

ultrasound could then be directed toward the anatomical regions where the lesion is located. Most regions of the brain can be accessed through the temporal acoustic window, with the exception of distal areas of the frontal and occipital lobes. Focussed ultrasounds are known to transiently increase the permeability of the BBB (3) and, therefore, allow passage of OA-GcMAF that is a relatively lipophilic molecule thanks to the presence of oleic acid. The procedure lasts 5-15 min, causes no discomfort or side effects and can be repeated continuously or in cycles. The procedure can be safely performed before, during or after other anti-neoplastic treatments.

- 1 Ruggiero M *et al*: Oleic Acid, deglycosylated vitamin D-binding protein, nitric oxide: a molecular triad made lethal to cancer. *Anticancer Res* 34(7): 3569-3578, 2014.
- 2 Bradstreet JJ *et al*: A new methodology of viewing extra-axial fluid and cortical abnormalities in children with autism *via* transcranial ultrasonography. *Front Hum Neurosci* 7: 934, 2014.
- 3 Burgess A *et al*: Drug delivery across the blood-brain barrier using focused ultrasound. *Expert Opin Drug Deliv* 1(5): 711-721, 2014.

85

GLYCOSYLATED OLEIC ACID/VITAMIN D-BINDING PROTEIN SUPPRESSES HER2 ONCOGENE EXPRESSION IN HUMAN BREAST CANCER

Marco Ruggiero^{1,3}, Jacopo J.V. Branca², David Noakes³, Massimo Gulisano², Gabriele Morucci², Lynda Thyer³ and Stefania Pacini²

Departments of ¹Experimental and Clinical Biomedical Sciences and ²Experimental and Clinical Medicine University of Firenze, Firenze, Italy;

³Immuno Biotech Ltd; Guernsey, Channel Islands, UK

A woman was diagnosed with mammary adenocarcinoma in the right breast in 1985 at the age of 37, followed by quadrantectomy, lymphadenectomy and irradiation. In 1999, an adenocarcinoma was diagnosed in the left breast, followed by ample resection and anti-oestrogen receptor treatment for 6 years. In April 2014, an infiltrating adenocarcinoma was diagnosed in the right breast that had been operated in 1985. Pre-operative biopsy showed weak positivity for progesterone receptor (PgR, <1%) and high positivity for the oncogene HER2 (>10%, score 2+). With the goal of boosting her immune system during the 3 weeks preceding surgery, glycosylated oleic acid/vitamin D-binding protein (OA-GcMAF) was administered by subcutaneous injections, nebulisation and with a fermented milk product rich in OA-GcMAF. No drug was administered in the 3 weeks preceding surgery, nor had the patient received any treatment for the previous 8 years. Following right mastectomy, analysis of the

surgical specimen showed no positivity for HER2 expression (negative, score 0) and significant increase in positivity of PgR, from <1% to 20%. These results indicate that OA-GcMAF treatment suppressed oncogene expression and induced differentiation of cancer cells. *Introduction*: The healthy properties of oleic acid (OA) in breast cancer have been known for centuries (1) and recent evidences suggest that these properties are amplified by association of OA with proteins such as α -lactalbumin and lactoferrins. These proteins form OA-protein complexes that exhibit highly selective anti-tumour activity *in vitro* and *in vivo* (2). We recently demonstrated that also a serum protein with the capability to bind OA shows anticancer effects; this is the glycosylated vitamin D-binding protein also known as Gc-protein-derived macrophage activating factor or GcMAF (3). This protein binds both OA and vitamin D and exerts its immune-stimulating and anticancer effects through cross-talk with the vitamin D receptor (4). Here we report a clinical observation suggesting that OA-GcMAF, that is GcMAF-complexed with OA, suppresses the expression of a major oncogene involved in human breast cancer that is the human epidermal growth factor receptor 2 (HER2). *Patients and Methods*: A woman was diagnosed with mammary adenocarcinoma in the right breast in 1985 at the age of 37, followed by quadrantectomy, lymphadenectomy and irradiation. In 1999, an adenocarcinoma was diagnosed in the left breast, followed by ample resection and anti-oestrogen receptor treatment for 6 years. In April 2014, an infiltrating adenocarcinoma was diagnosed in the right breast that had been operated in 1985. With the goal of boosting her immune system during the 3 weeks elapsing between biopsy and programmed surgery, OA-GcMAF (Goleic[®], Immuno Biotech Ltd.) was administered by subcutaneous injections (880 ng) and nebulisation (880 ng) as indicated in (3). The patient followed a nutritional regime based on a low carbohydrate, high protein diet (5). To this end, the patient was provided with food containing only 2% carbohydrates (Le Gamberi Foods, Forlì, Italy), and with essential aminoacids (Master Aminoacid Pattern[®], dr. reinwald healthcare gmbh, Schwarzenbruck, Germany) (6). The patient was also provided with a fermented milk product containing colostrum and microorganisms known to produce OA-GcMAF from the Gc-protein present in milk (Bravo Probiotic[®], Les Alpes, Wellington, NZ). No drug was administered or was programmed in the 3 weeks preceding surgery, nor had the patient received any treatment for the previous 8 years. The analyses on HER2 and other gene expression on the biopsy and surgical specimens were performed by the laboratory of the University Hospital of Careggi of the Italian Public Health Service, in Firenze, Italy. Analyses were performed according to the European standards of quality (UNI EN ISO 9001:2008) and were examined and countersigned by four different professionals. The original documents are conserved in the archives of the Department of Biomedicine of the Careggi

Hospital (Molecular Diagnostic and Pathologic Histology). The patient gave the informed consent to the treatment as well as to this description of her results. Surgery was performed at the Division of General Surgery n. 2 of the University Hospital of Careggi. *Results:* Amplification or overexpression of HER2 plays an important role in the development and progression of breast cancer and has become an important biomarker and target of therapy (7) since it is strongly associated with increased disease recurrence and a poor prognosis (8). Consistent with the aggressive nature of the cancer in this patient, pre-operative biopsy on four specimens collected under ultrasound guidance showed significant positivity for HER2 assessed by the polyclonal antibody A 0485 with >10% of positivity and a score of 2+ (Figure 1). After 3 weeks of OA-GcMAF treatment and subsequent mastectomy, analysis of the surgical specimen showed no positivity for HER2 expression (negative, score 0; Figure 1), thus indicating complete suppression of oncogene expression. Study of the expression of progesterone receptor (PgR, clone 1E2) was consistent with such a reversal of the neoplastic phenotype. PgR expression in the biopsy was low (<1%), a finding consistent with poor differentiation and aggressiveness. However, in the surgical specimen taken after the 3 weeks of treatment with OA-GcMAF, PgR expression was significantly increased to 20% (Figure). The selectivity of these effects was confirmed by a study of the expression of Ki67 and estrogen receptor (30% and 90%, respectively) that did not show any change following OA-GcMAF treatment (Figure). *Discussion:* These results demonstrate that OA-GcMAF, administered by subcutaneous injections, aerosol or in a functional food product, suppressed the expression of HER2, an oncogene which plays a key role in the aetiology, invasive progression and metastasis in breast cancer. This effect was paralleled by increase of PgR expression, thus indicating that OA-GcMAF treatment induced healthy differentiation of cancer cells. We hypothesize that these multifaceted effects on the regulation of gene expression in human breast cancer are due to the peculiar association of OA with GcMAF that is an association between two molecules endowed with anticancer properties. In fact, OA has been shown to down-regulate HER2 expression in cancer cell lines (9) and we demonstrated that GcMAF inhibits human breast cancer cell proliferation and reverts their malignant phenotype (10). We hypothesize that OA-GcMAF, but not OA or GcMAF taken singularly, interacts with the HER2 protein through hydrophobic interaction between the amino-terminal of GcMAF and the extracellular region of HER2, and between the OA-binding region of GcMAF and the plasma membrane (4). In fact, in the stretch of aminoacids between position 17-46 of GcMAF, and position 243-273 of HER2, there is a high density of hydrophobic aminoacids that may favour selective binding. Whatever the case, these results indicate that the effects of OA-GcMAF in cancer are due to a multiplicity of actions that involve suppression of oncogene expression.

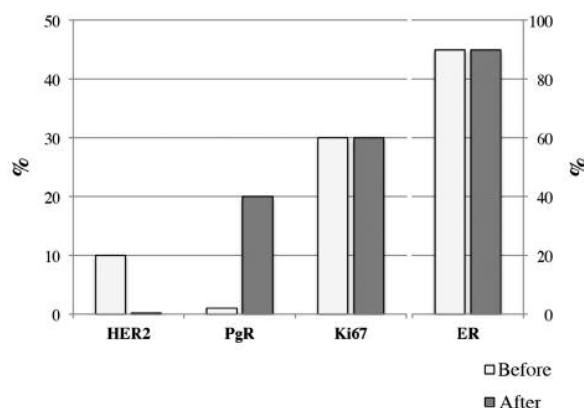


Figure. Level of expression of HER2, progesterone receptor (PgR), Ki67 protein and estrogen receptor (ER).

“Before”, indicates level of expression observed on the biopsy samples obtained 3 weeks before surgery and before any treatment. “After”, indicates level of expression observed on surgical specimens after OA-GcMAF treatment. Level of expression is expressed as percentages as in the original reports. The axis on the left (0-50%) refers to HER2, PgR and Ki67. The axis on the right (0-100%) refers only to ER. The actual levels were: HER2, before: >10%, score 2. HER2, after: negative, score 0. PgR, before: <1%. PgR, after: 20%. Ki67 before and after: 30%. ER, before and after: 90%.

- Colomer R *et al*: Giacomo Castelvetro's salads. Anti-HER2 oncogene nutraceuticals since the 17th century? *Clin Transl Oncol* 10(1): 30-34, 2008.
- Fang B *et al*: Bovine lactoferrin binds oleic acid to form an anti-tumor complex similar to HAMLET. *Biochim Biophys Acta* 1841(4): 535-543, 2014.
- Ward E *et al*: Clinical experience of cancer immunotherapy integrated with oleic acid complexed with de-glycosylated vitamin d binding protein. *Am J Immunol* 10(1): 23-32, 2014.
- Thyer L *et al*: A novel role for a major component of the vitamin D axis: vitamin D binding protein-derived macrophage activating factor induces human breast cancer cell apoptosis through stimulation of macrophages. *Nutrients* 5(7): 2577-2589, 2013.
- Ho VW *et al*: A low carbohydrate, high protein diet slows tumor growth and prevents cancer initiation. *Cancer Res* 71(13): 4484-4493, 2011.
- Lucà-Moretti M *et al*: Master Amino acid Pattern as substitute for dietary proteins during a weight-loss diet to achieve the body's nitrogen balance equilibrium with essentially no calories. *Adv Ther* 20(5): 282-291, 2003.
- Mitri Z *et al*: The HER2 Receptor in Breast Cancer: Pathophysiology, Clinical Use, and New Advances in

Therapy. *Chemother Res Pract* 2012: 743193, 2012.

8 Tan M *et al*: Molecular mechanisms of erbB2-mediated breast cancer chemoresistance. *Adv Exp Med Biol* 608: 119-129, 2007.

9 Carrillo C *et al*: Antitumor effect of oleic acid; mechanisms of action: a review. *Nutr Hosp* 27(6): 1860-1865, 2012.

10 Pacini S *et al*: Effects of vitamin D-binding protein-derived macrophage-activating factor on human breast cancer cells. *Anticancer Res* 32(1): 45-52, 2012.

86

CLINICAL EXPERIENCE OF IMMUNOTHERAPY BASED ON OLEIC ACID BOUND TO GLYCOSYLATED VITAMIN D-BINDING PROTEIN IN LOCALISED AND METASTATIC ADENOCARCINOMA OF THE PANCREAS

Lynda Thyer¹, Jacopo J.V. Branca², Margit Taubmann³

¹Macro Innovations Ltd, CB4 0DS Cambridge, UK;

²Department of Experimental and Clinical Medicine, University of Firenze, 50134 Firenze, Italy;

³Naturheilzentrum, D-95444 Bayreuth, Germany (jacopo.branca@libero.it)

Adenocarcinoma of the pancreas still carries a dramatically poor prognosis and the survival rate for this disease has not improved substantially in the past 40 years. Therefore, new treatment options are urgently needed and this need motivates oncologists to search for novel approaches such as immunotherapy. Here we report two clinical cases successfully treated with an integrative immunotherapeutic approach based on oleic acid bound to glycosylated vitamin D-binding protein (OA-GcMAF). Considering that immune suppression induced by pancreatic cancer is one of the main causes for resistance to chemotherapy and targeted therapy, this novel immunotherapeutic approach has the potential for revolutionising the field of pancreatic adenocarcinoma treatment. *Introduction*: Adenocarcinoma of the pancreas is, after colorectal cancer, the second most common digestive cancer in the USA where it represents the fourth leading cause of cancer-related death in both genders. In Europe, adenocarcinoma of the pancreas is the sixth most frequent cancer and is predicted to become the fourth cause of cancer death in both sexes in due course in the European Union (1, 2). Patients with pancreatic adenocarcinoma have an especially poor prognosis with a 5-year survival rate of <1% and a median survival of 4-6 months. Patients with a metastatic disease are usually treated with chemotherapy that is minimally effective (3). It has been demonstrated that pancreatic cancer-induced immune suppression is the main cause for this dramatically poor prognosis and, therefore, it has been proposed that immunotherapies may be particularly effective in this type of cancer (4). We recently demonstrated that

immunotherapy based on oleic acid (OA) bound to glycosylated vitamin D-binding protein (OA-GcMAF) is effective in a variety of cancers (5); here we describe two clinical cases demonstrating that OA-GcMAF has therapeutic efficacy also in pancreatic adenocarcinomas. *Patients and Methods*: Patients with adenocarcinoma of the pancreas were treated with OA-GcMAF-based integrative immunotherapy according to the "Good practice in prescribing and managing medicines and devices" effective February 2013. The approaches described below, aimed at strengthening the immune system and reducing tumour growth, are considered complementary to other anti-neoplastic therapeutic procedures. OA-GcMAF complexes (GOleic) were prepared in-house at Immuno Biotech Ltd as previously described (5). The protocol for pancreatic adenocarcinoma was the following: OA-GcMAF (880 ng/day) was administered by subcutaneous injections in proximity of the inguinal lymphnodes (440 ng in each side) under ultrasound guidance. OA-GcMAF (880 ng) was also administered daily by nebulisation (880 ng dissolved in 5 ml saline). Suppositories containing 200 ng OA-GcMAF were administered daily. The total amount of daily OA-GcMAF was 1960 ng, an amount consistent with the procedure described by Nonaka *et al*. (6). Patients were provided with supplementation of vitamin D3, 20.000 IU per day, and they were taught to drink at least 2 litres of water per day. Patients followed a nutritional regime based on a diet very low in carbohydrates, and high in proteins (7). This regimen included supplementation with essential aminoacids (Master Aminoacid Pattern, dr. reinwald healthcare gmbh, Schwarzenbruck, Germany). Considering that probiotics are efficient immunopotentiators and have a role in cancer prevention (8), patients were provided with a probiotic fermented milk product containing colostrum and microorganisms known to produce natural OA-GcMAF during the fermentation process (Bravo Probiotic, Les Alpes, Wellington, NZ). Finally, considering the role of low-dose acetylsalicylic acid in cancer prevention (9), patients were provided with 100 mg of such a principle per day. *Results*: *Clinical case #1*. A 58-year-old lady was diagnosed with pancreatic adenocarcinoma localised in the body of the pancreas. The lesion could be detected by ultrasonography and it appeared as a roundish mass of 0.924 ml of calculated volume (Figure 1A). After two weeks of treatment as described above, the calculated volume of the mass was reduced to 0.517 ml that is about 39% (Figure 1B). The patient did not report any side effect: her body weight and lean mass increased during the two weeks of treatment. *Clinical case #2*. A 73-year-old man was diagnosed with metastatic pancreatic adenocarcinoma. Previous CT scans had evidenced peritoneal metastases. The patient was overweight and presented with an insulin-dependent diabetes. Due to the morphological constitution of the patient, the primary pancreatic lesion could not be evidenced by ultrasonography. However, a hypo-echoic roundish mass in the abdomen,