

Cervicoisthmic choriocarcinoma mimicking cesarean section scar ectopic pregnancy

Flavia Sorbi, Giovanni Sisti, Annalisa Pieralli, Mariarosaria Di Tommaso, Lorenzo Livi¹, Anna Maria Buccoliero², Massimiliano Fambrini

Departments of Science for Woman and Child Health, ¹Radiation-Oncology, and ²Human Pathology and Oncology, University of Florence, Florence, Italy

Primary choriocarcinoma of the uterine cervix is an extremely rare disease. The clinical diagnosis of cervical choriocarcinoma is difficult, because of its rarity and being non-specific abnormal vaginal bleeding the most common symptom. In the present report, the authors present a case of cervical choriocarcinoma, which was initially misdiagnosed as a cesarean section scar ectopic pregnancy. Remission of cervical choriocarcinoma was accomplished with the combination of hysterectomy and chemotherapy.

Key words: Cesarean section scar, choriocarcinoma, ectopic pregnancy

How to cite this article: Sorbi F, Sisti G, Pieralli A, Di Tommaso M., Livi L, Buccoliero AM, Fambrini M. Cervicoisthmic choriocarcinoma mimicking cesarean section scar ectopic pregnancy. J Res Med Sci 2013;18:914-7.

INTRODUCTION

Primary gestational cervical choriocarcinoma is an extremely rare disease and belongs to heterogeneous family of the gestational trophoblastic disease (GTD). Gestational choriocarcinoma is associated with co-incident or antecedent pregnancy. These pregnancies may be normal term pregnancy, molar pregnancy or abortion.

There are nearly 90 extra-uterine choriocarcinoma cases in the literature and uterine cervix is the most common site.^[1]

The clinical diagnosis of cervical choriocarcinoma is difficult, because of its rarity and being non-specific abnormal vaginal bleeding the most common symptom.

In the present report, the authors present a case of cervical choriocarcinoma misdiagnosed as ectopic pregnancy.

CASE REPORT

In August 2012, a 30-year-old Chinese woman was admitted to Pescia Hospital for irregular vaginal bleeding of 10 days duration and suprapubic pain.

She was gravida 4 para 2. Her first and third pregnancy ended in full term delivery by cesarean

section (C-section) at 40 and 39 gestational week respectively. Her second and last pregnancy ended in the first trimester abortion in 2007 and 2010 respectively.

After 17 weeks of amenorrhea, serum beta human chorionic gonadotropin (β -hCG) was 40796 mUI/ml. Trans-vaginal ultrasound scan failed to identify an intrauterine pregnancy and showed the presence of an extremely vascularized cervical mass, localized in the isthmic region of the cervix, just over the scar of the previous C-section. The patient was considered to have an ectopic cesarean scar pregnancy and then was referred to our clinic, Careggi University Hospital as a third level hospital, for a better diagnostic and therapeutically assessment.

We repeated trans-vaginal ultrasound scan that confirmed the diagnosis [Figures 1 and 2]. Serum β -hCG level continued to grow reaching the value of 60,000 mUI/dl in 3 days. The patient had no any other symptoms than little vaginal bleeding.

Since, there is no standard protocol in the treatment of cesarean scar pregnancy, we discussed with the patient three treatment options: Expectant management, medical therapy or conservative surgical therapy. The decision fell on surgery and the patient underwent explorative laparotomy. The cervical lesion appeared as a large, friable highly vascularized mass that occupied

Address for correspondence: Dr. Sisti Giovanni, Viale Morgagni, 85; 50134; Florence, Departments of Science for Woman and Child Health Obstetrics and Gynecology division, Azienda Ospedaliero-Universitaria Careggi, Florence University, Italy. E-mail: giovanni83@email.it

Received: 16-01-2013; **Revised:** 13-02-2013; **Accepted:** 09-04-2013

the whole thickness of cervical wall. Intra-operative conversion to hysterectomy became necessary since the unfeasibility of conservative uterine surgery. The patient made an uneventful recovery. She was discharged on postoperative day 4, with serum β -hCG of 4885 mUI/ml.

Definitive pathologic evaluation of surgical specimen led to the diagnosis of: Primary gestational cervical choriocarcinoma with the presence of syncytiotrophoblastic and cytotrophoblastic cells [Figures 3 and 4]. Immunohistochemical staining was positive for β -hCG.

No metastases were detected by post-surgical whole-body computed tomography (CT).

The FIGO (Fédération Internationale de Gynécologie et d'Obstétrique) 2000 criteria showed a stage I choriocarcinoma (confined to the uterus) with a FIGO score of 8:^[2] Abortion before choriocarcinoma (1 point), delay between pregnancy and choriocarcinoma of over 12 months (4 points), and

β -hCG blood level of between 10,000 and 100,000 (2 points), largest tumor size of 3, 7 cm (1 point).

According to the FIGO classification, the patient began a combination chemotherapy using etoposide, methotrexate, actinomycin D, alternating with cyclophosphamide and oncovine (EMA-CO).

After the first cycle of chemotherapy, the serum β -hCG decreased to normal range (<5 mUI/dl). Eight weeks after the β -hCG level was still negative and treatment ended with the third cycle of EMA-CO.

One month later whole body CT scan revealed no abnormality.

DISCUSSION

In women, choriocarcinoma usually arises in the uterine cavity. Extra-uterine choriocarcinoma is an extremely rare condition, found mostly in the cervix.

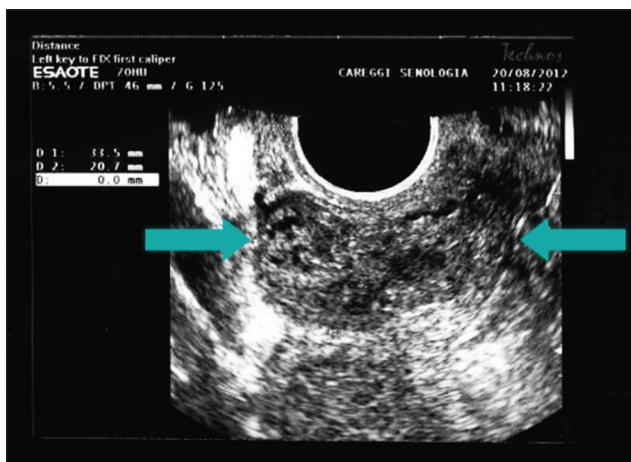


Figure 1: Ultrasound two-dimensional image of the cervix; the arrows outline the presence of the extra-uterine "mass"

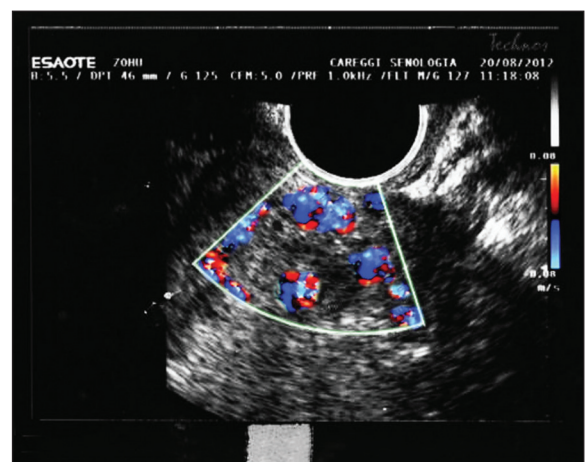


Figure 2: Ultrasound color Doppler applied to the cervix, showing a highly vascularized zone

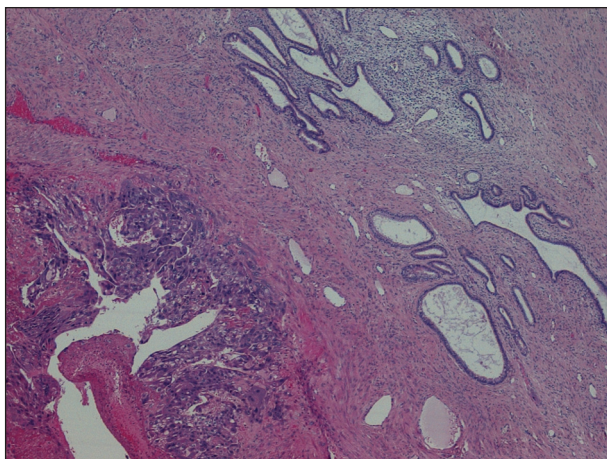


Figure 3: Tumor lesion in the lower left corner and cervical glandular crypt in the upper right corner of the figure (H and E, $\times 40$)

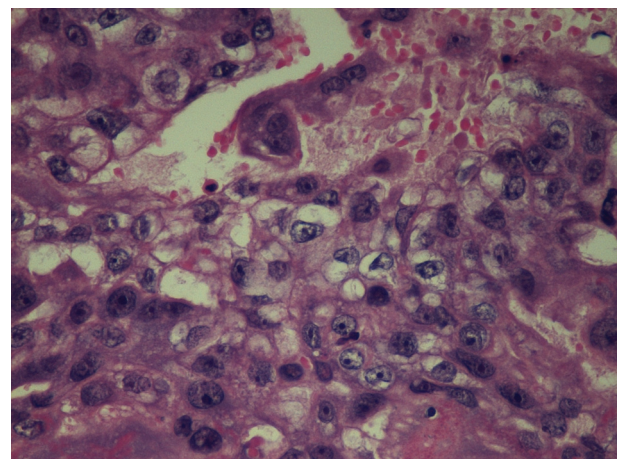


Figure 4: Choriocarcinoma. Atypical cytotrophoblasts and syncytiotrophoblasts with pronounced cytologic atypia (H and E, $\times 400$)

Diagnostic criteria of such an entity, described first by Saito^[3] are: (1) Absence of disease in the uterine cavity, (2) pathologic confirmation of disease, (3) exclusion of molar pregnancy or normal intrauterine pregnancy, and (4) intramural choriocarcinoma in the uterine corpus should not be considered as ectopic choriocarcinoma.

Although the tumor can develop with coincident pregnancy, late presentation of choriocarcinoma has been reported, including in postmenopausal patient.^[4]

The pathogenesis of cervical choriocarcinoma remains controversial.^[5,6] It has been suggested it may arise from a tumor in the uterine cavity that spontaneously regress after spreading to cervix.

There are authors that suggest it may develop from a coincident cervical pregnancy. In final, it may origins from transport of chorionic cells from a previous pregnancy that undergo malignant transformation after a quiescent period.

The diagnosis of primary extra-uterine choriocarcinoma is challenging because the clinical symptoms are often non-specific and can mimic others, more common, cervical lesions as cervical pregnancy, threatened abortion, cervical polyp or cervical neoplasia.

In the present case, choriocarcinoma was presented with 17 week of amenorrhea, vaginal bleeding, and low rate of serum β -hCG levels.

GTD produces excessive amounts of β -hCG, 3-100 times higher than normal pregnancy. Serial measurements of β -hCG level are the most useful method of diagnosis and follow-up after treatment.

In contrast, ectopic pregnancies are differentiated from normal intrauterine pregnancy by an abnormally slow rate of increase in or a decreasing β -hCG level. In our case, the absence of an embryo and the presence of low β -hCG level were in accordance with the diagnosis of ectopic pregnancy. On the other hand, the ethnic group and the history of abortion of our patient suggested a GTD.

Transvaginal color Doppler ultrasound is essential for early diagnosis of the disease since it allows the detection of hypervascularity with diastolic blood flow in tumoral vessels resulting from angiogenesis and neovascularization.^[5]

Unfortunately, in our case, the radiologist response was not exhaustive (“ectopic C-section scar pregnancy”), although the images didn’t show any embryo-shape

or any gestational sac well-defined. There was only a gestational tissue with high-density vascularization [Figures 1 and 2].

The imaging findings with the clinical signs and symptoms, and the rarity of choriocarcinoma misled us to the initial diagnosis of ectopic pregnancy. This resulted in delay in administrating appropriate chemotherapy with a subsequent hysterectomy, unnecessary in a young patient.

In the literature, the majority of the cases with choriocarcinoma were initially treated with hysterectomy due to incontrollable bleeding.^[2] Recently, selective arterial embolization was used to control bleeding from cervical choriocarcinoma allowing successfully conservative management by chemotherapy alone.^[7,8] The clinical presentation of our patient wasn’t a life-threatening vaginal bleeding and conservative management could have been proposed.

We believe focusing on epidemiologic risk factor of choriocarcinoma; diagnosis of choriocarcinoma could have been made early. Our patient was a Chinese woman with two previous abortions. In Italy the rate of choriocarcinoma is 0.013/1,000 pregnancies and 0.030/1,000 deliveries.^[9] In Asia, Africa and Latin America, the incidence rates are higher, about 1 in 500-1000 pregnancies. Twenty-five percent of choriocarcinoma growth occurs following an abortion.

In conclusion, although its rarity, choriocarcinoma should be considered in the differential diagnosis of a patient with the classic symptoms and imaging findings of ectopic pregnancy, particularly in Asiatic patient with history of recurrent abortion. A large increase in the incidence of choriocarcinoma is expected as a result of immigration from Asian in recent decades and we should then consider choriocarcinoma in the differential diagnosis of irregular vaginal bleeding, positive β -hCG level, and absence of an embryo at ultrasound.

REFERENCES

1. Herts BR, Yee JM, Porges RF. Primary cervical choriocarcinoma: Case report and review of the literature. *J Ultrasound Med* 1993;12:59-62.
2. FIGO Oncology Committee. FIGO staging for gestational trophoblastic neoplasia 2000. FIGO Oncology Committee. *Int J Gynaecol Obstet* 2002;77:285-7.
3. Saito N. On ectopic choriocarcinoma. *World Obstet Gynecol* 1965;17:459-84.
4. Baykal C, Tulunay G, Bülbül D, Boran N, Köse MF. Primary choriocarcinoma of the uterine cervix in a postmenopausal patient: A case report. *Gynecol Oncol* 2003;90:667-9.
5. Yahata T, Kodama S, Kase H, Sekizuka N, Kurabayashi T, Aoki Y, *et al.* Primary choriocarcinoma of the uterine cervix: Clinical,

- MRI, and color Doppler ultrasonographic study. *Gynecol Oncol* 1997;64:274-8.
6. Kairi-Vassilatou E, Papakonstantinou K, Grapsa D, Kondi-Paphiti A, Hasiakos D. Primary gestational choriocarcinoma of the uterine cervix. Report of a case and review of the literature. *Int J Gynecol Cancer* 2007;17:921-5.
 7. Frati A, Ducarme G, Wernet A, Chuttur A, Vilgrain V, Luton D. Uterine artery embolization as treatment for life-threatening haemorrhage from a cervical choriocarcinoma: A case report. *Eur J Obstet Gynecol Reprod Biol* 2008;141:87-8.
 8. Chandacham A, Kietpeerakool C, Khunamornpong S, Suprasert P, Srisomboon J, Charoenkwan K, *et al.* Successfully conservative treatment of large cervical choriocarcinoma with profuse vaginal bleeding. *J Med Assoc Thai* 2009;92:120-3.
 9. Salerno A. The incidence of gestational trophoblastic disease in Italy: A multicenter survey. *J Reprod Med* 2012;57:204-6.

Source of Support: Nil, **Conflict of Interest:** None declared.