

Surgical Correction of Left Coronary Artery Origin From the Right Coronary Artery

Michele Coceani, MD, Marco Ciardetti, MD, Emilio Pasanisi, MD, Mathis Schlueter, MD, Cataldo Palmieri, MD, Danilo Neglia, MD, Roberto Sciagrà, MD, Mattia Glauber, MD, and Daniele Rovai, MD, FESC

Invasive Cardiology Unit and Clinical Cardiology Unit, Fondazione Toscana G. Monasterio, Pisa; Invasive Cardiology Unit and Cardiac Surgery Unit, Fondazione Toscana G. Monasterio, Massa; Nuclear Medicine Unit, University of Florence, Careggi Hospital, Florence; and CNR Institute of Clinical Physiology, Pisa, Italy

We describe the case of a patient with limiting angina pectoris and anomalous origin of the left coronary artery from the right coronary artery, with a retroaortic course. Myocardial ischemia in the left anterior descending territory was documented by positron emission tomography, confirmed by fractional flow reserve, and relieved by surgical coronary reimplantation. This patient did not have coronary atherosclerosis or any other significant anatomic abnormality, such as myocardial bridging or compression between the aorta and the pulmonary artery. We attempt to describe the mechanisms of myocardial ischemia that contributed to the clinical manifestations in our patient.

(Ann Thorac Surg 2013;95:e1–2)

© 2013 by The Society of Thoracic Surgeons

Anomalous origin of a coronary artery (ACAO) from the opposite coronary sinus or the opposite coronary artery has a prevalence that ranges from 0.15% to 0.39% in invasive angiographic studies [1]. Although the majority of these individuals are symptom free, angina, syncope, and sudden cardiac death may occur, even in the absence of coronary atherosclerosis [1]. A mechanism underlying these clinical manifestations is extrinsic coronary compression, wherein the ACAO has an interarterial (between the aorta and pulmonary artery), intramural (in the aortic wall), or intraseptal (in the interventricular septum) course or when a muscular bridge is also present [1]. In the absence of these conditions, the mechanisms that link symptoms and sudden death with ACAO are unclear, and the indications for surgical correction remain controversial. Thus, the key clinical challenge lies in the identification of patients at risk of sudden death and, therefore, who should undergo operation. We present the case of a patient with anomalous origin of the left coronary artery from the right coronary artery (RCA) in whom symptoms were caused by myocardial ischemia and with perfusion defects that were no longer present after surgical correction.

A 39-year-old man was admitted to our institute because of a long-lasting history of exertional chest pain, resistant to medical therapy. He had a high-risk cardiovascular profile characterized by a positive family history for

sion, hypercholesterolemia, and psychosocial stress. The patient underwent exercise echocardiography, during which ST segment depression in the inferolateral leads associated with chest pain was observed—in the absence, however, of any wall motion abnormalities. Because of the recurrent symptoms, we performed ^{13}N -ammonia positron emission tomography during pharmacologic stress with dipyridamole (0.56 mg/kg over 4 minutes), which showed a relative and absolute reduction of myocardial blood flow in the apex of the left ventricle (Fig 1). The patient was referred for coronary angiography, which unveiled an anomalous origin of the left main coronary artery (LMCA) from the proximal portion of the RCA, with a course apparently posterior to the aorta (Fig 1); the LMCA then bifurcated regularly into the left anterior descending and circumflex arteries. Signs of atherosclerosis were absent in both the right and the left coronary systems. To give us a better understanding of the pathophysiology of the patient's symptoms, a pressure wire was advanced in the distal left anterior descending coronary artery and, during intravenous infusion of adenosine (140 $\mu\text{g}/\text{kg}/\text{min}$), abnormal fractional flow reserve (FFR) was registered (0.82). Measurements were repeated with the wire inserted in the distal RCA, and the FFR was normal (0.97). After coronary angiography, the patient underwent computed tomography coronary angiography, which confirmed the retroaortic course of the LMCA and disclosed a normal origin of the RCA and a regular ostium of the LMCA (Fig 1). Of note, the LMCA had a right-angle takeoff from the RCA. On the basis of the patient's clinical history and in consideration of the results of invasive and noninvasive testing, surgical correction of the coronary artery anomaly was performed. During the procedure, the LMCA was ligated, sectioned, and directly reimplanted on the non-coronary sinus of Valsalva with a "button technique." The patient's postoperative course was uneventful, and he has been asymptomatic for angina ever since. Repeated positron emission tomography was performed 3 months after the operation and, during pharmacologic stress with dipyridamole, the measured myocardial blood flow in the left ventricular apex was normal (Fig 1).

Comment

In our patient, the clinical scenario was dominated by limiting angina pectoris associated with objective evidence of myocardial ischemia that could be explained neither by extrinsic compression nor by coexisting coronary atherosclerosis. Previously, Lim and colleagues [2] had studied, through the use of FFR, a patient with an anomalous LMCA originating from the right sinus of Valsalva and with an interarterial course. These authors had recorded an FFR value of 0.87 in the LMCA, and their patient was scheduled for operation; interestingly, during the procedure a slitlike orifice of the LMCA was found, and this was attributed as the primary cause of myocardial ischemia, also because coronary atherosclerosis was absent. However, in our patient no abnormality in the origin of the LMCA from the RCA was observed at computed tomography or during surgical inspection. We therefore hypothesize that the reduced FFR registered in the left anterior descending coronary artery was second-

Accepted for publication July 11, 2012.

Address correspondence to Dr Coceani, Via Moruzzi 1, 56124 Pisa, Italy; e-mail: michecoc@ftgm.it.

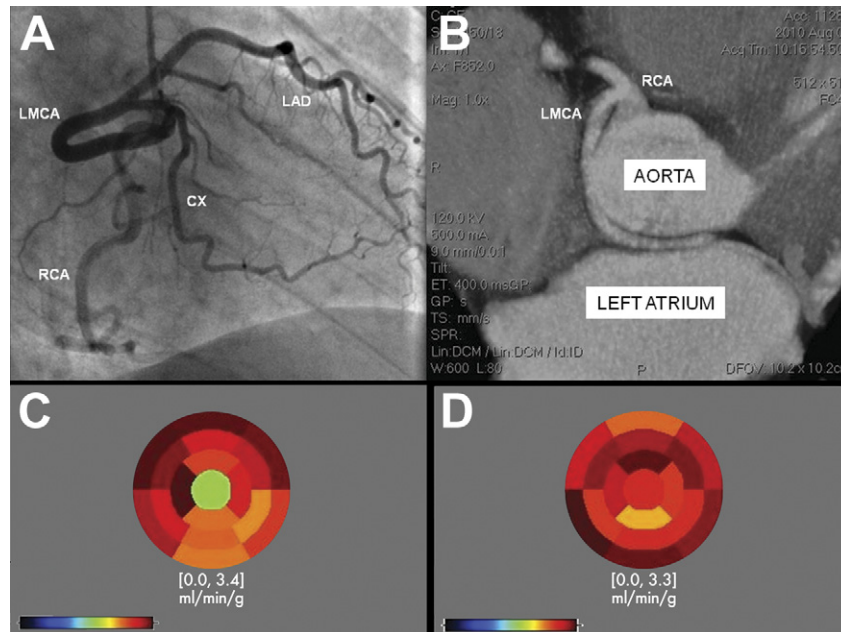


Fig 1. Coronary angiography, computed tomography coronary angiography and positron emission tomography images. (A) Coronary angiogram showing a right anterior oblique projection. The course of the LMCA appeared to be retroaortic, and this was subsequently confirmed by (B) computed tomography coronary angiography: maximum intensity projection image with increased slab thickness. Computed tomography also disclosed several other interesting elements: normal origin of the RCA from the right sinus of Valsalva, LMCA with a regular ostium and tight-angle takeoff from the proximal RCA, absence of coronary atherosclerosis. (C) Positron emission tomography scan before surgical correction, showing dipyridamole myocardial blood flow to be reduced in the apical segment of the left ventricle (1.86 mL/min/g compared with a mean value of 2.92 mL/min/g [range, 2.47 to 3.35 mL/min/g] in the remaining segments). (D) Return to normal after surgical correction (2.75 mL/min/g compared with a mean value of 2.89 mL/min/g [range, 2.33 to 3.26 mL/min/g] in the remaining segments). (CX = circumflex artery; LAD = left anterior descending artery; LMCA = left main coronary artery; RCA = right coronary artery.)

ary to other mechanisms such as the right-angle takeoff of the LMCA from the RCA, which may have resulted in reduced perfusion pressure during coronary hyperemia, an abnormally long LMCA (with length being an important determinant of vascular resistance), and aortic dilatation secondary to aging and exertion with possible compression of the LMCA.

Still today, the indications for surgical correction of ACAO remain controversial. Surgical correction is generally recommended for all patients with an anomalous LMCA originating from the right sinus of Valsalva and with an interarterial course, whereas when the RCA originates from the opposite coronary cusp, only patients with symptoms or a positive stress test result should undergo operation [1, 3]. However, the optimal therapy in patients (especially if asymptomatic) with LMCA originating from the right sinus of Valsalva, but with a retroaortic or prepulmonary course, has not yet been established [1, 3]. According to some, age is an important factor that should be weighed in during the decision process, with a conservative approach reserved for older

(more than 30 years of age) patients, especially in the absence of documented myocardial ischemia [1, 3]. To the best of our knowledge, this is the first reported case of inducible myocardial ischemia documented by noninvasive imaging, confirmed by FFR, and relieved by surgical reimplantation in the absence of coronary atherosclerosis or other significant anatomic abnormalities in a patient with ACAO and a retroaortic course.

References

1. Lim JC, Beale A, Ramcharitar S. Anomalous origination of a coronary artery from the opposite sinus. *Nat Rev Cardiol* 2011;8:706-19.
2. Lim MJ, Forsberg MJ, Lee R, Kern MJ. Hemodynamic abnormalities across an anomalous left main coronary artery assessment: evidence for a dynamic ostial obstruction. *Catheter Cardiovasc Interv* 2004;63:294-8.
3. Krasuski RA, Magyar D, Hart S, et al. Long-term outcome and impact of surgery on adults with coronary arteries originating from the opposite coronary cusp. *Circulation* 2011;123:154-62.