



NILDE

Network Inter-Library Document Exchange

Il presente documento viene fornito attraverso il servizio NILDE dalla Biblioteca fornitrice, nel rispetto della vigente normativa sul Diritto d'Autore (Legge n.633 del 22/4/1941 e successive modifiche e integrazioni) e delle clausole contrattuali in essere con il titolare dei diritti di proprietà intellettuale.

La Biblioteca fornitrice garantisce di aver effettuato copia del presente documento assolvendo direttamente ogni e qualsiasi onere correlato alla realizzazione di detta copia.

La Biblioteca richiedente garantisce che il documento richiesto è destinato ad un suo utente, che ne farà uso esclusivamente personale per scopi di studio o di ricerca, ed è tenuta ad informare adeguatamente i propri utenti circa i limiti di utilizzazione dei documenti forniti mediante il servizio NILDE.

La Biblioteca richiedente è tenuta al rispetto della vigente normativa sul Diritto d'Autore e in particolare, ma non solo, a consegnare al richiedente un'unica copia cartacea del presente documento, distruggendo ogni eventuale copia digitale ricevuta.

Biblioteca richiedente: Università degli studi di Firenze Biblioteca Biomedica

Data richiesta: 25/09/2013 10:30:00

Biblioteca fornitrice: Biblioteca Biomedica Centrale Università di Bologna

Data evasione: 25/09/2013 11:09:36

Titolo rivista/libro: Indian journal of orthopaedics

Titolo articolo/sezione: Long term results of percutaneous fixation of proximal humerus fractures.

Autore/i: Muncibì Francesco

ISSN: 0019-5413

DOI:

Anno: 2012

Volume:

Fascicolo:

Editore:

Pag. iniziale: 664

Pag. finale: 667

Long term results of percutaneous fixation of proximal humerus fractures

Francesco Muncibì, Diana Chicon Paez, Fabrizio Matassi, Christian Carulli, Lorenzo Nistri, Massimo Innocenti

ABSTRACT

Background: Proximal humerus fracture in elderly osteoporotic patients usually leads to severe displaced and multifragmentary fractures. Associated comorbidities may limit surgical options and conservative treatment is commonly indicated, however, with variable results. In most cases, surgery is the treatment of choice in order to restore anatomical integrity, and allow early functional recovery. Several techniques were used over the years, each with specific indication. Percutaneous pinning after closed reduction, a mini-invasive technique and fixation by use of K-wires is not preferred commonly. We present our experience with this approach, focusing on its indications and advantages.

Patients and Methods: A study group of 41 consecutive patients with a mean age of 65.5 years were evaluated clinically (VAS, Constant-Murley score, range of motion), and with radiological analysis: 35 patients finally completed a minimum followup of 24 months.

Results: K-wires were removed after a mean interval of 4 weeks. Clinical and radiographic healing occurred in a mean time of 8.2 weeks in all fractures but one, with improvements in mean Constant-Murley score of 87.6 points, mean VAS of 2.3. In 33 patients, the reduction was considered satisfactory. In two cases, reduction was poor, but the patients however presented acceptable functional outcome.

Conclusions: Percutaneous pinning may represent a suitable option of treatment for 2-or 3-part proximal humerus fractures in selected subjects.

Key words: Percutaneous fixation, proximal humerus fractures, percutaneous pinning

INTRODUCTION

Proximal humerus fractures are on rise due to sports and road accidents and increase in incidence of osteoporosis. Incidence is about 4-5% of all fractures, recent reports showed that over 70% of all proximal humeral fractures occur in patients over 60 years.¹ Several therapeutic approaches have been proposed depending on fracture pattern, patient's age, general health status, and level of activity: conservative treatment,² open reduction and internal fixation (ORIF),³ joint replacement,^{4,5} and percutaneous fixation.^{6,7} Good clinical outcomes range from 92% for ORIF³,

87% for conservative treatment², and 87.5% for shoulder arthroplasty.^{4,5} Advantages of ORIF are anatomic restoration, and early mobilization; however, open surgery may be associated with higher rates of infections, avascular necrosis of the humeral head and neurovascular lesions.³ Conservative treatment has limited indications, late functional recovery, but it is noninvasive, and may be efficient in undisplaced or mildly displaced fractures. Joint replacement has also very limited indications, strict selection of patients, and significant invasivity, but faster active recovery.^{4,5} Few reports showed results of percutaneous fixation and its actual indications.^{1,8,9} This technique is considered less invasive, with theoretic extensive indications, but it may not ensure anatomical reduction and early mobilization. Complications reported are pin migration and pintract infection.^{1,10,11}

Aim of this study was to report a prospective series of proximal humeral fracture to evaluate the efficacy of percutaneous fixation for proximal humerus fractures at a single Institution.

MATERIALS AND METHODS

We prospectively followed a series of 41 consecutive patients with proximal humeral fracture treated at our Institution

Orthopaedic Clinic, University of Florence (Chief: Prof. M. Innocenti), Largo P. Palagi, 1 – 50139 Florence, Italy

Address for correspondence: Dr. Christian Carulli, Orthopaedic Clinic, University of Florence, Largo P. Palagi, 1 – 50139, Florence, Italy
E-mail: christian.carulli@unifi.it

Access this article online	
Quick Response Code: 	Website: www.ijoonline.com
	DOI: 10.4103/0019-5413.104203

between March 2002 and October 2009 with closed reduction and percutaneous fixation with drilled Kirschner (K)-wires. Inclusion criteria were adult patients with 2-, 3-, or 4-part fractures. Exclusion criteria were subjects with fracture dislocations of proximal humerus, pathological fractures, patients affected by mental impairment, or not able to give informed consent.

Mechanism of injury included accidental falls ($n=37$), motorcycle accidents ($n=2$) and sports-related injuries ($n=2$). In 7 cases, other lesions were associated (legs fractures – 2 cases; chest fractures – 2 cases; ipsilateral wrist fractures – 3 cases). All patients underwent X-rays and CT scan at the Emergency Room. According to Neer's classification of,^{12,13} patients presented a displaced fracture type 2 ($n=8$), type 3 ($n=31$), and type 4 ($n=2$). Thirty patients were female and 11 male. Mean age was 65.5 years (range 34-88 years). Right arm was involved in 21 cases.

Surgery was performed by a single surgeon (FM) under scalene block ($n=34$), or general anaesthesia ($n=7$), under image intensifier assistance, and with patients in beach-chair position. Anatomic reduction was achieved by manual traction and gentle arm mobilization, and fixation was performed generally by three to four threaded 2.5-mm K-wires, depending on the number of fragments (according to Jaber's technique),^{4,6} and using a further wire only as joystick in cases of difficult reduction. Immobilization was generally achieved by a standard brace. Patients were encouraged to start active mobilization of elbow and wrist on the first postoperative day and Codman pendulum exercises on the second day. They were suggested to self-remove their braces several times during the day to allow passive mobilization of the shoulder, K-wires cleaning (with a 3-day interval). Braces were permanently removed after diagnosis of radiological healing and hardware removal: other exercises, as assisted or active elevation and internal/external rotation were thus allowed at that time. Range of motion (ROM) was limited to pain-free range. Followup visits were then conducted at 2, 3, 6, 12, and 24 months after surgery. Clinical examination included ROM and strength evaluation, pain assessment according to a visual analogic scale (VAS), and Constant-Murley score.¹⁴ Patients were considered clinically healed when able to perform a painless ROM closer as possible to pretraumatic conditions, particularly on forward elevation. Radiographic healing was demonstrated when all fragments showed substantial cortical continuity (defined as radiological proximity less than 1 mm between cortices in two projections). Complications were recorded during followup period.

RESULTS

Mean operation time was 35.6 minutes (range: 23-54

minutes). Fixation was achieved generally with K-wires left out of the skin, and bent at the extremity in order to control accidental migration.^{7,15} Postoperatively, a brace was positioned in 38 patients; the remainders, affected by ipsilateral wrist fractures, were treated with a cast and Desault bandage. No intraoperative and postoperative complications were recorded, as neurovascular lesions, migration of K-wires, infection, and avascular necrosis of proximal humerus. On the third postoperative day, all patients but 4 (with associated leg fractures) were discharged. Casts in patients with wrist fracture were removed after 5 weeks. K-wires were removed after 29.3 days (range 27-35 days) from surgery during first followup visit and after X-rays; assisted active ROM protocol of the shoulder was then suggested to all patients. Muscular strengthening exercises were delayed until full clinical and radiographic healing was established, with a mean interval of 87.8 days (range 81-94-days).

Thirty-five patients finally completed the followup; six patients were lost between 2 and 5 years after surgery (3 patients died for unrelated causes, 3 were unavailable).

All fractures but one completely healed in a mean time of 8.2 weeks (range 7-9 weeks) [Figure 1]. Two-and three-part fractures demonstrated faster clinical and radiographic healing with respect to the four-part fractures. Eleven patients presented severe comorbidities (type 2 fracture $n=1$, type 3 $n=7$, and type 4 $n=2$). A single case showed radiographic signs of atrophic nonunion [Figure 2]: the patient, a 34 year old female active subject, presented up to the 3 month followup, when substantial healing was noted. Subsequently, she never presented to other visits, because of full functional recovery in her daily activities. During a visit 8 years later asked by the patient for a subacromial impingement on the other shoulder, X-rays were performed bilaterally and surprisingly we found a nonunion in the previously fractured humerus treated with percutaneous fixation. However, she was still asymptomatic, even if a reduced muscular strength was referred during last years.

Mean Constant score normalized for age and gender was 87.6 points (range: 63-100) at final followup. Values varied on fracture type, resulting worst in 4-part fractures. Mean VAS score was 2.3 (range: 0-10); at final followup, 21 patients reported no pain, 8 mild pain and 6 significant, even tolerable pain.

Twenty two patients achieved a ROM very close to pretraumatic pattern, with more than 150° (range: 155°- 180°) in forward elevation and abduction, and more than 30° (range: 30°-35°) in both external and internal rotation. Seven subjects reported satisfactory ROM, with

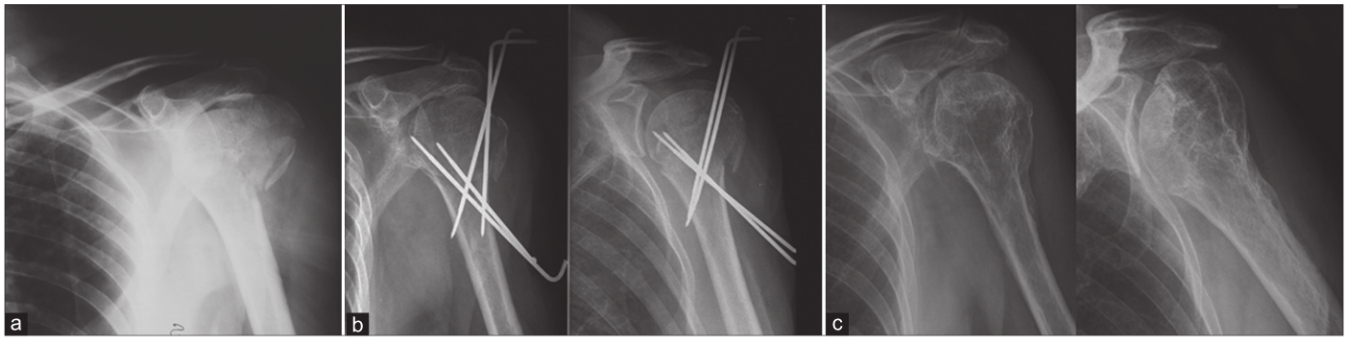


Figure 1: X-ray (anteroposterior view) left proximal humerus in a 61-year-old man showing (a) 3 part proximal humerus fracture; (b) postoperative X-rays with well aligned fragments and k-wires *in situ*; (c) X-rays at 5 years followup with well healed and remodeled proximal humerus

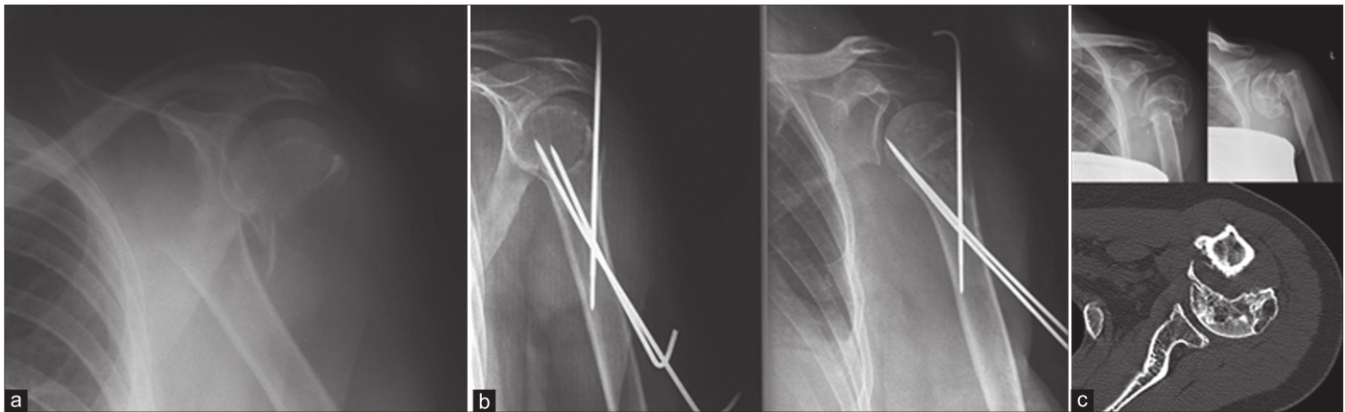


Figure 2: X-ray (anteroposterior view) left proximal humerus in a 36-year-old woman showing (a) 2-part proximal humerus fracture; (b) postoperative X-rays with adequate reduction of the fragments and k-wires *in situ*; (c) X-rays and CT scan at 8 years followup with loss of reduction and atrophic nonunion patient was asymptomatic

forward elevation and abduction over 120° (range: 120° - 140°), and over 25° (range: 25° - 30°) in external and internal rotation. The remainders acceptable ROM with elevation and abduction over 90° (range: 90° - 110°), and over than 20° (range: 20° - 25°) in external and internal rotation. Two 3-part fractures in 2 patients were judged as unsatisfactory from a radiographic point of view at one year followup check, even clinically their arms were well functioning, and constant scores more than 82 points. They presented a gap of the greater tuberosity more than 1 cm on the transverse plane, and varus malposition of 15° on the coronal plane.

DISCUSSION

Proximal humerus is second most common site of fracture in the upper limb after distal radius. Fractures are mainly related to low-energy trauma in elderly subjects affected by osteoporosis: bone fragility often complicates the pattern of fracture, and treatment is more challenging because of the higher rate of comorbidities affecting these patients. Younger patients are less frequently involved, usually after sport or road accidents.

Treatment of proximal humeral fractures still remains a

matter of controversy. Zyto and colleagues reported mean Constant scores of 65 points and no complications with conservative treatment with respect to surgical approach, resulting in a mean value of 60 points and complications (avascular necrosis, infection).² Magovern, Kenner, and Nho reported good Constant scores with surgery and relatively few complications, with better functional scores for percutaneous fixation.^{1,15,16} Ring *et al.* on the other hand reported excellent clinical results with low rate of complications in elderly patients treated by conservative treatment respect to ORIF, pinning, and joint replacement: particularly, pinning has been described as technically demanding, as ORIF by plates and screws characterized by high rates of complications.³ However, surgery has been proven for complex and complicated pattern of fractures in young and high-demand patients.^{8,9,15}

Percutaneous fixation has been reported in few papers as viable option, due to important limitations as long time of recovery, high rate of pins infection, poor reduction of fragments particularly in bone fragility.^{1,16} However, the advantage of this technique is its minimal invasivity, less blood loss, less exposure and soft tissues stripping and usefulness in older patients.^{16,17} Use of smooth K-wires

predisposes to pin loosening and loss of reduction: drilled K-wires with threaded tips allow reduction of this complication. Other advantage of percutaneous fixation is that in case of early loss of reduction ORIF may be performed.

In this series, no complication occurred; healing was achieved in all fractures but one clinical, with good pain relief and functional recovery. No loss of reduction was recorded at followup visits, even if in 2 cases, we had a significant gap between great tuberosity and head fragment, without clinical impairment or referred symptoms. The limitations of study are that it is an observational work with no blind observers analyzing the results. Study population is heterogeneous for age and level of activity; however, this represents one of the largest study group to date reported in literature with a long followup period. Fixation of percutaneous K-wire may represent an efficient treatment option for 2-or 3-part proximal humerus fractures.

REFERENCES

1. Magovern B, Ramsey ML. Percutaneous fixation of proximal humerus fractures. *Orthop Clin North Am* 2008;39:405-16.
2. Zyto K, Ahrengart L, Sperbert A, Törnkvist H. Treatment of displaced proximal humeral fractures in elderly patients. *J Bone Joint Surg Br* 1997;79B:412-7.
3. Ring D. Current concepts in plate and screw fixation of osteoporotic proximal humerus fractures. *Injury* 2007;38:559-68.
4. Reitman RD, Kerzhner E. Reverse shoulder arthroplasty as treatment for comminuted proximal humeral fractures in elderly patients. *Am J Orthop* 2011;40:458-61.
5. Esen E, Dogramci Y, Gultekin S, Deveci MA, Suluova Fanatli U, Bolukbasi S. Factors affecting results of patients with humeral proximal end fractures undergoing primary hemiarthroplasty: A retrospective study in 42 patients. *Injury* 2009;40:1336-41.
6. Jaberg H, Warner JJ, Jakob RP. Percutaneous stabilization of unstable fractures of the humerus. *J Bone Joint Surg Am* 1992;74A:508-15.
7. Resch H, Povacz P, Frölich R, Wambacher M. Percutaneous fixation of three-and four-part fractures of the proximal humerus. *J Bone Joint Surg Br* 1997;79B:295-300.
8. Karataglis D, Stavridis SI, Petsatodis G, Papadopolous P, Christodoulou A. New trends in fixation of proximal humeral fractures: A review. *Injury* 2011;42:330-8.
9. Drosdowech DS, Faber KJ, Athwal GS. Open reduction and internal fixation of proximal humerus fractures. *Orthop Clin North Am* 2008;39:429-39.
10. Freund E, Nachman R, Gips H, Hiss J. Migration of a Kirschner wire used in the fixation of a subcapital humeral fracture, causing cardiac tamponade: Case report and review of literature. *Am J Forensic Med Pathol* 2007;28:155-6.
11. Mellado JM, Calmet J, Garcia Forcada IL, Sauri A, Giné J. Early intrathoracic migration of Kirschner wires used for percutaneous osteosynthesis of a two-part humeral neck fracture: A case report. *Emerg Radiol* 2004;11:49-52.
12. Neer CR II. Displaced proximal humeral fracture. Part I. Classification and evaluation. *J Bone Joint Surg Am* 1970;52A:1077-89.
13. Neer CR II. Displaced proximal humeral fracture. Part II. Treatment of three-part and four-part displacement. *J Bone Joint Surg Am* 1970;52A:1090-103.
14. Constant CR, Murley AH. A clinical method of functional assessment of the shoulder. *Clin Orthop Relat Res* 1987;214:160-4.
15. Nho SJ, Brophy RH, Baker JU, Cornell CN, MacGillivray JD. Management of proximal humerus fractures based on current literature. *J Bone Joint Surg Am* 2007;89A:44-58.
16. Keener JD, Parsons BO, Flatow EL, Rogers K, Williams GR, Galatz LM. Outcomes after percutaneous reduction and fixation of proximal humerus fractures. *J Shoulder Elbow Surg* 2007;16:330-8.
17. Bogner R, Hubner C, Matis N, Auffarth A, Lederer S, Resch H. Minimally-invasive treatment of three-and four-part fractures of the proximal humerus in elderly patients. *J Bone Joint Surg Br* 2008;90B:1602-7.

How to cite this article: Muncibi F, Paez DC, Matassi F, Carulli C, Nistri L, Innocenti M. Long term results of percutaneous fixation of proximal humerus fractures. *Indian J Orthop* 2012;46:664-7.

Source of Support: Nil, **Conflict of Interest:** None.

Reproduced with permission of the copyright owner. Further reproduction prohibited without permission.