

Chapter 22

Doppler ultrasound of the aorta, inferior vena cava and visceral arteries

Boris Brkljačić¹, Sergio Castellani², Colin Deane³, Christoph F. Dietrich⁴

¹Boris Brkljačić, MD, Professor of Radiology, Department of Diagnostic and Interventional Radiology, University Hospital “Dubrava”, Medical School, University of Zagreb, Zagreb, Croatia.

²Sergio Castellani, Department of Medical and Surgical Critical Care A.O.U. - Careggi, associate professor in cardiovascular diseases, chair of angiology, University of Florence, Florence, Italy.

³Colin Deane, PhD, Vascular Laboratory, Department of Medical Engineering and Physics, King’s College, London, UK

⁴Christoph F. Dietrich, MD, PhD, Professor, Med. Klinik 2, Caritas-Krankenhaus Bad Mergentheim, Bad Mergentheim, Germany.

Content

Doppler ultrasound of the aorta.....	661
Doppler ultrasound of the inferior vena cava	667
References	668
Doppler ultrasound of visceral arteries	669
Doppler in diagnosis of mesenteric ischaemia	670
Aneurysms and pseudoaneurysms of visceral arteries	674
Doppler in inflammatory bowel disease.....	675
References	679

Doppler ultrasound of the aorta

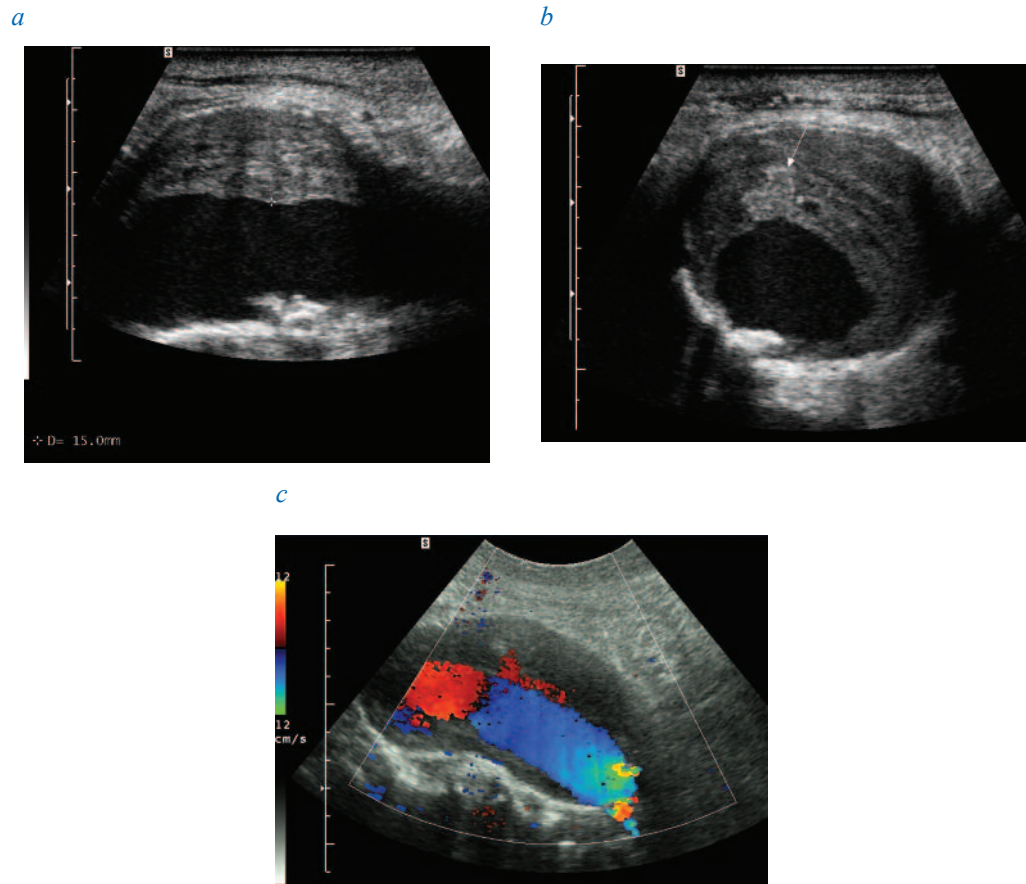
CT angiography (CTA) and MR angiography (MRA) are relatively new and commonly used imaging methods to evaluate diseases of the aorta. CTA is particularly useful to evaluate the abdominal aorta in acute aortic syndrome (AAS). In practice, the diagnosis of intramural haematoma can be reliably made using CT, and other manifestations of AAS can be reliably and relatively quickly evaluated with multidetector-row CT and CTA. To perform both CTA and MRA, intravenous injection of iodinated or gadolinium-based contrast media is required.

Ultrasound may also be useful, especially to detect the presence of an abdominal aortic aneurysm (AAA) and to follow-up its course. Ultrasound is also useful to follow-up patients after surgery or endovascular aortic repair (EVAR) for AAA. For the evaluation of the abdominal aorta and inferior vena cava (IVC) convex low-frequency transducers are used with a frequency range of 2.5–5 MHz, depending on the patient's body volume. Ultrasound is useful to demonstrate atherosclerotic changes of the aortic wall and to measure aortic diameter. Iliac arteries can be visualised well, as well as the coeliac trunk and its branches and mesenteric arteries. These vessels are usually examined with the patient in a supine position [1].

Aneurysm of the abdominal aorta and iliac artery are significant and potentially fatal conditions, which may remain clinically asymptomatic for years [2–4]. Acute aortic syndrome consists of aortic dissection, penetrating aortic ulcer and intramural haematoma. Ultrasound can demonstrate aneurysms that may be entirely asymptomatic, it can be used to follow-up enlargement of an aneurysm and to assess complications after surgery or endovascular treatment. If a patient is referred for ultrasound for AAA, one should measure the diameter and length of the aneurysm, evaluate the extension of the AAA to iliac arteries and try to determine the relation of the AAA to the renal arteries. The diameter of the normal aorta in adults is 2–2.5 cm, and a diameter above 3cm is diagnostic of AAA. However, an aneurysm can be present even if the diameter is below 3cm, if there is a focal dilatation of aorta. Normal iliac arteries have regular walls, with a maximum diameter of the common iliac artery of 1.5cm [2].

AAAs of atherosclerotic origin are most commonly saccular or fusiform in shape, their origin is infrarenal and they usually terminate at the aortic bifurcation, but may extend into the iliac arteries. These are true aneurysms, containing all layers of the aortic wall. It is recommended to briefly examine the aorta by ultrasound to rule out AAA in all patients who are referred to ultrasound for examination of peripheral arteries, because AAA is often asymptomatic. AAA usually enlarges 2 mm per year, and the dynamics of enlargement can be determined by ultrasound examinations [1,2,5,6]. AAA is shown in Figure 1.

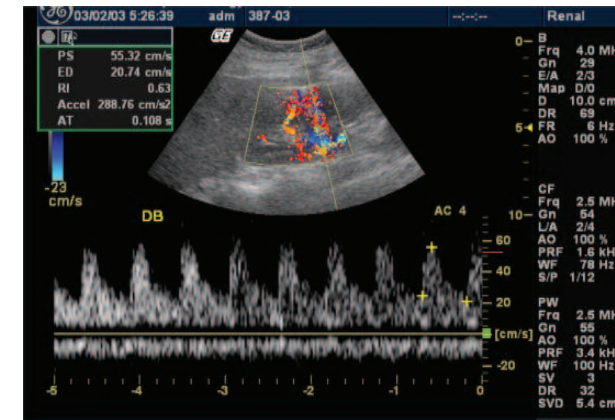
Figure 1 Saccular aneurysm of abdominal aorta in longitudinal (a) and transversal scan with mural (parietal) thrombi. Colour Doppler is also shown (c). The arrow shows microcalcifications.



It is very important to assess whether the aneurysm is infrarenal or if it affects renal arteries. If AAA is infrarenal it is relatively easy for the surgeon to preserve the flow in kidneys during AAA surgery. But if AAA extends to the origin of renal arteries, surgery is much more complicated and may require reimplantation of renal and/or mesenteric arteries [2].

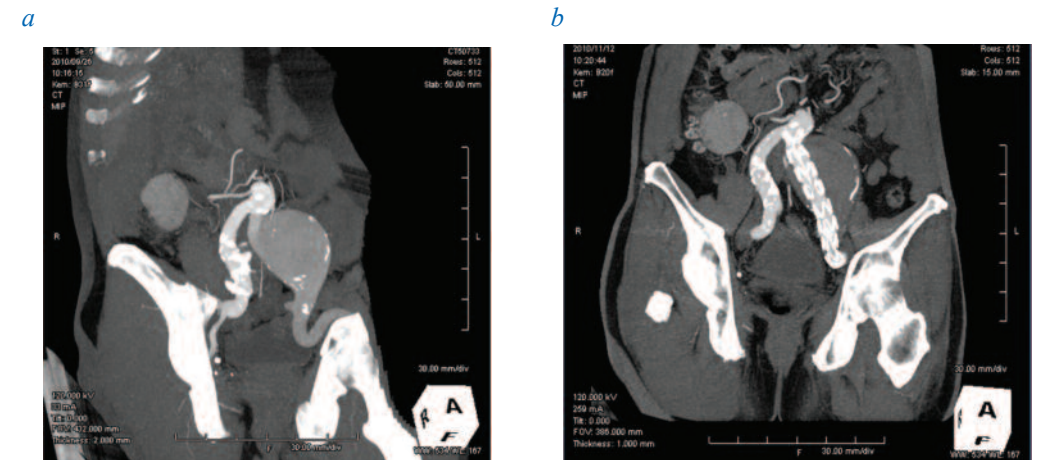
It is useful to analyse features of intrarenal arterial flow during the evaluation of AAA. This topic is discussed elsewhere in this chapter. One should also always carefully examine the kidneys to determine hydronephrosis caused by AAA. Affection of ureters is particularly common with inflammatory aneurysms causing periaortic retroperitoneal fibrosis (Figure 2).

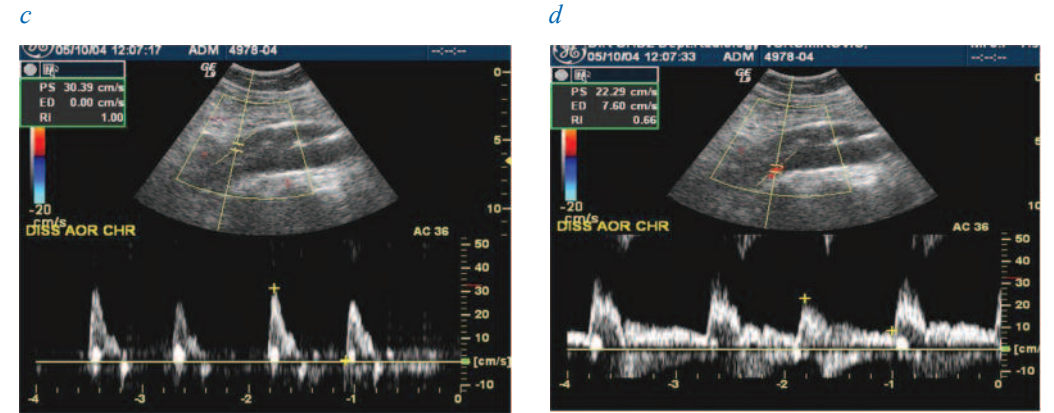
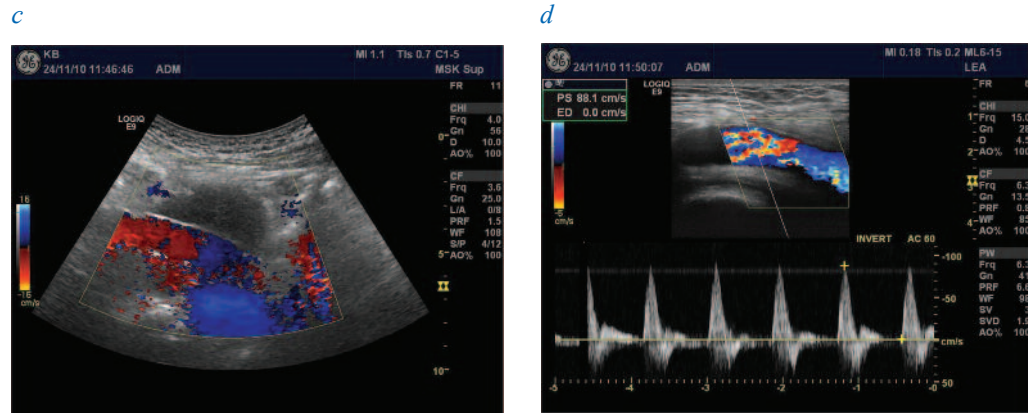
Figure 2 Normal intrarenal arterial Doppler spectra, with normal velocities and normal vascular resistance in a patient with AAA.



The distal end of AAA should be carefully evaluated to determine whether the iliac arteries are also affected. Most iliac artery aneurysms are related to AAA and the common iliac artery is usually affected. Isolated iliac artery aneurysms are seen less commonly and they are very dangerous because they may not be palpated, may be large and may rupture with non-specific symptoms of abdominal or pelvic pain that are unrecognised, with associated high mortality and delayed surgery [1] (Figure 3).

Figure 3 CT angiography of the large isolated left iliac artery aneurysm (a). CT angiography of the same patient after endovascular treatment of iliac artery aneurysm with the stent-graft (b). Colour Doppler image of the patent stent-graft and aneurismal sac excluded from the circulation (c). Normal, triphasic spectra within the stent-graft in iliac artery (d).





Colour Doppler may enable diagnosis of occlusion of renal arteries or of the superior mesenteric artery, but CTA is more accurate than ultrasound. A combination of duplex Doppler and MRA has a similar accuracy compared with CTA in evaluation of all features of aortic aneurysms. In the case of AAA rupture, CT should be performed as it provides the most accurate assessment. Although CTA is superior to ultrasound in diagnosing aortic dissection and other conditions of acute aortic syndrome, ultrasound may lead to the initial suspicion of AAS. In cases of aortic dissection ultrasound may visualise the intimal flap and flow in a true and false lumen (Figure 4). A pseudoaneurysm is shown in Figure 5.

Figure 4 B-mode example of chronic dissection (Dis) of abdominal aorta with the intimal flap clearly visible within the vessel lumen (a). Transverse scan of aorta of the same patient with the flow visible by colour Doppler in both lumina (b). Doppler spectrum demonstrating flow in the true lumen of dissected aorta (c). Doppler spectrum demonstrating flow in the false lumen of dissected aorta (d). A second example is shown using photopic with the flap clearly visible within the vessel lumen (e), panoramic imaging (f) and CEUS (g) with undulating (“WELLE”) flow in the false lumen.

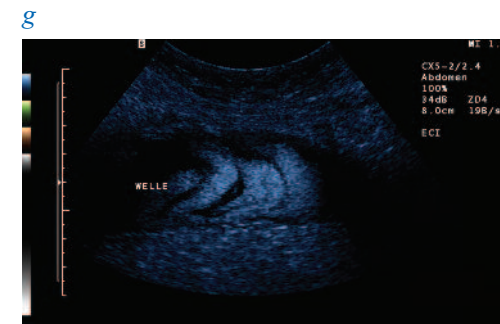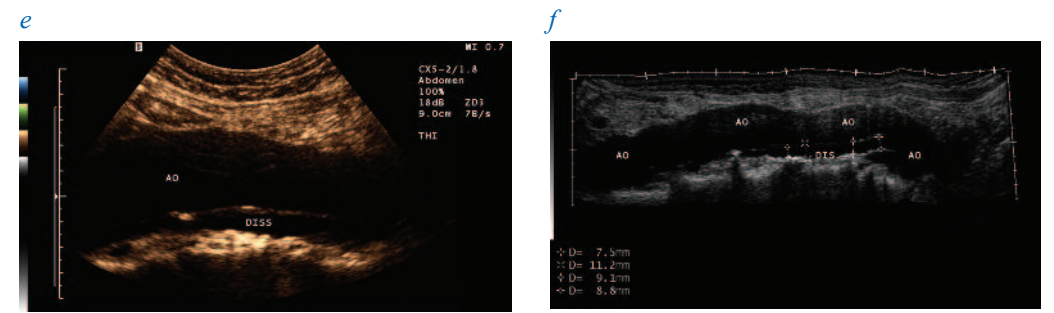
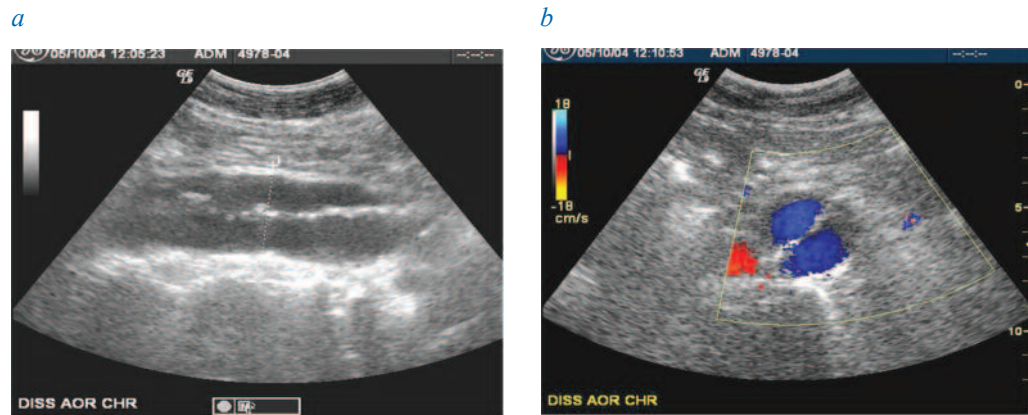
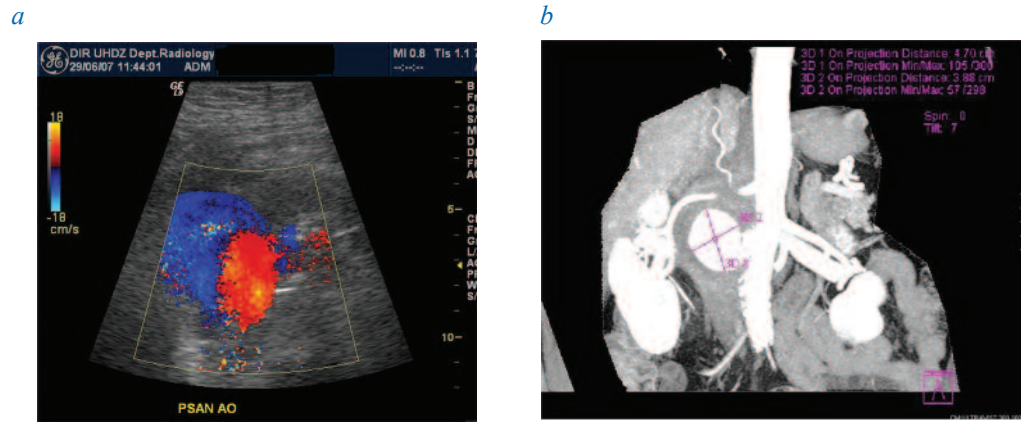


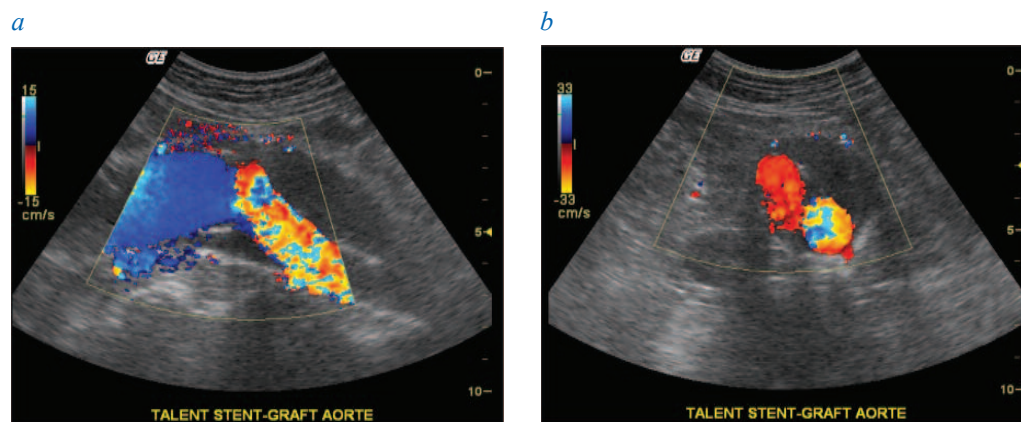
Figure 5 Colour Doppler image of pseudoaneurysm of abdominal aorta in the patient referred to ultrasound to rule out abdominal lymphadenopathy. Incidental finding (a). CT angiography of the same patient confirming diagnosis of abdominal aortic pseudoaneurysm (acute aortic syndrome) – mycotic aneurysm (b).



Doppler has a major role in post-operative evaluation of grafts after surgical resection of AAA. Most commonly, aortobilliic or aortobifemoral grafts are used. Ultrasound demonstrates proximal and distal anastomosis of the graft, all segments of the graft need to be examined to determine dilatation or liquid collections, and stenosis has to be excluded at proximal or distal anastomosis. Colour Doppler can demonstrate occlusion of the graft, stenoses, pseudoaneurysm or true aneurysm. Ultrasound can also demonstrate haematomas or abscesses adjacent to the graft. The graft wall can be easily seen because it is very echogenic [7].

EVAR is a percutaneous procedure of endovascular treatment of AAA or aortic dissection with stent-grafts. The procedure is planned on the basis of CTA. CTA is widely recommended as a method of choice for the follow-up these patients, and to detect complications, which are usually endoleaks [7–10]. Some authors claim that CEUS is even more useful than CTA to detect minimal endoleaks, demonstrating extravasation of contrast medium into the aneurismal sac [11,12] (Figure 6).

Figure 6 Colour Doppler image of flow within the stent graft after EVAR treatment of AAA – longitudinal scan (a). The same patient in transverse scan is shown as well (b).



Doppler ultrasound of the inferior vena cava

The IVC can be examined by placing the ultrasound probe just below the xiphoid process, aiming cranially, and visualising the IVC transversing the diaphragm and entering the right atrium. A different approach is used for the more caudal portion of IVC by using the liver as an acoustic window in a more cranial portion and in classic longitudinal and transversal scans below the liver.

Indications include the assessment of the intravascular volume status in patients with acute and chronic renal failure and dialysis, but also in patients with sepsis, heart failure and other cardiovascular disease.

The diameter of the IVC for the measurement of the caval index should be performed 2cm from the diaphragm where it enters the right atrium (largest diameter of the IVC and the degree of collapse during respiration) [13–17].

In patients with hypovolemia the diameter of the IVC is often decreased and more than 50% collapse. With complete collapse (which rarely happens in the more stiff intrahepatic course of the IVC) the IVC may become difficult to see. In patients with hypervolemia (increased intravascular volume) the IVC diameter is enlarged more than 20–25 mm and none or only minimal collapse is seen on inspiration.

Thrombosis of the IVC refers to the development of solid material within the lumen of any portion of the vessel. The thrombus may be occlusive or non-occlusive and may involve the entire IVC or any segment. There are two main forms: bland (appositional) thrombosis refers to the presence of a simple clot within the vein. Malignant (neoplastic) thrombosis always occurs always as a complication of malignant disease, most often renal carcinoma but other neoplasia have been encountered. Its identification is of prognostic significance as it negatively alters therapy options and upstages the disease.

References

1. Brkljačić B. Vascular Ultrasound. Medicinska naklada, Zagreb, 2010 (In Croatian).
2. Zwiebel WJ. Aortic and iliac aneurysm. *Seminars Ultrasound, CT, MRI* 1992; 13(1):53–68
3. Nevitt MP, Ballard DJ, Hallett JW. Prognosis of abdominal aortic aneurysms. *N Engl J Med* 1989; 321:1009–1014.
4. Mašković J, Cambj-Sapunar L, Grbić Ž, et al. Abdominal aortic aneurysms In: Mašković J (Ed). Selected topics of interventional radiology. Medical Faculty, University of Split, Split 2008; pp. 306-43 (in Croatian).
5. Fuyama Y, Hamada R, Uehara R, Yano I, Fujiwara M, Matoba M, i dr. Long-term follow up of abdominal aortic aneurysm complicating Kawasaki disease: comparison of the effectiveness of different imaging methods. *Acta Paediatr Jpn* 1996; 38(3):252–255.
6. Carriero A, Iezzi A, Magarelli N, Filippone A, Merlino B, Ambrosini R, Bonomo L. Magnetic resonance angiography and colour-Doppler sonography in the evaluation of abdominal aortic aneurysm. *Eur Radiol* 1997; 7(9):1495–1500.
7. Raithel D. Surveillance of patients after abdominal aortic aneurysm repair with endovascular grafting or conventional treatment. *J Mal Vasc* 1998;23(5):390–392.
8. Kronzon I, Tunick PA, Rosen R, Riles T. Ultrasound evaluation of endovascular repair of abdominal aortic aneurysms. *J Am Soc Echocardiogr* 1998; 11(4):377–380.
9. Cambj-Sapunar L. Endovascular aortic repair. *European Radiology* 2009; 19 (Suppl 1): S70.
10. Bargellini I, Cioni R, Napoli V, et al. Ultrasonographic surveillance with selective CTA after endovascular repair of abdominal aortic aneurysms. *J Endovasc Ther* 2009;16(1):93-104.
11. Quaia E. Detection of endoleak after endovascular abdominal aortic aneurysm repair. U: Quaia E (Ur). Contrast media in ultrasonography – basic principles and clinical applications. Springer, Berlin 2005; pp. 111-6
12. Napoli V, Bargellini I, Sardella SG, et al. Abdominal aortic aneurysm: contrast-enhanced ultrasound for missed endoleaks after endoluminal repair. *Radiology* 2004; 233(1):217-25.
13. Dietrich CF, Becker D. Farbduplexsonographie des Abdomens. Schnetztor Verlag Konstanz 2002, pp 1-265.
14. Blehar DJ, Dickman E, Gaspari R. Identification of congestive heart failure via respiratory variation of inferior vena cava diameter. *Am J Emerg Med* 2009;27:71-75.
15. Feissel M, Michard F, Faller JP, et al. The respiratory variation in inferior vena cava diameter as a guide to fluid therapy. *Intensive Care Med* 2004;30:1834-7.
16. Fields JM, Lee PA, Jenq KY, et al. The interrater reliability of inferior vena cava ultrasound by bedside clinician sonographers in emergency department patients. *Acad Emerg Med* 2011;18:98-101.
17. Kircher BJ, Himelman RB, Schiller NB. Noninvasive estimation of right atrial pressure from the inspiratory collapse of the inferior vena cava. *Am J Cardiol* 1990;66:493-6.

Doppler ultrasound of visceral arteries

Colour duplex Doppler in the diagnosis of diseases of the visceral arteries and chronic mesenteric ischaemia is not a common diagnosis of liver vessels or kidney circulation. These examinations are technically demanding. The main indication is evaluation of insufficient flow in the visceral arteries in patients who have abdominal pain and require ultrasound examination of the coeliac trunk, superior and inferior mesenteric artery. Modern ultrasound scanners allow the visualisation of flow in the bowel wall, and colour Doppler is mostly used to evaluate inflammatory hyperaemia in inflammatory bowel disease.

Low-frequency transducers are usually used to evaluate visceral arteries, in the frequency range of 2.5–3.5 MHz. In thin patients or children, high-frequency transducers can sometimes be used. To visualise the flow in the intestinal wall, higher-frequency transducers may be used. Patients should fast for 12 h prior to the examination to reduce air in the bowel lumen.

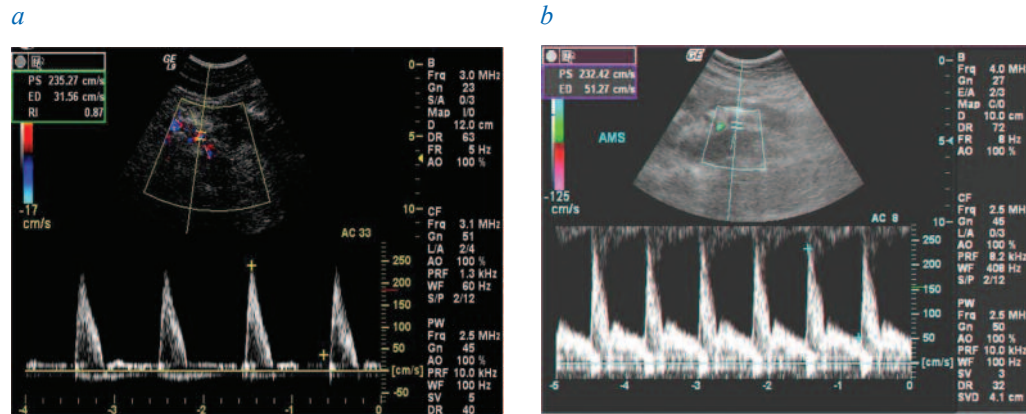
The coeliac trunk and superior mesenteric artery are best seen in longitudinal section through the aorta. Axial section demonstrates branching of the coeliac trunk to the splenic artery, coursing to the left, and the main hepatic artery coursing to the right side. The superior mesenteric artery does not have branches and is located inferiorly to the coeliac trunk, so that these two arteries can be easily distinguished [1–3].

The coeliac trunk and superior mesenteric artery perfuse the duodenum, small bowel and proximal large bowel. The inferior mesenteric artery (IMA) is the smallest of the three visceral arteries; it can be seen with duplex Doppler in 89% of healthy people [4]. IMA is easy to demonstrate when the coeliac trunk and superior mesenteric artery are stenosed or occluded, because it dilates in these cases. IMA originates from aorta anterolaterally on the left side, and courses towards the left hip. An abundant collateral arterial network exists between the visceral arteries, including pancreaticoduodenal arcades, Riolan arch and Drummond's artery [1–5].

Several segments of the arteries should be examined so as not to overlook focal stenosis. Spectral analysis should commence at the arterial origin, and continue distally in the visible segment of the vessel. Colour Doppler is very helpful to localise flow in these arteries.

Typical spectra in the coeliac trunk are of low-resistance type, with continuous, relatively high diastolic flow, reflecting low peripheral resistance. Similar spectra are visible in SMA after eating, but during fasting high-resistance spectra are seen in SMA with retrograde early diastolic flow (Figure 7).

Figure 7 High-resistance Doppler spectrum in superior mesenteric artery in a patient who fasted for 8 hours. Short retrograde early diastolic flow is visible (a). Spectrum in SMA of the same patient after the meal; continuous antegrade diastolic flow is visible (b). Due to the insonation angle the velocity seems to be overestimated.



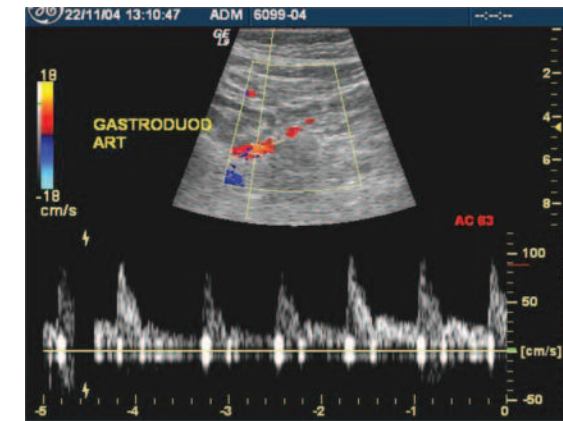
It is important to evaluate the direction of flow in the visceral artery, and particularly in the gastroduodenal artery (GDA) — the branch of the common hepatic artery that is used as a collateral channel in coeliac trunk occlusion. IMA normally has high-resistance Doppler spectra [1–5].

Doppler in diagnosis of mesenteric ischaemia

Acute mesenteric ischaemia is caused by sudden thrombosis and represents an acute condition. The patient is in a lot of pain, their life is at risk and they require urgent diagnosis and intervention. CTA is commonly used to diagnose this condition.

Chronic mesenteric ischaemia develops slowly and ultrasound is used to diagnose the condition. Occlusion can be diagnosed when flow is not detectable within the arterial lumen. In this case collateral flow may be demonstrated, the artery fills distally from the occlusion through collaterals. Retrograde flow can be seen in the arteries used as collateral conduits. For example, in cases of occlusion or high-grade stenosis of the main coeliac trunk the proper hepatic artery is filled over the GDA, in which retrograde flow can be seen both with colour Doppler and spectral analysis. GDA can be found in the posterior part of the pancreatic head. It normally has high-resistance spectra since it supplies the intestinal system. When the coeliac trunk is occluded it receives blood from the SMA over the pancreaticoduodenal artery and the flow direction is reversed; spectra are of the low-resistance type because the artery, in that case, supplies the liver that has low vascular resistance. Analysis of flow in the GDA is an important additional Doppler sign in diagnosing stenosis or occlusion of the coeliac trunk (Figure 8).

Figure 8 Retrograde flow in gastroduodenal artery (towards the liver) and low-resistance spectra – collateral flow in coeliac trunk occlusion.



Even if a short proximal segment of the coeliac trunk is occluded, flow can still be visible because the blood returns from the hepatic artery, supplying the splenic artery. Therefore the direction of flow in the hepatic artery has to be carefully analysed so as not to overlook occlusion of the origin of the coeliac trunk. Demonstration of retrograde flow in the hepatic artery is relatively easy.

In cases of significant stenosis (diameter reduction >50%) of the artery, elevation of velocities is observed at the site of stenosis, with post-stenotic changes (turbulence, disorganisation of flow at spectral analysis). A very important parameter to diagnose stenosis is focal elevation of velocity and one has to be careful not to misinterpret velocity changes caused by tortuous arteries. Peak systolic velocities at the site of stenosis have to be compared with prestenotic arterial segments. In cases of significant SMA stenosis after fasting, physiological retrograde diastolic flow is lacking, and antegrade spectral components are emphasised. A lack of retrograde diastolic components are seen in diabetic patients with diabetic nephropathy who may not have significant mesenteric vascular disease. One should always remember that in healthy people after eating, continuous antegrade diastolic flow is seen, and therefore all patients need to be examined after fasting. Low-resistance Doppler spectra after fasting indicates a high-degree of stenosis of SMA. Doppler findings of parvus-tardus spectra in SMA and the hepatic artery are not reliable signs of significant proximal stenosis because, unlike in renal artery stenosis, abundant collateral circulation develops [1,5,6].

Chronic mesenteric ischaemia (intestinal angina) manifests when the coeliac trunk, SMA and IMA cannot provide sufficient perfusion to satisfy the metabolic needs of the intestinal system after a meal. Two out of three vessels usually need to be occluded, or have haemodynamically significant stenosis, for the condition to be manifested. Most commonly simultaneous changes are seen in the coeliac trunk and SMA. Most atherosclerotic lesions that cause clinically manifested mesenteric ischaemia affect proximal segments of the coeliac trunk and SMA, which can be evaluated by duplex Doppler ultrasound. The condition is relatively rare in clinical practice, and the main symptoms are weight loss and post-prandial pain (1–3 hours after a meal), which are also seen in many other, more common, diseases of the gastrointestinal system. Apart from atherosclerosis, which is the most common cause of visceral arteries stenosis/occlusion, other causes may be coeliac trunk compression with diaphragm ligament (lig. arcuatum medianum),

dissection or embolism of these vessels. Median arcuate ligament compression is usually seen in thin young women and symptoms are manifested during expiration, when parvus-tardus spectra may be seen in the hepatic artery and retrograde flow in GDA, while findings normalise on inspiration [1,6].

The most important parameter to diagnose high-degree stenosis is measurement of PSV at the site of stenosis. The range of normal peak systolic velocities in the coeliac trunk is 98–105 cm/s, in SMA 95–140 cm/s and in IMA 95–190 cm/s [7]. Moneta and co-authors recommend threshold values of more than 2 m/s for the coeliac trunk, and more than 2.75 m/s from SMA to diagnose significant stenosis. These criteria are mostly used in clinical practice [8], but some authors recommend a PSV of more than 3 m/s and EDV of more than 45 cm/s as very specific values to diagnose SMA stenosis [9]. PSV at the site of SMA stenosis should be compared with PSV in the aorta, proximal to the origin of the visceral arteries; a ratio >3 indicates high-degree stenosis, even if the PSV is not as high as expected [1] (Figure 9 and 10).

Figure 9 Coeliac trunk stenosis; spectrum demonstrates peak systolic velocity of 4.5 m/s and end diastolic velocity of 1.05 m/s – elevated velocities clearly indicate high-grade stenosis.

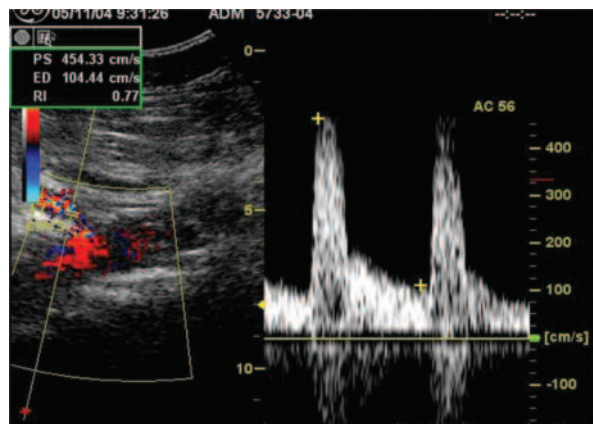
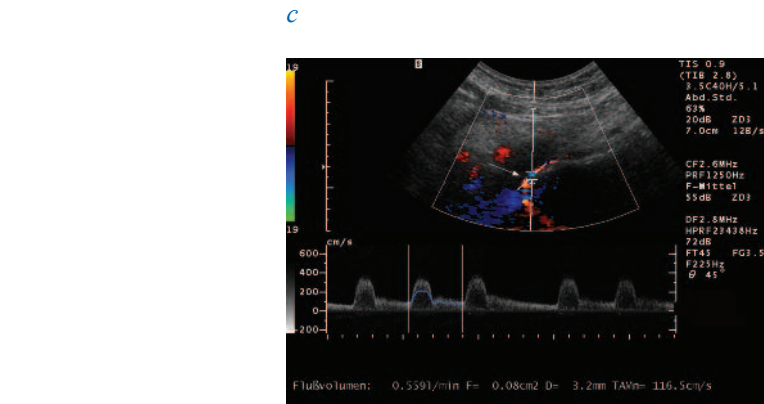
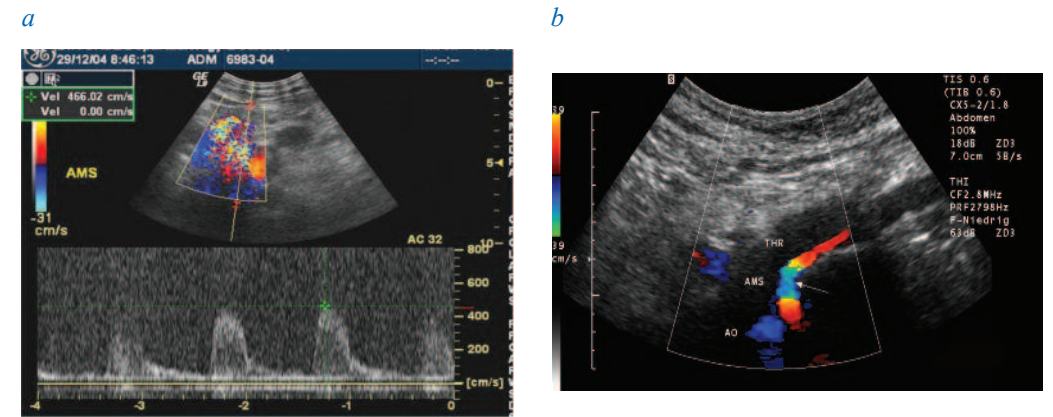


Figure 10 Stenosis of superior mesenteric artery; spectrum demonstrates peak systolic velocity of 4.7 m/s (a). Thrombosis of the superior mesenteric artery is shown as well (b,c).



It is optimal to combine velocity measurements and collateral flow evaluation. The presence of collateral flow may indicate that significant stenosis exists with adequate collateralisation, while absence of collaterals indicates that significant stenosis is lacking or that collateral circulation has not developed. Colour Doppler can demonstrate another collateral pathway – dilated arteries along the medial edge of the descending colon (Riolan’s arch); through these arteries, blood flows retrogradely, filling the SMA in cases of high-degree stenosis or occlusion of the proximal SMA. Normal Doppler findings of the coeliac trunk and SMA normally rule out a diagnosis of intestinal angina. If Doppler demonstrates evidence of chronic mesenteric ischaemia, CTA is regularly used to confirm the diagnosis [1,3,5].

Doppler diagnosis of visceral artery lesions requires manual skills, an experienced operator, optimal examination technique on a high-quality scanner and excellent knowledge of anatomy, physiological and pathological haemodynamics in these arteries.

Aneurysms and pseudoaneurysms of visceral arteries

The most common causes of aneurysm and pseudoaneurysms of the hepatic artery are pancreatitis, trauma (iatrogenic or non-iatrogenic) and degeneration of arterial media. Using B-mode ultrasound these lesions are often misdiagnosed as pancreatic pseudocysts, liver cysts or other non-vascular lesions. This may have serious consequences because some 80% of hepatic artery aneurysms rupture with possible lethal bleeding. The same may happen with splenic artery pseudoaneurysms caused by pancreatitis, which are often misdiagnosed as pancreatic pseudocysts. Colour Doppler and spectral analysis of flow allows the accurate diagnosis, and arteriography can be performed afterwards to plan surgical or endovascular treatment [10] (Figure 11 and 12).

Figure 11 B-mode image of inferior mesenteric artery pseudocyst (a). Colour Doppler image of the same lesion with the flow in both directions (b). Spectral image of the same lesion (c).

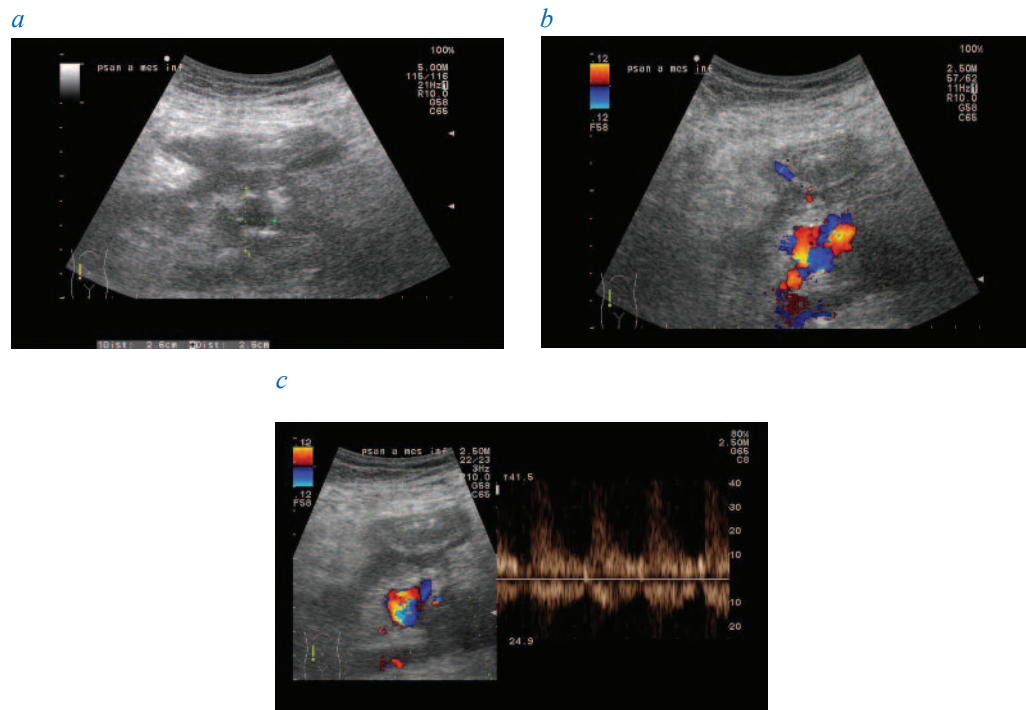
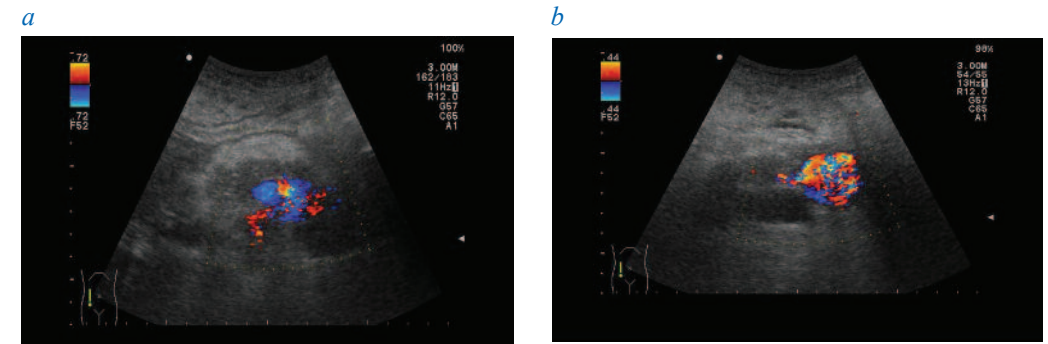


Figure 12 Colour Doppler image of pseudoaneurysm of splenic artery with clearly visible neck and flow in both directions within the PSAN lumen (a). Colour Doppler image of the same patient (b).



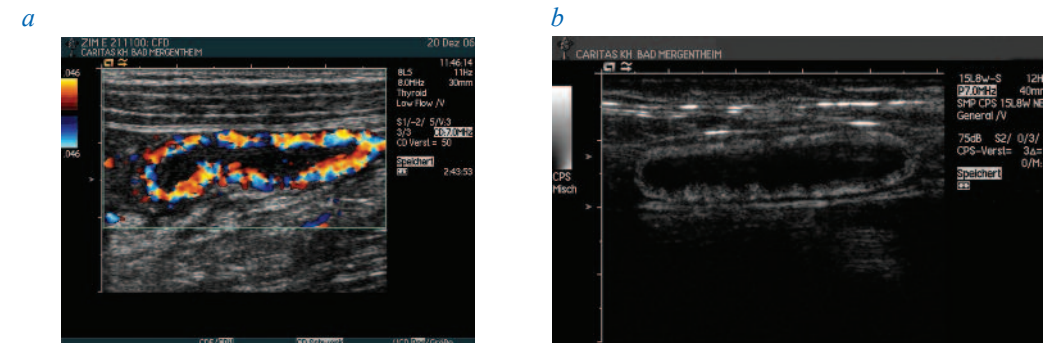
Doppler in inflammatory bowel disease

Ultrasound is a very useful technique to diagnose bowel disease. Inflammation is characterised by vasodilatation in the organ and surrounding tissues, clinically manifested as swelling and redness. Vascular permeability is increased, with subsequent oedema [11]. Inflammatory processes affecting the intestinal wall, with hypervascularisation can be demonstrated by colour Doppler. The number of visible vessels is increased, resistance index is decreased and flow velocities are elevated. Occasionally respiratory phasicity is decreased in some veins. By combining clinical, laboratory, B-mode and colour Doppler data, differential diagnosis can be elucidated in cases of intestinal wall swelling (of inflammatory, neoplastic, vascular or an ischaemic cause) [12,13].

Ultrasound is often the initial imaging modality to diagnose acute appendicitis in children, in who B-mode alterations are the most important for a correct diagnosis. Inflammatory bowel disease in which colour duplex Doppler is useful are: Crohn’s disease, colitis and diverticulitis. The role of ultrasound is less important than laboratory, colonoscopy and clinical findings, but it may contribute to a fast and accurate diagnosis.

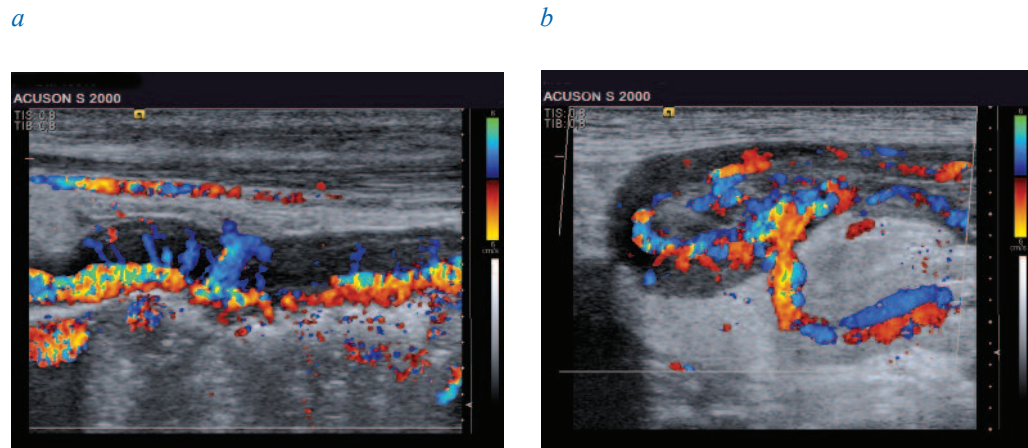
In acute appendicitis, in addition to B-mode findings of appendiceal thickening, luminal distension, mesoappendiceal oedema etc. colour Doppler demonstrates hypervascularisation of the appendix and mesoappendix, and a decrease of vascular resistance [14–16] (Figure 13).

Figure 13 Inflammatory hypervascularisation of appendiceal wall in acute appendicitis, demonstrated with colour Doppler (a) and contrast enhanced ultrasound.



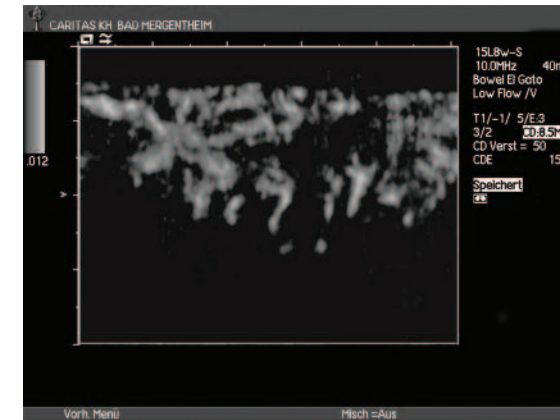
Crohn's disease is often detected by ultrasound, incidentally. Ultrasound is also very useful for the evaluation of activity of the disease by colour Doppler. Transmural disease affects the whole intestinal wall. Ultrasound demonstrates a thickened cecum and/or terminal ileum with surrounding hyperaemia. The combination of oedema and spasm causes the degree of wall thickening changes during the course of the disease. In addition to thickening of the wall, one can see mesenteric oedema, mesenteric lymphadenopathy and abscesses. Mesenteric oedema is demonstrated as hyperechoic tissues surrounding thickened intestine. Colour Doppler shows marked hyperaemia, which is so pronounced that it cannot be compared to other abdominal inflammatory lesions. The number of blood vessels visible by colour Doppler is increased in intestinal wall, mesentery and lymph nodes; resistance-index values are low. Ultrasound is useful for evaluating distribution, activity and extent of the disease and it does not require exposure of the patient to ionising radiation, unlike CT or contrast radiographic studies. This is important, especially because the disease often affects younger age groups [5,17–19] (Figure 14).

Figure 14 Markedly hypervascular intestinal wall in a patient with Crohn's disease – demonstration with Colour Doppler (a). High sophisticated colour Doppler imaging can differentiate the hypervascular submucosal layer, muscle proper penetrating vessels (a) and the supplying mesenteric artery (b).



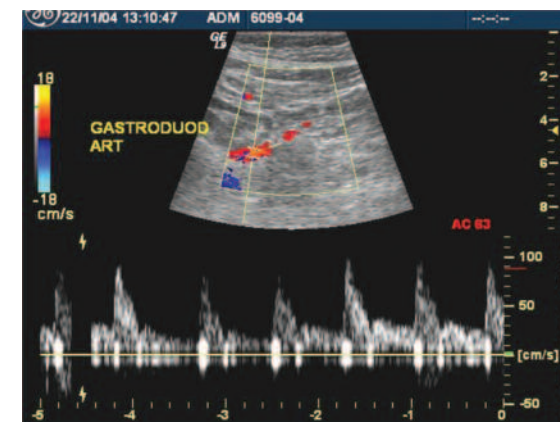
In ulcerous colitis the thickening of the bowel wall is caused by inflammatory activity involving the mucosa and submucosa, and in severe cases also involving the whole intestinal wall [12,13] (Figure 15).

Figure 15 Severe ulcerative colitis with pronounced hypervascularity.



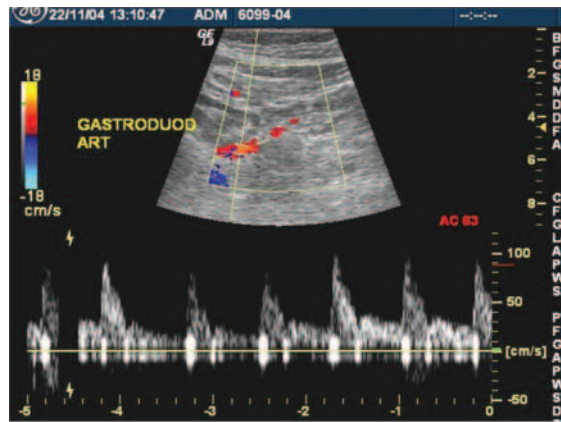
Asymmetric thickening of the colonic wall in ulcerous colitis that lasts a long time should arise the suspicion of colonic cancer. Colour and power Doppler are not very useful for diagnosing bowel cancer, although neovascularisation can be noted along with the B-mode finding of “pseudokidney”, or thickened hypoechoic bowel wall surrounding the central hyperechoic mucosa. Differentiation of inflammatory and neoplastic colon disease with ultrasound is often unreliable [12,13] (Figure 16).

Figure 16 Prominent vascularisation within the wall of a young patient with Burkitt lymphoma of the sigmoid colon and rectum. Colour Doppler display arterial and venous flow.



Ultrasound is a useful method to diagnose acute diverticulitis in typical cases where it develops in the lower left abdominal quadrant. Diverticula are found on the mesenteric side of the bowel, at the point of entrance of the vessels into the colon wall. Thickening is seen there, and is usually accompanied by massive mesenteric oedema that is very hyperechoic, and hypervascularisation is visible with colour Doppler [12] (Figure 17).

Figure 17 Acute diverticulitis: thickened bowel wall, with preserved mucosa and mesenterial oedema. Vascularisation of bowel wall and mesentery demonstrated with colour Doppler.



In conclusion, colour and power Doppler can contribute to the diagnosis of inflammatory bowel disease, since inflammatory hypervascularisation is clearly visible, especially in cases of acute appendicitis, Crohn's disease, coeliac sprue and other acute and chronic inflammatory bowel disease [20–25].

References

- Pellerito JS. Ultrasound assessment of the splanchnic (mesenteric) arteries. U: Zwiebel WJ, Pellerito JS (Ur.) Introduction to Vascular Ultrasonography, Elsevier-Saunders, Philadelphia; 2005: pp. 571-84.
- Nylund K, Odegaard S, Hausken T, et al. Sonography of the small intestine. World J Gastroenterol 2009; 15(11):1319-30.
- Mitchell EL, Moneta GL. Mesenteric duplex scanning. Perspect Vasc Surg Endovasc Ther 2006;18(2):175–83.
- Mirk P, Palazzoni G, Cotroneo AR, di Stasi C, Fileni A. Sonographic and Doppler assessment of the inferior mesenteric artery: normal morphologic and hemodynamic features. Abdom Imaging 1998; 23(4):364–369.
- Dietrich CF, Jedrzejczyk M, Ignee A. Sonographic assessment of splanchnic arteries and the bowel wall. Eur J Radiol 2007; 64:202.
- Armstrong A. Visceral duplex scanning: evaluation before and after intervention for chronic mesenteric ischemia. Perspect Vasc Surg Endovasc Ther 2007;19(4): 386–92.
- Jager K, Bollinger A, Valli C, Ammann R. Measurement of mesenteric blood flow by duplex scan. J Vasc Surg 1986;3:462-9.
- Moneta GL. Screening for mesenteric vascular insufficiency and follow-up of mesenteric artery bypass procedures. Semin Vasc Surg 2001;14(3): 186-92.
- Perko MJ, Just S, Schroeder TV. Importance of diastolic velocities in the detection of celiac and mesenteric artery disease by duplex ultrasound. J Vasc Surg 1997; 26(2):288–293.
- Brkljačić B. Vascular Ultrasound. Medicinska naklada, Zagreb, 2010 (In Croatian)
- Newman JS, Adler RS, Bude RO, Rubin JM. Detection of soft tissue hyperemia: value of power Doppler sonography. AJR 1994; 163:385–9.
- Hagiu C, Badea R. Applicability of abdominal ultrasonography in inflammatory bowel diseases. J Gastrointestin Liver Dis 2007;16(2):205-9.
- Parente F, Greco S, Molteni M, Anderloni A, Bianchi Porro G. Imaging inflammatory bowel disease using bowel ultrasound. Eur J Gastroenterol Hepatol 2005;17(3):283–91.
- Sivit CJ, Applegate KE. Imaging of acute appendicitis in children. Semin Ultrasound CT MR 2003; 24(2):74–82.
- Sivit CJ. Imaging the child with right lower quadrant pain and suspected appendicitis: current concepts. Pediatr Radiol 2004; 34(6):447–53.
- Baldisserotto M, Peletti AB. Is colour Doppler sonography a good method to differentiate normal and abnormal appendices in children? Clin Radiol 2007;62(4):365–9.
- Maconi G, Radice E, Greco S, Bianchi Porro G. Bowel ultrasound in Crohn's disease. Best Pract Res Clin Gastroenterol 2006;20(1):93–112.
- Sjekavica I, Barbarić-Babić V, Krznarić Z, Molnar M, Čuković-Čavka S, Štern-Padovan R. Assessment of Crohn's disease activity by Doppler ultrasound of superior mesenteric artery and mural arteries in thickened bowel wall: cross sectional study. Croat Med J 2007;48(6):822–30.
- Martinez MJ, Ripolles T, Paredes JM, Blanc E, Marti-Bonmati L. Assessment of the extension and the inflammatory activity in Crohn's disease: comparison of ultrasound and MRI. Abdom Imaging 2009; 34(2):141–8.
- Dietrich CF, Becker D. Farbduplexsonographie des Abdomens. Schnetztor Verlag Konstanz 2002, pp 1-265.
- Dietrich CF. Ultrasonography of the small and large intestine. In: UpToDate, Rose BD (Ed), UpToDate, Wellesley MA 2012.

Doppler ultrasound of the aorta, inferior vena cava and visceral arteries

22. Hirche TO, Russler J, Schroder O, Schuessler G, Kappeser P, Caspary WF, Dietrich CF. The value of routinely performed ultrasonography in patients with Crohn disease. *Scand J Gastroenterol* 2002;37:1178-1183
23. Dietrich CF, Brunner V, Lembcke B. Intestinale Sonographie bei seltenen Dünn- und Dickdarmerkrankungen. *Z Gastroenterol* 1998;36:955-970.
24. Dietrich CF, Zeuzem S, Caspary WF, Wehrmann T. Sonographische Lymphknotendarstellung im Abdomen bei gesunden Probanden. *Ultraschall Med* 1998;19:265-269.
25. Dietrich CF, Brunner V, Seifert H, Schreiber-Dietrich D, Caspary WF, Lembcke B. Intestinale B-Bild Sonographie bei Patienten mit einheimischer Sprue. *Ultraschall Med* 1999;20:242-247.