



UNIVERSITÀ  
DEGLI STUDI  
FIRENZE

# FLORE

## Repository istituzionale dell'Università degli Studi di Firenze

### Unsuspected Heart Failure: Usefulness of a Minimally Invasive Hemodynamic Monitoring System

Questa è la Versione finale referata (Post print/Accepted manuscript) della seguente pubblicazione:

*Original Citation:*

Unsuspected Heart Failure: Usefulness of a Minimally Invasive Hemodynamic Monitoring System / Pavoni V; Romagnoli S; Batignani G; Giancesello L; Horton A; Romano SM.. - In: JOURNAL OF ANESTHESIA & CLINICAL RESEARCH. - ISSN 2155-6148. - ELETTRONICO. - 3(2012), pp. 228-230. [10.4172/2155-6148.1000228]

*Availability:*

This version is available at: 2158/781639 since:

*Published version:*

DOI: 10.4172/2155-6148.1000228

*Terms of use:*

Open Access

La pubblicazione è resa disponibile sotto le norme e i termini della licenza di deposito, secondo quanto stabilito dalla Policy per l'accesso aperto dell'Università degli Studi di Firenze (<https://www.sba.unifi.it/upload/policy-oa-2016-1.pdf>)

*Publisher copyright claim:*

(Article begins on next page)

Case Report

Open Access

## Unsuspected Heart Failure: Usefulness of a Minimally Invasive Hemodynamic Monitoring System

Vittorio Pavoni<sup>1</sup>, Stefano Romagnoli<sup>2</sup>, Giacomo Batignani<sup>3</sup>, Lara Giancesello<sup>1\*</sup>, Andrew Horton<sup>4</sup> and Salvatore Mario Romano<sup>2</sup>

<sup>1</sup>Department of Critical Care Medicine, University-Hospital Careggi, Firenze, Italy

<sup>2</sup>Department of Heart and Vessels, University-Hospital Careggi, Firenze, Italy

<sup>3</sup>Department of Abdominal Surgery, University-Hospital Careggi, Firenze, Italy

<sup>4</sup>Administration, Mayo Clinic, Phoenix, AZ, USA

### Abstract

A case of young male, with negative history for heart disease, who was scheduled for abdominal surgery due to an adrenal tumor, is presented. During the surgery, the patient unexpectedly developed bi-ventricular dysfunction. Causes of cardiac dysfunctions as well as the utility of MostCare<sup>®</sup>, an uncalibrated blood pressure wave-based (pulse wave analysis) hemodynamic monitoring system powered by the Pressure Recording Analytical Method (PRAM), are discussed.

### Introduction

Hemodynamic monitoring, by means of a pulmonary artery catheter (PAC), transesophageal echocardiography (TEE), Doppler techniques or pulse contour methods (PCMs) is usually employed in selected high risk patients, who are at risk of developing hemodynamic instability and are undergoing major surgery [1]. These patients may benefit from the monitoring of cardiac output (CO) and other hemodynamic variables, such as stroke volume or pulse pressure variations (SVV, PPV), since an early goal-directed therapy may improve outcome [2]. Patients without co-morbidities or in advanced age are usually excluded from this kind of monitoring due to the invasiveness of some of these techniques. A healthy young man undergoing general abdominal surgery is usually not considered to be high-risk. However even the type of surgery should be taken into account. In the present case report we suggest the importance of using MostCare<sup>®</sup> hemodynamic monitoring to detect severe intraoperative hemodynamic impairment.

### Case Report

A 17-year-old patient was scheduled for abdominal surgery because of an adrenal mass. A preoperative cortisol test showed a level of 470 mM in a 24-hour urine sample; the value of dehydroandrosterone-sulfate (DHEA-S) was 27.1 mcrM/L. The medical history and preoperative cardio-respiratory exams were normal and the patient was a professional soccer player. The day before the surgery, an angiographic embolization of the tumor was performed with the aim of reducing intraoperative bleeding. During the intervention, the following parameters were monitored: arterial blood pressure (ABP, radial artery catheter), heart rate (HR), arterial oxygen saturation and central venous pressure (CVP). In addition, before induction of anesthesia a radial artery catheter was introduced and then it was connected to MostCare<sup>®</sup> by means of a pressure transducer to monitor the uncalibrated blood pressure wave-based hemodynamic [3,4]. MostCare<sup>®</sup>, a monitoring system powered by the Pressure Recording Analytical Method (PRAM), measures and estimates beat-to-beat systolic, diastolic, mean and diastolic blood pressure (SBP, DBP, MBP, DicBP), cardiac output/index (CO/CI), systemic vascular resistances (SVR/SVRI), stroke volume variation (SVV), pulse pressure variation (PPV), peripheral maximal pressure to time ratio ( $dP/dt_{MAX}$ ) and Cardiac Cycle Efficiency (CCE; values -1 to +1), a parameter that expresses the energy expenditure of the heart-circulatory system coupling [5].

The operation was carried out through a bilateral sub costal incision

with xifoid expansion. A huge (20×30 cm) retroperitoneal tumoral mass, dislocating the liver, duodenum, pancreas, and the right kidney was present. The tumor seemed to be adherent, but not infiltrating diaphragmatic retrohepatic vena cava and right renal vein.

During the first twenty minutes of the operation, while surgeons after mobilization of the liver started the isolation of tumoral mass from the main intrabdominal vessels, the mean arterial pressure was normal [6] (SBP: mean 104 standard deviation (SD) 12; DBP mean 70 SD 9 mmHg). The mean of HR was 91 (SD 5) beats/min (Figure 1). At the same time (T1), MostCare<sup>®</sup> showed an unexpected condition of low CI associated with increased SVR: CI 1.5-1.8 l/min/m<sup>2</sup>; SVR 2000 dynes×sec/cm<sup>5</sup> (Figure 2). Lactate levels showed an increase compared to baseline values obtained by an arterial blood sample before induction of anesthesia (3.5 vs.1.2 mEq/l) suggesting a surprising imbalance of oxygen delivery to tissue oxygen needs [7]. In addition, peripheral  $dP/dt_{MAX}$ , a measure of the maximal rate of pressure change over time between two consecutive points along the systolic upstroke (sample rate waveform 1000 Hz), showed very low values even though there was an increased arterial tone (Figure 3). CCE was abnormally low showing a value of -0.8 to -0.9 units, thus indicating very high energy expenditure for the maintenance of the current hemodynamic state (Figure 4).

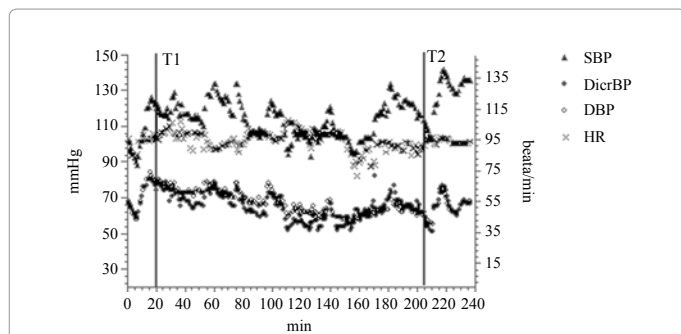
On the basis of the data displayed by MostCare<sup>®</sup>, and after a careful exclusion of the artifacts affecting the blood pressure signal, our objective was to assure an adequate ventricle preload in spite of a PPV value of 13%, a SVV value of 14% and a CVP of 14 mmHg. After excluding a surgical cause of impaired venous return (i.e. mechanical obstruction of liver venous drainage), a fluid overloading with 250 ml of lactate's ringer solution (3.3 ml/Kg) was attempted. After the volume loading, the CVP quickly increased to 20 mmHg without any

\*Corresponding author: Giancesello Lara, Department of Critical Care Medicine, University-Hospital Careggi, Largo Brambilla, 3. 50134 Firenze, Italy, Tel: +39-055-7948416, E-mail: [giancesello.lara@libero.it](mailto:giancesello.lara@libero.it)

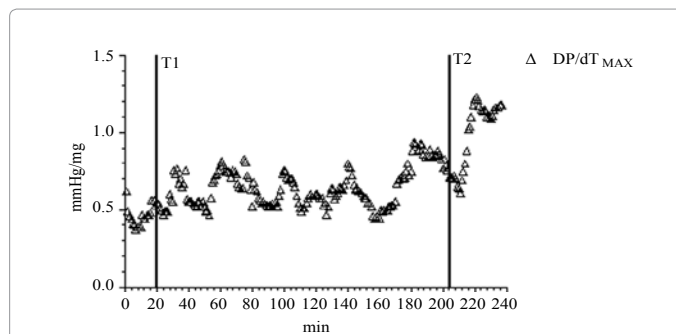
Received July 27, 2012; Accepted August 04, 2012; Published August 11, 2012

Citation: Pavoni V, Romagnoli S, Batignani G, Giancesello L, Horton A, et al. (2012) Unsuspected Heart Failure: Usefulness of a Minimally Invasive Hemodynamic Monitoring System. J Anesth Clin Res 3:228. doi:10.4172/2155-6148.1000228

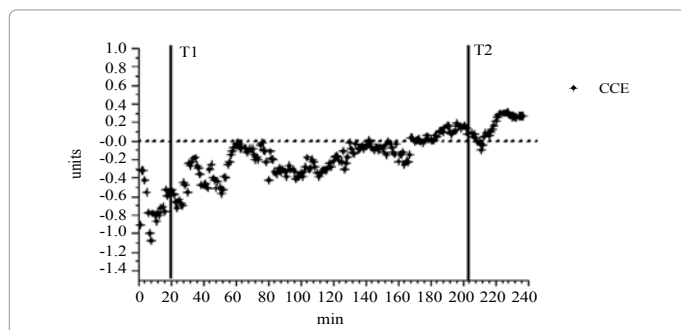
Copyright: © 2012 Pavoni V, et al. This is an open-access article distributed under the terms of the Creative Commons Attribution License, which permits unrestricted use, distribution, and reproduction in any medium, provided the original author and source are credited.



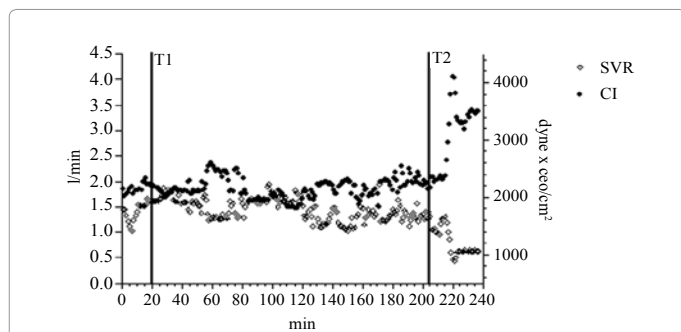
**Figure 1:** Standard monitoring. SBP, systolic blood pressure; DicroBP, dirotic blood pressure; DBP, diastolic blood pressure; HR, heart rate; T1, time of hemodynamic impairment; T2, time of tumor extraction.



**Figure 4:** MostCare®.  $dP/dt_{MAX}$ , maximal rate of pressure change over time.



**Figure 2:** MostCare®. CCE, Cardiac cycle efficiency.



**Figure 3:** MostCare®. CI, cardiac index; SVR, systemic vascular resistances.

improvement in CI, SVR or HR (Figure 1 and Figure 2). Therefore we decided to perform a transesophageal echocardiogram (TEE), in order to exclude other causes of hemodynamic impairment (i.e. cardiac tamponade).

The examination showed systolic dysfunction of both ventricles: left ventricular ejection fraction was 35%; right ventricular fractional area change was an estimated 18% and tricuspid annular plane systolic excursion was at 10 mm. Color-Doppler analyses did not show any valvular regurgitation. The trans-mitral pulsed-wave Doppler pattern was compatible with a left ventricle impaired relaxation (E-wave/A-wave 0.7; deceleration time 250 msec).

No further hemodynamic adjustments were made other than avoiding hypovolemia taking into account that lactate concentration progressively decreased. No other intervention was performed (e.g. inotropic drugs) because it was known that physiologic adaptations,

mainly characterized by compensatory tachycardia and redistribution of blood flow to organs, were capable of compensating for the temporary heart dysfunction. Lactate concentration with blood pressure and diuresis were used as markers of tissue perfusion and oxygenation. At this point the tumor was detached from the diaphragm, the upper pole of the kidney and from the renal vessels tying and cutting the superior and the inferior adrenal arteries and veins, respectively. The medial part of the tumor was dissected from the suprarenal and retro-hepatic vena cava sectioning the middle adrenal artery and the vein. After the isolation from systemic circulation of the tumor and the adrenal remove (T2), CI showed an abrupt increase (Figure 2) and CCE values progressively increased reaching the value of zero in the proximity of the tumor extraction. It is noteworthy that throughout the entire operation SBP remained stable, while DBP and HR showed a slightly decrease (8%). A further TEE, performed at the end of the intervention, showed a global improvement in both left and right ventricular systolic functions (left ventricular ejection fraction= 45%; right ventricular fractional area change= 25% and tricuspid annular plane systolic excursion= 16 mm). After the surgery, the patient was transferred to the general Intensive Care Unit (ICU) for close hemodynamic monitoring until complete recovery of cardiac function was observed during the following 24 hours. The histological examination identified the tumor as an adenocarcinoma and before the discharge of the patient from the hospital the cardiologic examination confirmed a complete recovery of heart function.

Five years after surgery the patient was alive and the follow-up showed that the patient was free of disease.

## Discussion

In the present case, a widely used hemodynamic monitoring system such as PAC or TEE would have been considered unnecessary and inappropriate since the patient was not considered high risk. Nonetheless, an unexpected bi-ventricular dysfunction complicated the course of the intervention. A pressure-based hemodynamic monitoring system, MostCare®, not requiring any adjunctive invasive devices, gave an early warning that allowed focusing on the acute cardiac failure without time delay. Standard monitoring based on invasive blood pressure and HR proved to be incapable of detecting the problem. TEE was performed as a second level monitoring-diagnostic tool with the aim of confirming the hemodynamic imbalances displayed by MostCare®. In spite of low CO, no inotropic support was used because although inotropic agents can be useful in restoring hemodynamic parameters and improving peripheral organ perfusion, they can also increase short-term and long-term mortality. The patient seemed to compensate for heart dysfunction since lactate concentration progressively decreased.

Interestingly, a low CCE value, abnormal for a healthy cardio-vascular system, suggested that compensatory mechanisms affecting the dynamic arterial impedance were activated.

PRAM estimates the cardio-vascular impedance by analyzing point-by-point the arterial waveform sampled with high details (1000 Hz = 1000 values/sec). Cardio-vascular impedance is a complex quantity affected by a number of co-interacting physiologic elements (relationship between pulsatile pressure and flow, arterial tone and stiffness, reflected waves, heart rate and contractility, blood viscosity, etc) and CCE has a strong dependency from the heart-vascular system interaction in terms of cardio-vascular impedance. Therefore, CCE represents the hemodynamic work performed/energetic expenditure ratio giving an estimation of the energetic expenditure performed by the cardiovascular system to keep some kind of hemodynamic balance. It is possible to assess the correlation between different energetic expenditures and CCE as the expression of the ability of the cardiovascular system to keep homeostasis at different energetic levels. As a consequence, trends of CCE can be interpreted as modifications in cardio-vascular impedance and therefore, one of the determinants of ventricular afterload. Although studies focused on CCE are still lacking, a potential role of this parameter in the management of cardio-vascular instability may be arguable.

Moreover, peripheral  $dP/dt_{MAX}$  proposed to be proportional to left ventricle contractile function despite the fact that published studies have reached conflicting results although sampled at low rate (200Hz) [8,9], appeared to be abnormally low despite an increased arterial tone. Peripheral  $dP/dt_{MAX}$  is measured as the maximal rate of pressure change over time measured between two consecutive points along the systolic upstroke.  $DP/dt_{MAX}$  progressively improved in agreement with the TEE findings that showed an increase in left ventricular systolic function. Our pathophysiological explanation of the observed acute ventricular dysfunction was related to the angiographic embolization of the tumor, performed the day before the intervention, with the aim of reducing intraoperative bleeding. The ischemic injury may have led to the production of metabolites with cardio-toxic effects. The improvement in myocardial function observed after the removal of the tumor was explained by the wash-out of toxic metabolites. Moreover, it is possible to hypothesize that the exclusion of the tumor from the systemic circulation resulted in a state of acute hypoadrenocorticism.

Dicrotic pressure was lower than diastolic pressure during the first part of the intervention (DBP: 71 (SD 6); DicroBP: 67 (SD 7) mmHg (Figure 1). This finding can be explained by the combination of low stroke volume and high arteriolar tone as previously observed by McDonald and coworkers [10] and described as a "large secondary pressure wave". Moreover, it strongly suggests the presence of high compliance of the aorta in which the systolic ejection loads the vessels with high potential energy. The aortic pressure closes the aortic valve (dicrotic notch) at a lower pressure level than the diastolic one. In fact, the potential energy is then returned during the diastolic phase with an increase in diastolic pressure, a similar, though not identical, hemodynamic state that can be created by means of the intra-aortic-balloon-pump application. Finally, as described in the present case, the authors believe that hemodynamic monitoring has a fundamental role in identifying unstable clinical conditions before the development of cellular dysfunction. For example, mixed venous oxygen saturation has been used for years to identify inadequate oxygen delivery before cellular damage develops. In our presented case, the PRAM suggested a hemodynamic derangement (low CCE, low CI, and low  $dP/dt_{MAX}$ ) that we chose to confirm and to investigate further with TEE evaluation.

We then decided to transfer the patient to the ICU for continuous monitoring of heart function.

In conclusion, MostCare®, the only PCM which does not need any starting calibration or preloaded data [3,4], showed a severe hemodynamic impairment not detectable by standard monitoring based on blood pressure and HR. PCMs that use preloaded data (patient's demographic and anthropometric characteristics) for vascular impedance evaluation, in presence of normal values of blood pressure and HR, showed that the stroke volume estimation can be deeply affected [4]. The PRAM does not depend on preloaded data and estimates the vascular impedance in vivo during each cardiac beat by analyzing the wave morphology with high detail (1000 Hz). Without hemodynamic monitoring, an acute cardiac insufficiency, like that described in the present case, could have been suspected only after the failure of compensatory mechanisms. Moreover, potential adverse consequences including the risk of fluid overload or incorrect use of vasoactive amines could have worsened the patient condition.

#### Acknowledgements

Published with the written consent of the patient.

#### References

1. Lees N, Hamilton M, Rhodes A (2009) Clinical review: Goal-directed therapy in high risk surgical patients. *Crit Care* 13: 231.
2. Pearse RM, Rhodes A, Grounds RM (2004) Clinical review: How to optimize management of high-risk surgical patients. *Crit Care* 8: 503-507.
3. Romano SM, Pistolesi M (2002) Assessment of cardiac output from systemic arterial pressure in humans. *Crit Care Med* 30: 1834-1841.
4. Romagnoli S, Romano SM (2010) Estimation of hemodynamic parameters by arterial waveform: available technologies. *Anesth Analg* 110: 257-258.
5. Modesti PA, Gamberi T, Bazzini C, Borro M, Romano SM, et al. (2009) Response of serum prothrombin in patients undergoing infrarenal aortic aneurysm repair. *Anesthesiology* 111: 844-854.
6. Pinsky MR, Payen D (2005) Functional hemodynamic monitoring. *Crit Care* 9: 566-572.
7. Valenza F, Aletti G, Fossali T, Chevillard G, Sacconi F, et al. (2005) Lactate as a marker of energy failure in critically ill patients: hypothesis *Crit Care* 9: 588-593.
8. De Hert SG, Robert D, Cromheecke S, Michard F, Nijs J, et al. (2006) Evaluation of left ventricular function in anesthetized patients using femoral artery  $dP/dt_{MAX}$ . *J Cardiothorac Vasc Anesth* 3: 325-330.
9. Sharman JE, Qasem AM, Hanekom L, Gill DS, Lim R, et al. (2007) Radial pressure waveform  $dP/dt_{max}$  is a poor indicator of left ventricular systolic function. *Eur J Clin Invest* 37: 276-281.
10. Nichols WW, O'Rourke MF (2005) McDonald's blood flow in arteries. Theoretical, Experimental and Clinical Principles. 5th edn. London.

#### Submit your next manuscript and get advantages of OMICS Group submissions

##### Unique features:

- User friendly/feasible website-translation of your paper to 50 world's leading languages
- Audio Version of published paper
- Digital articles to share and explore

##### Special features:

- 200 Open Access Journals
- 15,000 editorial team
- 21 days rapid review process
- Quality and quick editorial, review and publication processing
- Indexing at PubMed (partial), Scopus, DOAJ, EBSCO, Index Copernicus and Google Scholar etc
- Sharing Option: Social Networking Enabled
- Authors, Reviewers and Editors rewarded with online Scientific Credits
- Better discount for your subsequent articles

Submit your manuscript at: <http://www.omicsonline.org/submission>