

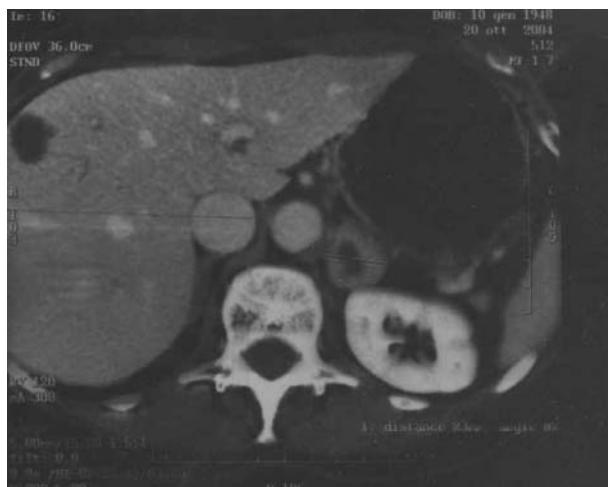

Figure 1. Nodular lesion of the left adrenal gland at computed tomography scan.

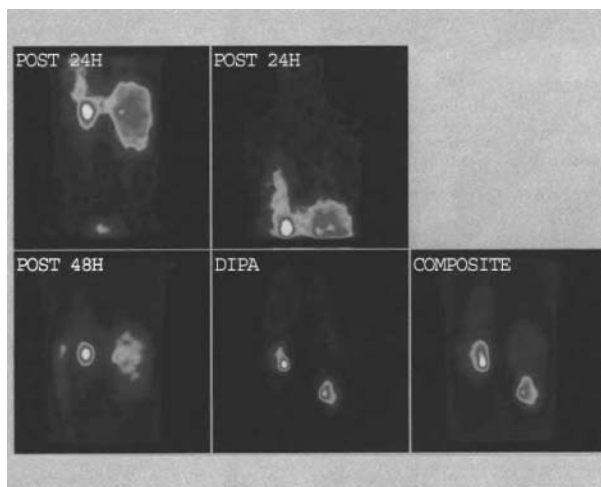


Figure 2. ¹³¹I-meta-iodobenzylguanidine scintigram showing marked uptake at the single location corresponding to the left adrenal gland.

showed marked uptake at the single location corresponding to the left adrenal gland (Fig. 2). After medical stabilisation, left adrenalectomy was performed. During the operation, blood pressure rose to 210/106 mmHg before excision; however, it became stable after resection. The resected tumour (30 x 25 x 23 mm) in the

left adrenal gland was soft, well encapsulated and yellowish-white with haemorrhage. Microscopically, the tumour was diagnosed as pheochromocytoma. Blood pressure and heart rate responses to standing up were normal after the operation. The patient was discharged in good clinical conditions and up to now is asymptomatic.

Editorial comment

Pietro Amedeo Modesti

Clinical Medicine and Cardiology, Department of Critical Care Medicine and Surgery, University of Florence, Florence, Italy

Anecdotes like the one reported by Vanni et al. are bewitching in our times. Together with the history, physical examination is the doctor's best kept secret, powerful, portable, fast, cheap, durable, reproducible and fun^{1,2}, but it must be allowed out of the closet. Young physicians trained in physical examination are dismayed upon first encountering the "hands off" culture of US medicine. The value of "laying on of hands" is often confined to its power to improve communication and trust between doctors and patients, somehow "connecting" them better. This phenomenon is notable, but it is not enough to convince the sceptical among us about the value of a complete clinical examination. It is said not to worry

about the lack of published evidence, the clinical value of physical examination being self-evident. However, the current trend of medical care seems to counteract this optimistic statement. Other medical professionals claim to be bothered by this cultural trend but the role of physical examination in the quality of patient care rarely appears from reading the medical literature. Indeed, research attempted to clarify the accuracy (likelihood ratios) and reliability (kappa statistics) of particular physical findings³, poor attention being paid to the impact of physical examination on the quality of patient care⁴. However, to investigate physical examination as a single diagnostic tool isolated from clinical history and test results taking an instrumental examination as a gold standard, makes little sense clinically. For example, the accuracy of physical examination in the early diagnosis of abdominal aortic aneurysm (sensitivity 68%, specificity 75%)⁵ is obviously markedly inferior to that of abdominal ultrasound (sensitivity 98.9%, specificity 99.9%)^{6,7}. By using a Bayesian approach, it appears that the index of clinical suspicion and the rate of early detection may be increased by the identification of risk factors associated with the development of abdominal aortic aneurysm at clinical history⁸ but a more clinically relevant question remains unanswered: How much physical examination can modify the fate of my patient? Research failed to

Address for correspondence: Prof. Pietro Amedeo Modesti, Clinica Medica e Cardiologia, Dipartimento di Area Critica Medico Chirurgica, Università degli Studi, Viale Morgagni 85, 50134 Firenze, Italy. E-mail: pa.modesti@unifi.it

© 2006 CEPI Srl

approach the role of physical examination in improving the quality of patient care.

In this direction the note by Vanni et al. found its particular value. Pheochromocytoma usually manifests with headache, diaphoresis, palpitation, and paroxysmal or sustained hypertension⁹. In retrospect, this patient's initial signs and symptoms were classic. The symptom triad of headache, sweating, and palpitations would have demanded an immediate evaluation for pheochromocytoma rather than for syncope. This, combined with the failure to perform an accurate preliminary physical examination of the abdomen lead our patient to be included for years among the 13-31% of patients in whom the underlying cause of syncope remains unidentified even after a "thorough evaluation"^{10,11}.

Such anecdotes prove nothing, of course, but they are bewitching.

References

1. Hampton JR, Harrison MJ, Mitchell JR, Prichard JS, Seymour C. Relative contributions of history-taking, physical examination, and laboratory investigation to diagnosis and management of medical outpatients. *BMJ* 1975; 2: 486-9.
2. Peterson MC, Holbrook JH, Von Hales D, Smith NL, Staker LV. Contributions of the history, physical examination, and laboratory investigation in making medical diagnoses. *West J Med* 1992; 156: 163-5.
3. McGee S. Evidence-based physical diagnosis. Philadelphia, PA: WB Saunders, 2001.
4. Reilly BM. Physical examination in the care of medical inpatients: an observational study. *Lancet* 2003; 362: 1100-5.
5. Fink HA, Lederle FA, Roth CS, Bowles CA, Nelson DB, Haas MA. The accuracy of physical examination to detect abdominal aortic aneurysm. *Arch Intern Med* 2000; 160: 833-6.
6. Lindholt JS, Vammen S, Juul S, Henneberg EW, Fasting H. The validity of ultrasonographic scanning as screening method for abdominal aortic aneurysm. *Eur J Vasc Endovasc Surg* 1999; 17: 472-5.
7. Lederle FA, Walker JM, Reinke DB. Selective screening for abdominal aortic aneurysms with physical examination and ultrasound. *Arch Intern Med* 1988; 148: 1753-6.
8. Lynch RM. Accuracy of abdominal examination in the diagnosis of non-ruptured abdominal aortic aneurysm. *Accid Emerg Nurs* 2004; 12: 99-107.
9. Pacak K, Linehan WM, Eisenhofer G, Walther MM, Goldstein DS. Recent advances in genetics, diagnosis, localization, and treatment of pheochromocytoma. *Ann Intern Med* 2001; 134: 315-29.
10. Brignole M, Alboni P, Benditt DG, et al, for the Task Force on Syncope, European Society of Cardiology. Guidelines on management (diagnosis and treatment) of syncope - update 2004. Executive summary. *Eur Heart J* 2004; 25: 2054-72.
11. Miller TH, Kruse JE. Evaluation of syncope. *Am Fam Physician* 2005; 72: 1492-500.