

Intern Emerg Med  
DOI 10.1007/s11739-010-0384-7

IM - PHYSICAL EXAMINATION

## Unintentional although providential iodinated contrast

Luca Naldi · Filippo Fassio · Chiara Alamanni ·  
Maurizio Bartolucci · Ilaria Cecioni ·  
Pietro Amedeo Modesti

Received: 1 March 2010 / Accepted: 18 March 2010  
© SIMI 2010

### Case report

**Luca Naldi, Filippo Fassio, Chiara Alamanni,  
Maurizio Bartolucci**

An 88-year-old man was referred to our Unit for a bowel obstruction. The past history included a diagnosis of chronic obstructive pulmonary disease (COPD) with cor pulmonale treated with anti-cholinergic and glucocorticoid inhalation therapy, as well as prostate cancer. At admission he was periodically drowsy and confused. Arterial gas analysis demonstrated a mild respiratory failure with hypercapnia and normal arterial O<sub>2</sub>-saturation. The EKG showed a sinus rhythm. A few hours later atrial fibrillation began, and the patient was treated with an intravenous infusion of amiodarone, with recovery of a sinus rhythm. An amiodarone oral maintenance regimen was then started.

The bowel obstruction resolved after adequate intravenous fluid infusion and enemas.

A few days thereafter, the patient underwent CT scan of head, thorax and abdomen with contrast media enhancement (iopromide—Ultravist 370, Bayer HealthCare Pharmaceuticals, 100 mL), as suggested by the patient's oncologist.

On return from the Radiology Unit, the patient appeared restless and dyspneic. Physical examination showed tachypnea (respiratory rate 34 breaths/min), reduction of normal vesicular breath sounds and diffuse wheezing. The blood pressure was 140/80 mmHg, with a heart rate of 94 beats/min, and in a sinus rhythm. The pulse oximetry saturation was 83% while inhaling 2 L of oxygen/min by nasal cannula. Oxygen therapy was promptly increased to 8 L/min via pharyngeal cannula; anti-cholinergic drugs, glucocorticoids and short-acting  $\beta$ 2-adrenergic agonists were given via aerosol. Arterial gas analysis parameters showed severe respiratory acidosis (pH 7.17, pCO<sub>2</sub> 78 mmHg, pO<sub>2</sub> 129 mmHg, SaO<sub>2</sub> 99%). Intravenous glucocorticoids (hydrocortisone 1 g), histamine H1 antagonists (chlorphenamine maleate, 20 mg), furosemide (80 mg) and nitrates (17 gamma/min) were administered. As even adrenaline administration was considered in the concern for an iodinated contrast media adverse reaction, the radiologist called in, to inform about the presence of an unusual finding in the patient's CT scans of the thorax: an oval image, strongly radio-opaque, looking just like a pill was present in the right bronchus (Fig. 1). The pill-shaped foreign body, with intense radio-opacity, was identified as the amiodarone pill that the patient was given before going to the Radiology Unit. Emergency bronchoscopy was performed and the foreign body was found just below the carina, plugging the right main bronchus almost completely. After bronchoscopic aspiration of the tablet, the patient's condition gradually improved, and the arterial gas

---

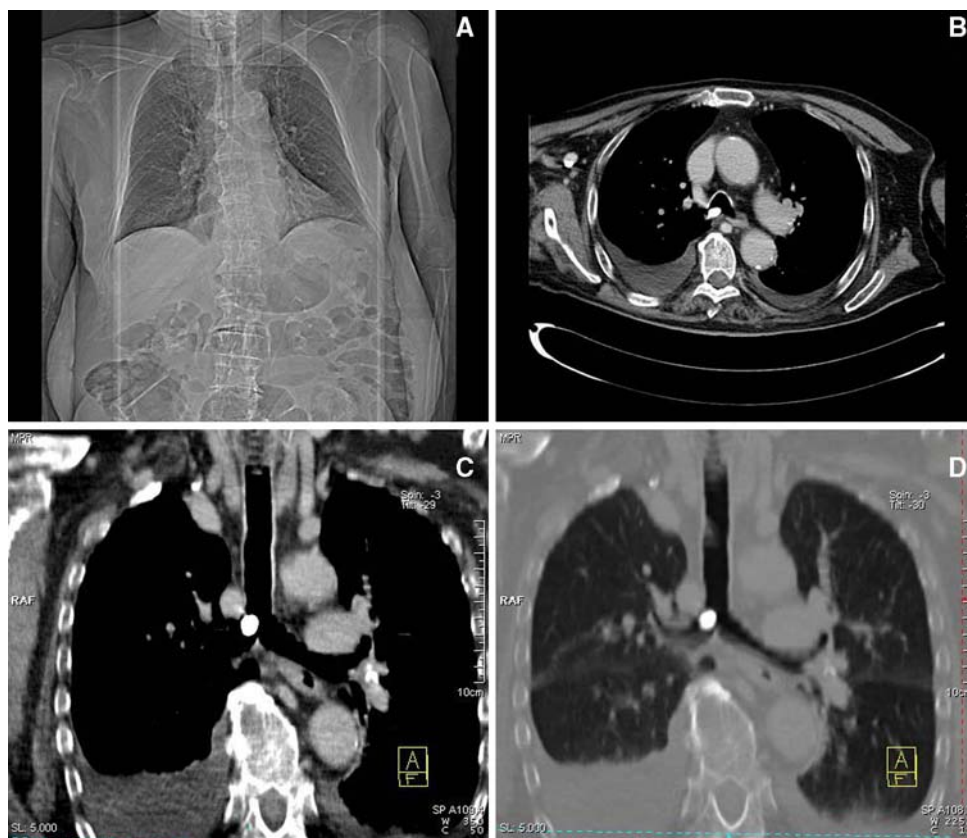
L. Naldi (✉) · F. Fassio · C. Alamanni · I. Cecioni  
Immunology and Cell Therapies Unit,  
Department of Biomedicine, AOU Careggi,  
University of Florence, Viale G.B. Morgagni,  
85, 50134 Florence, Italy  
e-mail: [lucanaldi@virgilio.it](mailto:lucanaldi@virgilio.it)

M. Bartolucci  
Sezione di Radiodiagnostica, Dipartimento di Fisiopatologia  
Clinica, University of Florence, Florence, Italy

P. A. Modesti  
Dipartimento di Area Critica Medico Chirurgica,  
Clinica Medica Generale e Cardiologia,  
University of Florence, Florence, Italy

P. A. Modesti  
Fondazione Don Carlo Gnocchi Onlus IRCCS Centro S. Maria  
Agli Ulivi, Pozzolatico, Italy

**Fig. 1** a Scout view shows a round radio-opaque image projected near the carina. CT thorax scan in axial plane (b), reformatted in coronal plane (c, d) with mediastinum (c) and lung (d) window, demonstrates a high-density endobronchial foreign body at the origin of right main bronchus



analysis returned to baseline levels. On the chest radiograph performed after the procedure, the foreign body was not evident anymore and no further pathological findings were detected.

## Comment

**Ilaria Cecioni, Pietro Amedeo Modesti**

*“Not invisible but unnoticed, Watson. You did not know where to look, and so you missed all that was important.” (from: “A case of identity” in “The adventures of Sherlock Holmes”, Sir Arthur Conan Doyle, 1891).*

Wheezes are adventitious lung sounds superimposed on the normal breath sound [1]. They are continuous (longer than 250 ms) high-pitched sounds with a musical quality predominantly heard in the expiratory phase, often associated with prolonged expiration [2]. Wheezes emanate from the intrathoracic airways, and are produced by an airflow limitation, which can be detected either in healthy subjects during forced expirations [3] or in pathological states of large (central) or small (peripheral) airways [4]. Based on the location of airflow limitation, wheezes can be

disseminated to the entire chest or may be present in a limited area. Wheeze intensity is a poor indicator of the severity of the obstruction: indeed, if the obstruction is extremely severe, the wheeze may become inaudible [4]. Although asthma is the commonest cause of wheeze, all mechanisms narrowing airway caliber, such as bronchospasm, mucosal edema, intraluminal tumor or secretions, foreign body inhalation, and extrinsic or dynamic airway compression may be responsible for the production of these continuous adventitious lung sounds [1, 4]. Wheezes have been described in a proportion of patients (either adults or children) with foreign body inhalation widely ranging from 26 to 51%, alone or together with other signs and/or symptoms [5–7].

The aspiration of a foreign body into the tracheo-bronchial tree can occur in all age groups, although it is significantly more frequent in little children than in adults [5, 8]. Foreign body aspiration in adult patients is often associated with an underlying condition causing impairment of airway protective mechanisms, such as depressed mental status, mental retardation, neurological disorders, impairment in the swallowing reflex, alcohol or sedative abuse, trauma with loss of consciousness, or as a complication of medical procedures such as traumatic intubation or dental care [9]. Although the nature of the foreign body differs according to lifestyle and eating

habits, most foreign bodies in children and in adults are organic in nature [5, 9, 10]. Symptoms associated with the aspiration of a foreign body are heterogeneous, and may range from acute asphyxiation with or without complete airway obstruction, to stridor, dysphonia, cough, dyspnea, or fever, therefore mimicking many other medical conditions presenting with breathing abnormalities [9, 11]. This wide range of clinical presentations can complicate and delay the diagnosis, especially when the clinical history of inhalation is obscure or when chronic lung disease is present [8, 12]. The delay in diagnosis has been described to range from a few hours to some months, and the mean delay seems to be longer in adults than in children [5]. Serious sequels such as pneumonia (with delayed resolution or recurrent in the same areas), pulmonary atelectasis, bronchiectasis [8, 10] or chronic cough [13] may occur in cases of delay in diagnosis.

Although the diagnosis of foreign body aspiration continues to pose a challenge to clinicians as medical history and physical signs are often nonspecific and chest radiographs can be normal in one-fourth of the cases, a symptom triad of wheezing, cough, and decreased air entry should suggest the possibility of a foreign body aspiration [14]. Radio-opacity of the foreign body provides an early and accurate diagnosis, and prevents misinterpretation of the symptoms [8]; indeed, a retrospective review of a 10-year experience involving 3,300 patients undergoing rigid bronchoscopy for suspected foreign body inhalation, shows that the number of radio-opaque foreign bodies is significantly higher in the early diagnosis group [8]. In our case, the high iodine content of amiodarone contributed to the marked radio-opacity of this tablet and consequently to its excellent visibility on the X-ray study. Airway support is the initial treatment for foreign body inhalation, and bronchoscopy can usually accomplish its removal.

This is a quite unique case in which iodine, initially suspected of being the cause of an adverse event, actually

solved the diagnosis, and was providential in saving the patient's life.

**Conflict of interest** None.

## References

1. Meslier N, Charbonneau G, Racineux JL (1995) Wheezes. *Eur Respir J* 8:1942–1948
2. Brand PL, Baraldi E, Bisgaard H et al (2008) Definition, assessment and treatment of wheezing disorders in preschool children: an evidence-based approach. *Eur Respir J* 32:1096–1110
3. Charbonneau G, Sudraud M, Racineux JL, Meslier N, Tuchais E (1987) Forced expirations in normal subjects. Is the shape of the flow rate curve related to existence of a wheeze? *Chest* 92:825–831
4. Mellis C (2009) Respiratory noises: how useful are they clinically? *Pediatr Clin North Am* 56:1–17
5. Baharloo F, Veyckemans F, Francis C, Biettlot MP, Rodenstein DO (1999) Tracheobronchial foreign bodies: presentation and management in children and adults. *Chest* 115:1357–1362
6. Burton EM, Brick WG, Hall JD, Riggs W Jr, Houston CS (1996) Tracheobronchial foreign body aspiration in children. *South Med J* 89:195–198
7. Kiyani G, Gocmen B, Tugtepe H, Karakoc F, Dagli E, Dagli TE (2009) Foreign body aspiration in children: the value of diagnostic criteria. *Int J Pediatr Otorhinolaryngol* 73:963–967
8. Sersar SI, Rizk WH, Bilal M et al (2006) Inhaled foreign bodies: presentation, management and value of history and plain chest radiography in delayed presentation. *Otolaryngol Head Neck Surg* 134:92–99
9. Limper AH, Prakash UB (1990) Tracheobronchial foreign bodies in adults. *Ann Intern Med* 112:604–609
10. Lan RS (1994) Non-asphyxiating tracheobronchial foreign bodies in adults. *Eur Respir J* 7:510–514
11. Rafanan AL, Mehta AC (2001) Adult airway foreign body removal. What's new? *Clin Chest Med* 22:319–330
12. Zissin R, Shapiro-Feinberg M, Rozenman J, Apter S, Smorjik J, Hertz M (2001) CT findings of the chest in adults with aspirated foreign bodies. *Eur Radiol* 11:606–611
13. Nakhosteen JA (1994) Tracheobronchial foreign bodies. *Eur Respir J* 7:429–430
14. Lee P, Culver DA, Farver C, Mehta AC (2002) Syndrome of iron pill aspiration. *Chest* 121:1355–1357