

Low-dose dobutamine nitrate-enhanced technetium 99m sestamibi gated SPECT versus low-dose dobutamine echocardiography for detecting reversible dysfunction in ischemic cardiomyopathy

Mario Leoncini, MD,^a Roberto Sciagrà, MD,^b Francesco Bellandi, MD,^a Mauro Maioli, MD,^a Stelvio Sestini, MD,^c Gabriella Marcucci, MD,^c Angela Coppola, MD,^c Fabio Frascarelli, MD,^a Alberto Mennuti, MD,^c and Roberto P. Dabizzi, MD^a

Background. The simultaneous assessment of perfusion and function with the use of technetium 99m sestamibi gated single photon emission computed tomography (SPECT) is helpful for the detection of myocardial viability, but its value in comparison with more established methods is not yet defined.

Methods and Results. This study compared low-dose dobutamine (LDD) nitrate-enhanced gated SPECT with LDD echocardiography for predicting recovery of regional ventricular function after revascularization in 25 patients with ischemic cardiomyopathy. In both studies, regional function (wall motion and thickening) at rest, during inotropic stimulation, and after revascularization was scored by a 4-point scale. In LDD echocardiography, the prediction of reversible dysfunction was based on the recognition of contractile reserve in asynergic (hypokinetic or a-dyskinetic) segments. In LDD gated sestamibi SPECT, reversible dysfunction was predicted on the basis of perfusion quantification (sestamibi uptake $\geq 50\%$) in a-dyskinetic segments and on the basis of contractile reserve in hypokinetic segments. LDD echocardiography predicted reversible dysfunction with sensitivity, specificity, and global accuracy of 57%, 85%, and 75%, respectively. The sensitivity and specificity of LDD gated SPECT for identifying dysfunctional segments capable of functional recovery were 77% and 88%, respectively, with a diagnostic accuracy of 84% ($P < .02$ vs LDD echocardiography).

Conclusions. The combined use of 2 different markers of viability, such as cellular integrity in a-dyskinetic segments and contractile reserve in hypokinetic segments, as permitted by LDD gated sestamibi SPECT, showed higher predictive accuracy for reversible dysfunction than the assessment of contractile reserve in all asynergic segments with LDD echocardiography. (J Nucl Cardiol 2002;9:402-6.)

Key Words: Echocardiography • gated single photon emission computed tomography • low-dose dobutamine • myocardial viability • sestamibi

The simultaneous assessment of perfusion and function that is possible with the use of gated single photon emission computed tomography (SPECT)¹ is

helpful for detecting myocardial viability.² Moreover, the acquisition of gated SPECT images during low-dose dobutamine (LDD) infusion permits the detection of contractile reserve in asynergic segments,³ with results that are comparable to those of LDD echocardiography.⁴ The combination of perfusion and functional data, including the assessment of contractile reserve, significantly improved the accuracy of nitrate-enhanced technetium 99m sestamibi gated SPECT in detecting viable hibernating myocardium.⁵ However, the value of this combined approach in comparison with a more established method such as LDD echocardiography is still unknown. The aim of this study was to compare LDD nitrate-enhanced gated sestamibi

From the Division of Cardiology,^a and Nuclear Medicine Unit,^c Misericordia e Dolce Hospital, Prato, Nuclear Medicine Unit,^b Department of Clinical Physiopathology, University of Florence, Florence, Italy.

Received for publication Oct 15, 2001; final revision accepted Feb 4, 2002.

Reprint requests: Mario Leoncini, MD, Via del Cittadino 24, 59100, Prato, Italy; r.sciagra@dfc.unifi.it.

Copyright © 2002 by the American Society of Nuclear Cardiology.

1071-3581/2002/\$35.00 + 0 43/1/123856

doi:10.1067/mnc.2002.123856

SPECT with LDD echocardiography for predicting recovery of regional ventricular function after revascularization in patients with chronic coronary artery disease and left ventricular dysfunction.

METHODS

Patient Population

The study group included 25 patients (23 men; age, 58 ± 7 years [mean \pm SD]) with previous myocardial infarction (anterior in 19) and ischemic cardiomyopathy (left ventricular ejection fraction $< 50\%$), who were referred to our laboratory for viability assessment. To be included in the study, the patients had to be scheduled for myocardial revascularization on the basis of the independent judgment of the referring physician. The exclusion criteria were recent myocardial infarction or unstable angina, presence of heart disease other than coronary artery disease, atrial fibrillation, and history of sustained ventricular tachycardia. Diabetes was reported in 9 patients, and hypertension in 7. According to coronary angiography, 8 patients had 1-vessel, 11 had 2-vessel, and 6 had 3-vessel coronary artery disease. The revascularization procedure was coronary artery bypass graft surgery in 10 patients and percutaneous transluminal coronary angioplasty in 15.

Study Protocol

Before revascularization, all patients underwent (1) LDD echocardiography and (2) LDD nitrate-enhanced gated sestamibi SPECT. The studies were performed within 1 week with a 24-hour interval. β -Adrenergic blocking agents were withdrawn 48 hours before the test. After revascularization (109 ± 20 days for surgical revascularization and 67 ± 29 days for coronary angioplasty), resting echocardiography and resting gated sestamibi SPECT were repeated to evaluate regional functional changes. All patients gave written informed consent to participate in the protocol.

Two-dimensional Echocardiography

Two-dimensional echocardiograms were registered with the patients lying in the left lateral decubitus position through use of commercially available echocardiographic equipment (2.5- and 3.5-MHz transducers, Hewlett Packard Sonos 2000) using all available tomographic planes obtainable from the parasternal and apical approach. Each study was recorded on videotape for offline evaluation.

Gated Sestamibi SPECT

The nitrate sestamibi protocol has been described.^{6,7} After 1 hour of sestamibi (1111 MBq [30 mCi]) injection, baseline resting gated SPECT was acquired. Immediately thereafter, the dobutamine study was performed. For the postrevascularization study, the same dose of sestamibi was injected at rest. Images were acquired by a dual-head gamma camera (ADAC Vertex)

equipped with high-resolution collimators, with a 15% window centered on the 140-keV photopeak of Tc-99m. SPECT was performed in step-and-shoot mode, with 32 projections over a 180° elliptical orbit (matrix size, 64×64 ; 45 seconds/projection; 8 frames/cardiac cycle). The studies were reconstructed by filtered backprojection without attenuation or scatter correction and realigned along the heart axis.

LDD Protocol

Dobutamine infusion was started at a dosage of 5 $\mu\text{g}/\text{kg}$ body weight/min for 5 minutes and then increased to 10 $\mu\text{g}/\text{kg}/\text{min}$ for a further 5 minutes.⁴ The intravenous infusion of dobutamine was performed with the patient under continuous electrocardiographic and blood pressure monitoring. Criteria for early interruption included hypotension, angina, and significant ventricular arrhythmia. Echocardiographic images were collected after 3 minutes of the 10- μg dosage. Similarly, gated sestamibi SPECT acquisition was started after 3 minutes of the 10- μg dosage, which was maintained until the acquisition was complete.

Data Analysis

For both echocardiographic and scintigraphic analyses, the left ventricle was divided into 16 segments that were assigned to 1 of the 3 coronary territories according to an established scheme.⁸ In both studies, regional function (wall motion and thickening) was assessed visually by consensus of 2 experienced observers using a 4-point scale (1, normal; 2, hypokinesis; 3, akinesis; 4, dyskinesis). Interobserver and intraobserver agreement for regional functional scoring was previously reported.⁴ Contractile reserve was considered to be present in the LDD studies when segments with abnormal baseline regional function exhibited a decrease of 1 grade or more in regional wall motion score.⁹ For the perfusion study, tracer uptake was quantified with the use of an automated program that identified the segment with peak uptake, set its activity to 100%, and scaled the other segments in percent of peak activity.⁷ In LDD echocardiography, the identification of reversible dysfunction was based on the presence of contractile reserve in baseline asynergic segments (score, ≥ 2). On LDD nitrate-enhanced gated sestamibi SPECT, the identification of reversible dysfunction was based on perfusion quantification (sestamibi uptake $\geq 50\%$) in the instance of baseline a-dyskinetic segments (score, 3-4) and on contractile reserve in baseline hypokinetic segments (score, 2).⁵ An asynergic segment was considered to have functional recovery in the follow-up control when, compared with the respective baseline study, it showed a wall motion improvement of 1 or more grades⁹ or of 2 or more grades in the case of dyskinesia.¹⁰

Statistical Analysis

Results are expressed as mean \pm SD. Continuous variables were compared by the Student *t* test. The comparison of proportions was made by the Fisher exact test. Agreement between baseline gated sestamibi SPECT and echocardiogra-

Table 1. Results of LDD echocardiography and gated sestamibi SPECT in hypokinetic versus a-dyskinetic segments

	Hypokinetic		A-dyskinetic	
	LDD echocardiography	Gated SPECT (contractile reserve)	LDD echocardiography	Gated SPECT (sestamibi activity)
Sensitivity	23/34 (68%)	22/30 (73%)	20/41 (49%)*	36/45 (80%)*
Specificity	30/36 (83%)	42/46 (91%)	81/94 (86%)	70/82 (85%)
Accuracy	53/70 (76%)	64/76 (84%)	101/135 (75%)	106/127 (83%)

* $P < .005$.

phy for regional functional evaluation was assessed by Cohen kappa statistics. $P < .05$ was considered significant.

RESULTS

Baseline and Postrevascularization Regional Ventricular Function

In the 25 patients, a total of 39 vascular territories including 278 segments were successfully revascularized. Of these, 205 (70 hypokinetic) demonstrated abnormal baseline function on echocardiography and 203 (76 hypokinetic) showed abnormal contractility in baseline gated sestamibi SPECT. In the 271 segments evaluated by both techniques (7 segments could not be evaluated by echocardiography), the exact agreement between gated sestamibi SPECT and echocardiography for baseline resting regional function was 56% (153/271; kappa = 0.36). The agreement for precise wall motion score ± 1 was 92% (249/271; kappa = 0.90). After revascularization, 75 abnormal segments (34 hypokinetic) functionally improved on echocardiography and 75 asynergic segments (30 hypokinetic) showed functional recovery on gated sestamibi SPECT. Before revascularization, mean sestamibi activity was 47% \pm 20% in the segments without recovery and 57% \pm 16% in those with reversible dysfunction, and it increased to 52% \pm 18% ($P < .0001$) and 65% \pm 14% ($P < .00001$), respectively, after revascularization.

Prediction of Functional Recovery

Contractile reserve was detected by echocardiography in 62 asynergic segments. The presence of contractile reserve correctly identified 43 asynergic segments with functional recovery; its absence was registered in 111 of 130 segments with unchanged dysfunction after revascularization. Thus sensitivity was 57% and specificity 85%, with an overall accuracy for prediction of functional recovery of 75%. Table 1 details the results of

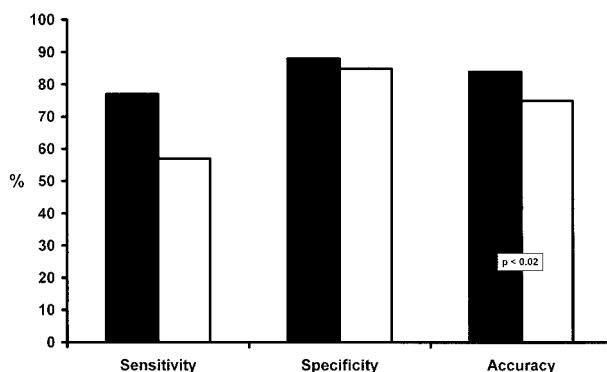


Figure 1. Histogram comparing the results of LDD gated sestamibi SPECT (black bars) versus LDD echocardiography (white bars) for the prediction of reversible dysfunction.

LDD echocardiography in hypokinetic versus akinetic segments.

On gated sestamibi SPECT, contractile reserve correctly classified 64 hypokinetic segments and perfusion quantification 106 a-dyskinetic segments (Table 1). The related sensitivity and specificity values in the whole cohort of asynergic segments were 77% and 88%, respectively, without significant differences from the values obtained by LDD echocardiography. The overall accuracy for prediction of functional recovery was 84%, significantly higher than that registered with the use of LDD echocardiography ($P < .02$) (Figure 1).

DISCUSSION

Gated SPECT permits the detection of hibernating myocardium with the use of 2 different markers of viability, cellular integrity and contractile reserve. Using LDD nitrate-enhanced gated SPECT, we had previously demonstrated that the combination of perfusion quantification and contractile reserve evaluation achieved results that were significantly superior to perfusion or contractile reserve data applied separately.⁵ In this study the identification of myocardial viability based on per-

fusion quantification in a-dyskinetic segments and on contractile reserve detection in hypokinetic segments by means of LDD nitrate-enhanced gated sestamibi SPECT showed higher predictive values for reversible dysfunction than evaluation of contractile reserve in all asynergic segments by means of LDD echocardiography. The significantly higher predictive accuracy of the nuclear technique mainly results from the superior sensitivity in a-dyskinetic segments (80% vs 49%; $P < .005$), and this finding confirms that perfusion quantification is advantageous over contractile reserve evaluation in this most important subset of dysfunctional segments. In previous comparisons between perfusion scintigraphy and LDD echocardiography, the sensitivity of perfusion imaging for the detection of viable hibernating myocardium appeared to be higher than that of echocardiography in a-dyskinetic segments, although its specificity was found to be significantly lower in hypokinetic segments.^{11,12} Histopathologic observations in explanted hearts suggest that cellular integrity and contractile reserve provide complementary data for the assessment of tissue viability.¹³ These findings have been confirmed in clinical settings. The combined evaluation of rest-redistribution thallium 201 and LDD echocardiography significantly enhanced the identification of viable myocardium in patients with chronic coronary artery disease.¹⁴ The main advantage of LDD nitrate-enhanced gated SPECT is that for each subset of dysfunctional segments, the most appropriate viability marker can be used within a single test.

Some limitations of this study must be considered. A longer follow-up could have increased the detection of functional recovery and hence decreased the incidence of apparently false-positive responses for both imaging methods. We used a low-dose infusion protocol. The additional high-dose infusion has been reported to improve the accuracy in identifying viable myocardium, and the biphasic response is considered the most reliable marker of preserved viability when dobutamine echocardiography is used.¹⁵ The ability to monitor functional changes could be an advantage of echocardiography over gated SPECT. However, recent data using short-time collection methods for gated imaging have demonstrated the possibility of assessing the biphasic response as well.¹⁶ Silent restenosis or graft occlusion could not be completely ruled out, because angiography was not performed at follow-up. However, none of the patients had a worsened perfusion pattern after revascularization. Finally, the results of echocardiography could have been improved by the use of cine-loop or quad-screen images.

In conclusion, LDD nitrate-enhanced gated SPECT is a feasible imaging technique, which, in a single study, provides quantification of regional perfusion and evaluation of segmental contractile reserve, thereby obviating

the need for separate tests to predict reversible dysfunction accurately in patients with ischemic cardiomyopathy.

Acknowledgment

The authors have indicated they have no financial conflicts of interest.

References

1. Mansoor MR, Heller GV. Gated SPECT imaging. *Semin Nucl Med* 1999;29:271-8.
2. Levine MG, McGill CC, Ahlberg AW, White MP, Giri S, Shareef B, et al. Functional assessment with electrocardiographic gated single-photon emission computed tomography improves the ability of technetium-99m sestamibi myocardial perfusion imaging to predict myocardial viability in patients undergoing revascularization. *Am J Cardiol* 1999;83:1-5.
3. Everaert H, Vanhove C, Franken PR. Effects of low-dose dobutamine on left ventricular function in normal subjects as assessed by gated single-photon emission tomography myocardial perfusion studies. *Eur J Nucl Med* 1999;26:1298-1303.
4. Leoncini M, Marcucci G, Sciagrà R, Frascarelli F, Traini AM, Mondanelli D, et al. Nitrate-enhanced gated Tc-99m sestamibi SPECT for evaluating regional wall motion at baseline and during low dose dobutamine infusion in patients with chronic coronary artery disease and left ventricular dysfunction. Comparison with two-dimensional echocardiography. *J Nucl Cardiol* 2000;7:426-31.
5. Leoncini M, Marcucci G, Sciagrà R, Frascarelli F, Simonetti I, Bini L, et al. Prediction of functional recovery in patients with chronic coronary artery disease and left ventricular dysfunction combining the evaluation of myocardial perfusion and contractile reserve using nitrate-enhanced technetium-99m sestamibi gated single-photon emission computed tomography and dobutamine stress. *Am J Cardiol* 2001;87:1346-50.
6. Bisi G, Sciagrà R, Santoro GM, Fazzini PF. Rest technetium-99m sestamibi tomography in combination with short-term administration of nitrates. feasibility and reliability for prediction of postrevascularization outcome of asynergic territories. *J Am Coll Cardiol* 1994;24:1282-9.
7. Sciagrà R, Bisi G, Santoro GM, Zerauschek F, Sestini S, Pedenovi P, et al. Comparison of baseline-nitrate technetium-99m-sestamibi with rest-redistribution thallium-201 tomography in detecting viable hibernating myocardium and predicting postrevascularization recovery. *J Am Coll Cardiol* 1997;30:384-91.
8. Segar D, Brown SE, Sawada SG, Ryan T, Feigenbaum H. Dobutamine stress echocardiography. correlation with coronary lesion severity as determined by quantitative angiography. *J Am Coll Cardiol* 1992;19:1197-1202.
9. Leoncini M, Marcucci G, Sciagrà R, Mondanelli D, Traini AM, Magni M, et al. Comparison of baseline and low-dose dobutamine technetium-99m sestamibi scintigraphy with low-dose dobutamine echocardiography for predicting functional recovery after revascularization. *Am J Cardiol* 2000;86:153-7.
10. Meluzin J, Cerný J, Frélich M, Stetka F, Spinarova L, Popelova J, et al. Prognostic value of the amount of dysfunctional but viable myocardium in revascularized patients with coronary artery disease and left ventricular dysfunction. *J Am Coll Cardiol* 1998;32:912-20.

11. Perrone-Filardi P, Pace L, Prastaro M, Squame F, Betocchi S, Soricelli A. Assessment of myocardial viability in patients with chronic coronary artery disease. Rest-4-hour-24-hour ²⁰¹Tl tomography versus dobutamine echocardiography. *Circulation* 1996;94:2712-9.
12. Qureshi U, Nagueh SF, Afridi I, Vaduganathan P, Blaustein A, Verani M, et al. Dobutamine echocardiography and quantitative rest-redistribution ²⁰¹Tl tomography in myocardial hibernation. Relation of contractile reserve to ²⁰¹Tl uptake and comparative prediction of recovery of function. *Circulation* 1997;95:626-35.
13. Baumgartener H, Porenta G, Lau YK, Wutte M, Klaar U, Mehrabi M, et al. Assessment of myocardial viability by dobutamine echocardiography, positron emission tomography and thallium-201 SPECT. Correlation with histopathology in explanted hearts. *J Am Coll Cardiol* 1998;32:1701-8.
14. Pace L, Perrone-Filardi P, Mainenti P, Pastraro M, Vezzuto P, Varrone A, et al. Combined evaluation of rest-redistribution thallium-201 tomography and low-dose dobutamine echocardiography enhances the identification of viable myocardium in patients with chronic coronary artery disease. *Eur J Nucl Med* 1998;25:744-750.
15. Afridi I, Kleiman NS, Raizner AE, Zoghbi WA. Dobutamine echocardiography in myocardial hibernation. Optimal dose and accuracy in predicting recovery of ventricular function after coronary angioplasty. *Circulation* 1995;91:663-70.
16. Kumina SS, Cho K, Nakajo H, Toba M, Kijima T, Mizumara S, et al. Serial assessment of left ventricular function during dobutamine stress by means of electrocardiography-gated myocardial SPECT: combination with dual-isotope myocardial perfusion SPECT for detection of ischemic heart disease. *J Nucl Cardiol* 2001;8:152-8.