



UNIVERSITÀ
DEGLI STUDI
FIRENZE

FLORE

Repository istituzionale dell'Università degli Studi di Firenze

Collateral circulation in occlusion of lower limbs arteries: an anatomical study and statistical research in 35 old subjects.

Questa è la Versione finale referata (Post print/Accepted manuscript) della seguente pubblicazione:

Original Citation:

Collateral circulation in occlusion of lower limbs arteries: an anatomical study and statistical research in 35 old subjects / C.Macchi;F.Giannelli;F.Cecchi;L.Corcoss;F.Repice;C.Catini C;E.Brizzi.. - In: ITALIAN JOURNAL OF ANATOMY AND EMBRYOLOGY. - ISSN 1122-6714. - STAMPA. - 101(1996), pp. 89-96.

Availability:

This version is available at: 2158/681349 since:

Terms of use:

Open Access

La pubblicazione è resa disponibile sotto le norme e i termini della licenza di deposito, secondo quanto stabilito dalla Policy per l'accesso aperto dell'Università degli Studi di Firenze (<https://www.sba.unifi.it/upload/policy-oa-2016-1.pdf>)

Publisher copyright claim:

(Article begins on next page)

Collateral circulation in occlusion of lower limbs arteries: an anatomical study and statistical research in 35 old subjects.

Claudio Macchi */**** - Fabrizio Giannelli *** - Francesca Cecchi ***
Leonardo Corcos ** - Francesco Repice * - Claudio Cantini * and Enzo Brizzi *

* Department of Human Anatomy and Histology, University of Study of Florence, Italy

** Department of Surgery, University of Sassari, Italy

*** Proserpius Institute, Florence, Italy

**** Pro-Juventute Foundation Don C. Gnocchi, Pozzolatico, Florence, Italy.

Key words: lower limbs, collateral circulation, echo-color-doppler.

SUMMARY

The collateral circles formed following lower limbs arterial occlusion and their hemodynamic function have been described; 35 subjects (23 men and 12 women; age range 65 to 80), with symptomatic lower limbs obstructive arteriopathy (Fontaine's stage II) following occlusion of vessels downstream the subrenal aorta have been studied by means of Contrast Angiography and Color Doppler Echography of the vascular district including the terminal aorta and the lower limbs arteries.

The hemodynamic significance of the collateral circles was assessed by calculating the Windsor index. In this population, the collateral circles for each level of obstruction were explored. Occlusion of the terminal abdominal aorta: the collateral circle was mainly established through the inferior mesenteric and ischiatic arteries and through the lumbar, ilio-lumbar and gluteal arteries; occlusion of the iliac tract: the collateral circulation was established through the spermatic or ovarian artery and through the funicular, external pudendal and middle sacral arteries; occlusion of the ilio-femoral tract: the collateral circulation was formed by the internal and external pudendal arteries and by the ilio-lumbar, obturator, gluteal and circumflex iliac arteries; occlusion of first tract of the superficial femoral artery: collateral circulation was established through the deep femoral artery and through the perforating arteries; occlusion of the terminal tract of the superficial femoral artery: collateral circulation was formed by the articular branches of the same artery originating proximal to the occlusion and through branches of the deep femoral artery; occlusion of the superficial and deep femoral arteries at their origin: collateral circulation was established through the ischiatic artery (directly and, indirectly, through the perforating arteries), and through the tegumental arteries. The hemodynamic significance, as measured by Windsor index was higher the more proximal was the occlusion, in accord with the lower caliber and/or number of vessels involved in the collateral circles.

INTRODUCTION

Vascular surgery is a rapidly growing speciality, and many reconstructive techniques are now available (Vollmar, 1967). In lower limb obstructive arteriopathy, where ischemia often led to limb amputation, biological or artificial arterial prostheses can now be applied often ensuring adequate perfusion to the districts distal to the stenotic or occluded tract (Cutler and Thompson, 1974; Dale, 1976; Johnson, 1979).

The choice of type of surgical intervention requires an accurate study of the collateral circles that have been or may be formed. Contrast Angiography (CA) is mandatory, but sometimes this technique does not allow correct anatomical identification of the vessels. Combining CA with Color Doppler Ecography (CDE), that displays simultaneously the vessels and the surrounding tissues, may often overcome this drawback.

Many authors have studied the collateral circulation in lower limbs obstructive arteriopathy, by means of CA in the living subject and of coloured resins in the cadaver (Salmon, 1939; Mercier and Vanneville, 1968; Renard *et al.*, 1974), but there is no study in the literature which combines the use of CA and CDE. Our purpose is the accurate description of the collateral circulation in obstructive arteriopathy distal to the subrenal aorta by means of CA and CDE.

MATERIAL AND METHODS

We have studied 35 subjects (23 men and 12 women; age range 65 to 80), with symptomatic lower limbs obstructive arteriopathy (Fontaine's stage II) following occlusion of vessels downstream the subrenal aorta.

Given their informed consent, each subject underwent CA of the aorto-iliac and lower limbs arterial district. A morphological and velocimetric study of the same districts the performed by CDE.

The hemodynamic significance of the collateral circles was assessed by calculating the Windsor index (WI), expressed by the formula: $WI = (dP \times 100)/hP$, were dP = systolic arterial pressure at the anterior or posterior tibialis artery or the average of the two measurements when both are possible; hP = humeral systolic arterial pressure.

A Philips DVI2 digital subtraction unit was used for CA, and an Acuson 128XP echo color doppler equipped by 5 and 7 MHz probes was used for CDE.

Radiologic, ultrasonographic and hemodynamic data were correlated with age, sex, and body surface area using Student's "T" test.

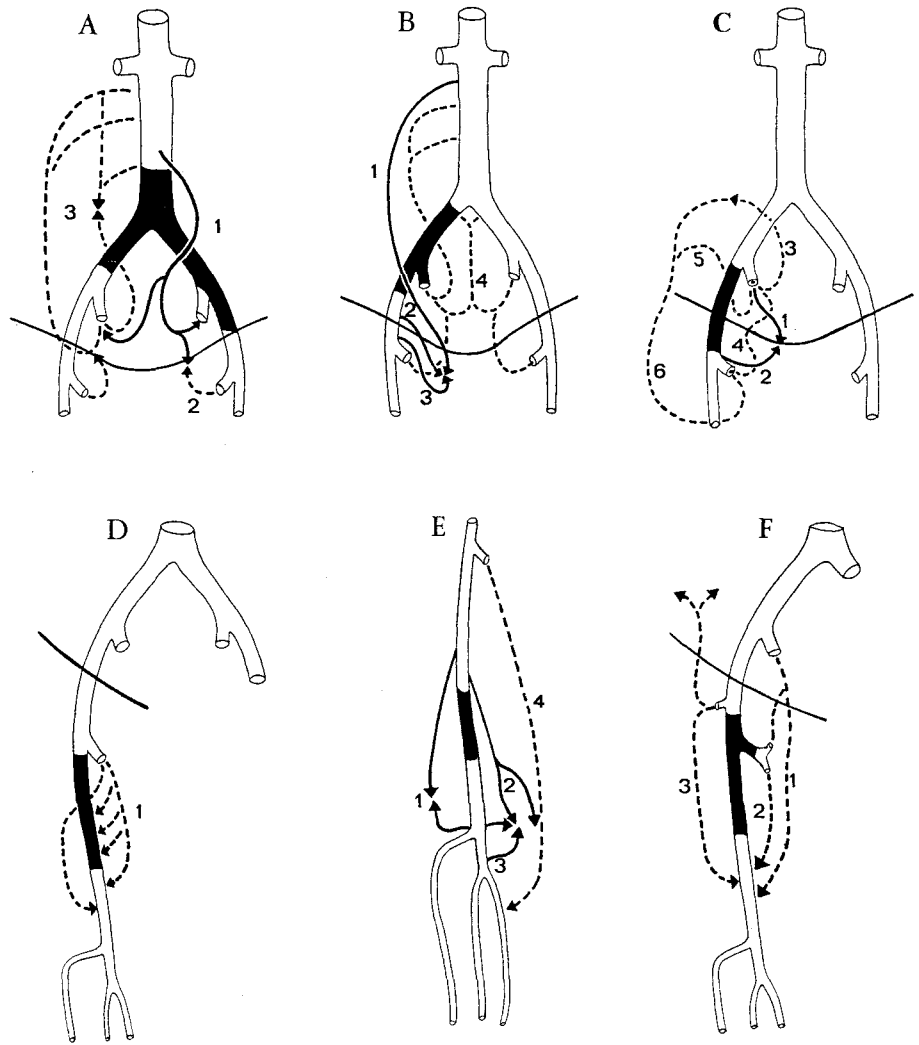
RESULTS

Results are presented separately for each level of vascular occlusion:

— occlusion of the terminal abdominal aorta (1 case): the collateral circle was

TABLE 1 — Total of cases. Note of abbreviations: *b.s.a.* = body surface area; *level o.* = level of obstruction (*C. Iliac* = Common iliac a.; *E. Iliac* = external iliac a.; *S. fem. 1* = superficial femoral a. at its origin; *S. Fem. 2* = superficial femoral a. at distal level; *B. fem.* = superficial and deep femoral as. at their origin; *T. Aorta* = terminal branch of abdominal aorta); *I. W.* = Windsor index.

TABLE 1								
	sex	age	weight	height	level o.	side	I.W.(%)	BSA (m ²)
1	M	65	73	170	E.Iliac	DX	55,4	1,84
2	M	65	55	163	S.fem.1	DX	69	1,58
3	M	65	76	182	S.fem.1	SN	70,6	1,97
4	M	66	78	178	T.Aorta	///	32,2	1,96
5	M	67	64	165	S.fem.2	DX	34	1,70
6	M	68	83	183	B.fem.	DX	23,3	2,05
7	M	68	75	175	S.fem.1	SN	56	1,90
8	M	69	70	175	S.fem.1	DX	70,2	1,85
9	M	71	77	177	S.fem.2	SN	44,3	1,94
10	M	71	75	177	S.fem.1	DX	59	1,92
11	M	73	84	179	S.fem.1	SN	48	2,03
12	M	74	73	173	C.Iliac	SN	23	1,87
13	M	74	69	159	B.fem.	SN	18,5	1,71
14	M	75	75	178	S.fem.1	DX	59	1,93
15	M	77	77	181	S.fem.1	DX	60	1,97
16	M	77	75	173	S.fem.1	SN	44,4	1,89
17	M	77	63	163	E.Iliac	DX	29,3	1,68
18	M	78	78	178	S.fem.1	SN	45	1,96
19	M	78	57	166	S.fem.1	SN	44,3	1,63
20	M	79	58	158	S.fem.1	DX	65	1,58
21	M	79	77	176	S.fem.1	SN	58	1,93
22	M	80	81	174	B.Fem.	DX	36	1,96
23	M	80	92	184	S.fem.2	DX	27,4	2,15
24	F	66	79	172	S.fem.1	SN	39	1,92
25	F	66	75	163	S.fem.1	SN	35	1,81
26	F	67	57	165	E.Iliac	SN	21	1,62
27	F	69	48	157	S.fem.2	DX	24	1,46
28	F	71	66	168	C.Iliac	DX	18,3	1,75
29	F	72	56	164	S.fem.1	SN	69	1,60
30	F	74	54	163	E.Iliac	DX	43	1,57
31	F	74	62	160	S.fem.1	DX	55,3	1,64
32	F	76	59	168	S.fem.2	SN	42	1,67
33	F	76	64	156	S.fem.1	SN	67	1,64
34	F	78	65	167	E.Iliac	SN	34,2	1,73
35	F	79	58	165	S.fem.1	DX	49	1,63
mean		72	72,686	170,1				1,80
sd ±		5	10,327	8,034				0,17



- Fig. A. — Occlusion of terminal branch of abdominal aorta. Collateral circulation. 1: inferior mesenteric a.; 2: ischiatic a.; 3: lumbar, ilio-lumbar and gluteal a.
- Fig. B. — Complete occlusion of iliac tract. Collateral circulation. 1: spermatic or ovarian a.; 2: funicular a.; 3: external pudendal a.; 4: middle sacral a.
- Fig. C. — Occlusion of ilio-femoral tract. Collateral circulation. 1: internal pudendal a.; 2: external pudendal a.; 3: ilio-lumbar a.; 4: obturator a.; 5: gluteal a.; 6: circumflex iliac a.
- Fig. D. — Occlusion of first tract of superficial femoral a. Collateral circulation. 1: perforating aa.
- Fig. E. — Occlusion of terminal tract of superficial femoral a. Collateral circulation. 1: articular branches; 2: great anastomotic a.; 3: recurrent posterior tibialis a.; 4: deep femoral a.
- Fig. F. — Occlusion of superficial and deep femoral as. at their origin. Collateral circulation. 1: ischiatic a.; 2: perforating as.; 3: tegumental as.

mainly established through the inferior mesenteric and ischiatic arteries and through the lumbar, ilio-lumbar and gluteal arteries (*Fig. A*);

— occlusion of the iliac tract (2 cases): the collateral circulation was established through the spermatic or ovaric artery and through the funicular, external pudendal and middle sacral arteries (*Fig. B*);

— occlusion of the ilio-femoral tract (4 cases): the collateral circulation was formed by the internal and external pudendal arteries and by the ilio-lumbar, obturating, gluteal and circumflex iliac arteries (*Fig. C*);

— occlusion of first tract of the superficial femoral artery (17 cases): collateral circulation was established through the deep femoral artery and through the perforating arteries (*Fig. D*);

— occlusion of the terminal tract of the superficial femoral artery (8 cases): collateral circulation was formed by the articular branches of the same artery originating proximal to the occlusion and through the branches of the deep femoral artery (*Fig. E*);

— occlusion of the superficial and deep femoral arteries at their origin (3 cases): collateral circulation was established through the ischiatic artery (directly and, indirectly, through the perforating arteries), and through the tegumenal arteries.

Radiologic and ultrasonic data were not significantly correlated with age, sex, or body surface.

The hemodynamic significance as measured by Windsor index was higher the more proximal was the occlusion, though this trend did not reach statistical significance.

DISCUSSION AND CONCLUSION

With progress of arteriopathy, arterial stenosis or occlusion increases blood flow through high resistance vessels. This causes a reduction of the pulsatory wave and of the average arterial pressure downstream (Carter, 1978).

In our study, the superficial femoral artery was the vessel most often involved in arterial obstruction. The low hemodynamic significance of occlusion at this level can be explained with the connections of this vessel: actually, the deep femoral artery and the circumflex artery can often guarantee an adequate collateral circulation.

On the contrary, because of the low caliber of the vessels involved in the collateral circle, in the three cases with a proximal occlusion (1 occlusion of the terminal aorta and 2 occlusions of the common iliac artery), the hemodynamic compromission was high; the funicular artery was particularly important in the collateral circulation in these cases, connecting the external iliac artery both with the internal iliac artery, through the deferential artery, and with the abdominal aorta, through the internal spermatic artery.

The lower hemodynamic compromise (except for 1 case) in occlusion of the external iliac artery, is due to the higher caliber of the vessels forming the collateral circles and to the high number of connections between them: in fact, the anastomoses between the obturator arteries and the retropubic branches and between the gluteal artery and the ischiatic artery and between the internal pudendal and middle hemorrhoidal, can altogether establish an adequate compensation.

Our results are in agreement with the observation by Lanz and Wachsmuth that occlusions distal to the inguinal ligamentum may have a favourable outcome if an adequate circulation between the ipogastric artery and the iliac circumflex branches of the deep femoral artery is established.

Studying the development of collateral circles and defining their pathways has a great prognostic and therapeutical value, leading to the best choice of time and type of intervention. The pressure index is a valid measure of the hemodynamic significance of a stenosis and allows a measurement of the adequacy of a compensatory circle.

It is well known it is not the time since symptoms of obstruction show up, but rather the anatomical and hemodynamic state of the lower limb that predicts the outcome of a surgical revascularization (Malan e Tattoni, 1963). On the other and, indications for therapeutical intervention have not yet been definitely established (Stipa, 1977). For these reasons, the study of collateral circles in lower limbs arterial obstruction is of great clinical value.

As the choice if the type of prosthesis depends also from the length and caliber of the vessels involved in the collateral circles (Sauvage and Berger, 1974), our further purpose is to increase our study population in the attempt of identifying indications to surgical intervention based on quantity and quality of collateral circles.

Arrived 15/5/96. Accepted 4/6/96.

REFERENCES

- Carter SA. 1978. Role of pressure measurements in vascular disease, in Bernstein EF (ed): *Noninvasive Diagnostic Techniques in Vascular Disease*. CV Mosby Co, St Louis, p. 261.
- Cutler BS, Thompson JE. 1974. The modified bovine arterial graft. *Surgery*, 76: 963.
- Dale AW, Lewis MR. 1976. Further experience with bovine arterial grafts. *Surgery*, 80: 711.
- Johnson WC. 1979. Preliminary experience with PTFE grafts. *Surgery*, 85: 123.
- Malan E, Tattoni G. 1963. Physio and anatomo-pathology of acute ischemia of the extremities. *J Cardiovasc Surg*, 4: 212.
- Mercier R, Vanneuville G. 1968. *Anatomie radiologique de l'aorte abdominale et de ses branches*. L'Expansion scientifique ed, Paris.
- Renard M, Brice M, Borrelli J, Stehin P, Schmitt M. et Masson JP. 1974. Les voies de suppléance des axes artériels ilio-fémoraux (étude radio-anatomique). *C R Ass Anat, Liège*, 58, 162, 649-660.

- Sauvage LR, Berger KE. 1974. Future directions in the development of arterial prostheses for small and medium calibre arteries. *Surg Clin North Am*, 54, 1: 212.
- Salmon M. 1939. Les voies anastomotiques artérielles des membres. Masson et Cie èd, Paris.
- Stipa S. 1977. La chirurgia delle arterie periferiche. Piccin ed, Padova.
- Vollmar J. 1967. Rekonstruktive Chirurgie der Arterien. Stuttgart, Georg Thieme, Verlag.

Address:

Prof. Claudio Catini
Dipartimento di Anatomia Umana Normale
e Istologia
Policlinico di Careggi
50134 Firenze - Italia