

Published 26 June 2009

Cite this as: *BMJ Case Reports* 2009 [doi:10.1136/bcr.04.2009.1810]

Copyright © 2009 by the BMJ Publishing Group Ltd.

## Findings that shed new light on the possible pathogenesis of a disease or an adverse effect

### Complete resolution of primary sclerosing peritonitis ("abdominal cocoon") following long term therapy for *Tropheryma whipplei*: a case report and review of literature

Roberto Tarquini<sup>1</sup>, Stefano Colagrande<sup>2</sup>, Matteo Rosselli<sup>1</sup>, Marco Novelli<sup>1</sup>, Silvia Dolenti<sup>1</sup>, Alice Valoriani<sup>1</sup> and Giacomo Laffi<sup>1</sup>

<sup>1</sup> Department of Internal Medicine, University of Florence, Azienda Ospedaliero-Universitaria Careggi. Viale Morgagni 85, Florence 50134, Italy

<sup>2</sup> Department of Clinical Physiopathology, Section of Radiodiagnostics, University of Florence, Azienda Ospedaliero-Universitaria Careggi. Viale Morgagni 85, Florence 50134, Italy

Correspondence to:

Roberto Tarquini, [rtarquini@unifi.it](mailto:rtarquini@unifi.it)

#### SUMMARY

A 53-year-old man was admitted to our internal medicine unit with intestinal obstruction and signs of systemic inflammatory disease. Clinical history was unremarkable until a few months earlier, when he began suffering from Achilles tendonitis. Diagnostic procedures, including laparotomy, revealed diffuse thickening of the peritoneum resembling sclerosing encapsulating peritonitis. Biopsies showed reactive fibrosis. No known secondary causes were found and surgery was technically not feasible. Clinical conditions worsened daily until, on the basis of the overall spectrum of clinical and radiological findings, Whipple's disease was hypothesised and specific therapy administered, with prompt clinical improvement. Complete disappearance of the cocoon was demonstrated at 1 year clinical/ultrasound/computed tomography follow-up.

---

#### BACKGROUND

Sclerosing encapsulating peritonitis is a rare cause of small bowel obstruction and can be classified as primary or secondary, the latter usually linked to chronic peritoneal dialysis. The primary form, known as abdominal cocoon, was first described by Foo *et al* in 1978.<sup>1</sup> It is characterised by a thick, fibrotic, cocoon-like membrane, partially or totally encasing the small bowel. Clinically, it presents with recurrent episodes of acute or sub-acute small bowel obstruction, weight loss, nausea and anorexia, and occasionally with a palpable abdominal mass.<sup>2</sup> Diagnosis is often made during laparotomy for intestinal obstruction and frequently surgical treatment is mandatory, comprising adhesiolysis and small bowel intubation.<sup>3</sup> Abdominal cocoon is mainly reported in young adolescent females from tropical countries, and its aetiology is still challenging. Some authors believe that subclinical viral peritonitis, gynaecological infections or retrograde menstruation could play a role.<sup>4</sup> Some reports describe an association between abdominal cocoon and infectious disease, in particular tuberculosis.<sup>4</sup> However, this is the first case of primary sclerosing peritonitis associated

with Whipple's disease. The complete recovery after treatment for *Tropheryma whipplei* strongly supports this contention.

## CASE PRESENTATION

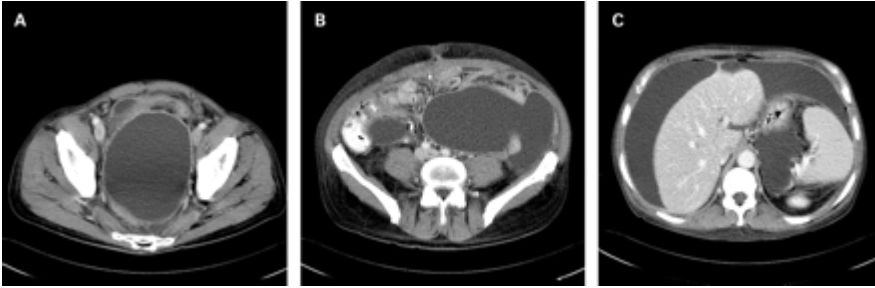
In April 2005 a 53-year-old man was admitted to our internal medicine unit because of intestinal obstruction associated with fever, epigastric pain, nausea and biliary vomit. He was in good health until January 2005 when he began to suffer from bilateral Achilles tendonitis. Laboratory findings showed normocytic anaemia and increased values of inflammatory markers (fibrinogen 654 mg/dl, erythrocyte sedimentation rate (ESR) 78 ml/h, C reactive protein (CRP) 134 mg/l).

## INVESTIGATIONS

The patient's history is extremely complex. For the sake of clarity, the clinical course is described in three steps.

**Initial admission and first investigations.** Abdominal x ray showed proximal small bowel air–fluid levels due to intestinal obstruction. Abdominal computed tomography (CT) scan revealed ascites and deformation of the periduodenal tract of the bowel and of the Treitz ligament associated with thickening of the mesentery and peritoneum. Paracentesis documented exudative ascites together with inflammatory and epitheliomorphic cells. Laparotomy showed conspicuous ascites (6 litres), thickened mesentery and peritoneum as well as dense interbowel adhesions, creases, and pseudonodules. Biopsy specimen examination revealed nodular fibrosis (neoplastic-like) of the mesentery and hyperplastic lymphadenitis without atypical cells. Positron emission tomography (PET) total body scan showed no pathologic areas and the re-evaluation of the biopsy samples confirmed the absence of neoplastic cells. A few days later, paracentesis was repeated and increased values of Ca-125 (790 U/ml) were detected. Cultural examinations of ascites were negative for common bacterial agents and Koch Bacillus (KB), similarly to CRP and microscopic examination. Conversely, a Mantoux intradermic reaction and quantiferon-gold were positive. The patient then underwent an oesophagogastroduodenoscopy (OGD) that showed no alterations of the mucosa; therefore biopsy was not performed. A chest x ray showed a right infiltrate compatible with active pneumonia. Antibiotic treatment with ceftriaxone was empirically given for 3 weeks

**The infectious diseases unit and the "tuberculosis hypothesis".** At that time, hypothesising intestinal tuberculosis, the patient was transferred to the infectious diseases unit (IDU) where he was administered specific therapy for KB comprising in four drugs (rifampin, isoniazide, ethambutol, pyrazinamide). Two weeks later bowel function resumed, ascites decreased, and the patient started eating again. He was therefore discharged with the presumed diagnosis of "tubercular peritonitis" and followed-up by infectious disease specialists. After 2 months, treatment was reduced to two drugs (isoniazide and rifampin). One month later the patient started to feel abdominal tension. Ultrasound showed a relapse of peritoneal effusion. He was re-admitted to the IDU. An abdominal and thoracic CT scan showed limited bilateral pleural effusion, multiple lymphadenopathies of the mesentery, thickening of the peritoneum and fluid levels ([fig 1](#)).<sup>5-8</sup> A new laparotomy confirmed diffused and increased thickening of the peritoneum resembling abdominal cocoon. The biopsy documented reactive fibrosis, without atypical cells.



**Figure 1** Axial contrast enhanced computed tomography (CT) images, acquired in September 2006 (pre-therapy) show diffuse ascites, clustered loops of small bowel (B), retroperitoneal low attenuation lymphadenopathies (B), and diffuse thickening of the mesentery, omentum, and parietal peritoneum (A, B, C).

**From tuberculosis to Whipple’s disease.** Bearing in mind the patient’s clinical course, as well as the results of the latest examinations, Whipple’s disease was hypothesised. Treatment with ceftriaxone and cotrimoxazole was started. Two weeks later, peristalsis slowly normalised together with bowel function, and ascites noticeably decreased. The patient regained appetite and started eating normally.

#### DIFFERENTIAL DIAGNOSIS

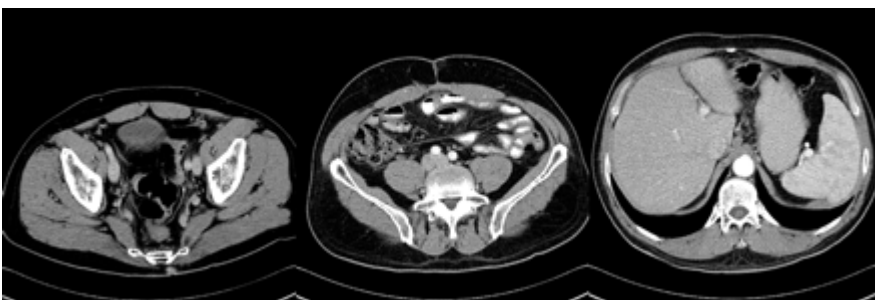Mechanical causes of intestinal obstruction (intussusception, hernia torsion, volvulus), peritoneal carcinosis, mesothelioma of the peritoneum, sarcoidosis, intestinal tuberculosis, atypical infectious diseases.

#### TREATMENT

Ceftriaxone and cotrimoxazole for 12 months.

#### OUTCOME AND FOLLOW-UP

At the time of discharge, bowel function was regular, blood count was almost normal and the patient had gained 6 kg. At 3 and 6 months follow-up, the patient was healthy, with no clinical or ultrasound signs of ascites. An abdominal CT scan performed after 12 months confirmed the absence of ascites and peritoneum thickening ([fig 2](#)).



**Figure 2** Axial contrast enhanced CT images, acquired after 9 months of treatment with cotrimoxazole and ceftriaxone, show complete resolution of ascites and thickening of the peritoneum.

## DISCUSSION

Whipple's disease is a rare systemic infection that may involve any major system. Although potentially fatal, it dramatically responds to antibiotic treatment.<sup>9</sup> To the best of our knowledge, in the indexed literature Whipple's disease complicated by peritoneal involvement is outlined in only one review, but abdominal cocoon is not mentioned.<sup>10</sup> Our diagnosis lacks histologic confirmation; however, it fulfils the criteria based on the surprising clinical response to ceftriaxone and cotrimoxazole confirmed by radiological findings.

Our patient never underwent peritoneal dialysis nor was treated with practolol. Previous symptoms that could indicate recurrent peritonitis<sup>11</sup> were absent. The biopsy of the cocoon was performed twice and on both occasions showed reactive fibrosis excluding carcinosis and mesothelioma of the peritoneum. Sclerosing encapsulating peritonitis has sometimes been associated with intestinal tuberculosis or sarcoidosis.<sup>12</sup> In our case report although quantiferon-gold and Mantoux tests were positive (indicating a previous contact with KB), no evidence of active tuberculosis was detectable in the bioptic specimen. Moreover, despite treatment for KB, ascites and intestinal obstruction relapsed. The recurrence of the disease compelled us to reconsider the whole history, the clinical course, the radiological findings, and the response to our therapeutic strategy. The CT findings drove the diagnosis, in particular the finding of the cluster of jejunal loops in a sack-like membrane with diffuse thickening of the mesentery, omentum, and parietal peritoneum, in combination with low attenuation mesenteric/retroperitoneal adenopathies (fig 1). These features are, in fact, suggestive mainly of either mycobacterial infection or Whipple's disease.<sup>10</sup> However, the association with articular disease (Achilles tendonitis, in this case) and the clinical relapse of intestinal obstruction during tuberculosis treatment would favour the second hypothesis. Moreover, in our opinion, the first clinical improvement was due to ceftriaxone (administered for pneumonia) that is known to be effective against *Tropheryma whipplei*, and not to tuberculosis treatment. Therapy with cotrimoxazole and ceftriaxone was attempted with a prompt clinical response. A new OGD with biopsy of the duodenum was performed and the specimen was sent to the European Centre for Whipple's disease: no foamy period acid-Schiff (PAS) positive macrophages were found and CRP for *T whipplei* was negative. However, this may occur shortly after initiation of antibiotic treatment<sup>13</sup>, thus we assumed that cotrimoxazole and ceftriaxone may have influenced the results.

We are not able to demonstrate how *T whipplei* may have induced peritoneal sclerosis. Nevertheless, as underlined in a recent review, Whipple's disease can be defined as a macrophage disease, and it is well known how these cells play a pivotal role in the cytokine network and production of TGF- $\beta$ .<sup>14</sup> This is speculative and further studies are needed to prove this relation. In our opinion, considering the prompt response to specific therapy in the absence of any other cause of abdominal cocoon, and considering also the CT findings and some of the clinical features, Whipple's disease complicated by abdominal cocoon is a reasonable diagnostic hypothesis. Indeed, the most important follow-up criterion for successful treatment in patients with Whipple's disease is known to be the improvement of clinical symptoms, which should occur in the first 2 weeks after initiation of treatment.<sup>13</sup>

## LEARNING POINTS

- In the case of intestinal obstruction with no apparent cause, Whipple's disease should be considered a possible diagnosis.
- Abdominal cocoon can probably be caused by *Tropheryma whipplei*.
- Specific therapy can lead to complete recovery even at an advanced stage of the disease.

**Competing interests:** none. **Patient consent:** Patient/guardian consent was obtained for publication

## REFERENCES

1. Foo, KT, Ng, KC, Rauff, A, et al. Unusual small intestinal obstruction in adolescent girls: the abdominal cocoon. *Br J Surg* 1978; 65: 427–30.
2. Kawaguchi, Y, Kawanishi, H, Mujais, S, et al. Encapsulating peritoneal sclerosis: definition, etiology, diagnosis, and treatment. International Society for Peritoneal Dialysis Ad Hoc Committee on Ultrafiltration Management in Peritoneal Dialysis. *Perit Dial Int* 2000; 20: S43–55.
3. Deeb, LS, Mourad, FH, El-Zein, YR, et al. Abdominal cocoon in a man: preoperative diagnosis and literature review. *J Clin Gastroenterol* 1998; 26: 148–150.
4. Xu, P, Chen, LH, & Li, YM. Idiopathic sclerosing encapsulating peritonitis (or abdominal cocoon): a report of 5 cases. *World J Gastroenterol* 2007; 13: 3649–51.
5. Qingbing, W, & Dengbin, W. Abdominal Cocoon: multi-detector row CT with multi planar reformation and review of literatures. *Abdominal Imaging* 2008; Epub ahead of print.
6. Jin, H, Ki Wang, K, Mi-Suk, P, et al. Abdominal cocoon: preoperative diagnostic clues from radiologic imaging with pathologic correlation. *AJR Am J Radiol* 2004; 182: 639–41.
7. George, C, Al-Zwae, K, Nair, S, et al. Computed tomography appearances of sclerosing encapsulating peritonitis. *Clin Radiol* 2007; 62: 732–7.
8. Ranganathan, S, Abdullah, BJJ, & Sivanesaratnam, V. Abdominal cocoon syndrome. *J HK Coll Radiol* 2003; 6: 201–3.
9. Lo Monaco, A, Govoni, M, Zelante, et al. Whipple disease: unusual presentation of a protean and sometimes confusing disease. *Semin Arthritis Rheum* 2008; Epub ahead of print.
10. Pickardt, PJ, & Bhalla, S. Unusual nonneoplastic peritoneal and subperitoneal conditions: CT findings. *Radiographics* 2005; 25: 719–30.
11. Atinli, E, Summer, A, & Celik, A. Abdominal cocoon: a rare cause of intestinal obstruction. *Israeli J Emerg Med* 2007; 7: 42–4.
12. Ngo, Yann, Messing, B, Marteau, P, et al. Peritoneal Sarcoidosis: An Unrecognized Cause of Sclerosing Peritonitis. *Dig Dis Sci* 1992; 37: 1776–80.
13. Schneider, T, Moos, V, Laddenkemper, C, et al. Whipple's disease: new aspects of pathogenesis and treatment. *Lancet Infect Dis* 2008; 8: 179–90.
14. Desnues, B, Ihrig, M, Raoult, D, et al. Whipple's disease: a macrophage disease. *Clin Vaccine Immunol* 2006; 13: 170–8.