

## ORIGINAL ARTICLE

# Feasibility of an accurate assessment of myocardial salvage by comparing functional and perfusion abnormalities in post-reperfusion gated SPECT

Roberto Sciagrà, MD,<sup>a</sup> Manjola Dona, MD,<sup>a</sup> Angela Coppola, MD,<sup>b</sup>  
Mario Leoncini, MD,<sup>c</sup> Mauro Maioli, MD,<sup>c</sup> Antonio Castagnoli, MD,<sup>b</sup>  
Francesco Bellandi, MD,<sup>c</sup> and Alberto Pupi, MD<sup>a</sup>

**Background.** Because of persistent stunning, post-treatment functional abnormalities could identify the initial risk area. The study aims to detect myocardial salvage using post-revascularization gated SPECT in acute myocardial infarction (AMI) treated by reperfusion therapy.

**Methods.** In 36 AMI patients, we performed a first gated SPECT injecting <sup>99m</sup>Tc-sestamibi before primary percutaneous coronary intervention (PCI), and a second 5 days later. The salvage index defined by the two perfusion images was compared with the value obtained by subtracting in the second gated SPECT the extent of perfusion defect from the extent of wall thickening abnormalities.

**Results.** The wall thickening salvage index correlated with the reference perfusion salvage index (Spearman's  $\rho = .92, P < .0001$ ), with a 95% limit of agreement =  $\pm .25$ . The agreement between the classifications in salvage index tertiles of the reference and of the wall thickening salvage index was good (kappa = .75). All patients with optimal PCI result and 18/24 of those with intermediate or poor outcome were correctly classified.

**Conclusions.** Comparing function and perfusion in a single post-PCI <sup>99m</sup>Tc-sestamibi gated SPECT it is possible to estimate myocardial salvage. This could have useful implications in studies comparing different treatment strategies for AMI. (J Nucl Cardiol 2010;17:825–30.)

**Key Words:** Myocardial infarction • reperfusion • scintigraphy • stunning

---

**See related editorial, pp. 778–780**

---

## INTRODUCTION

The real success of reperfusion therapy in acute myocardial infarction (AMI) is defined by the amount of salvaged myocardium and this requires assessing both the initial risk area and the ultimate myocardial damage.<sup>1-3</sup> While the latter parameter can be easily evaluated using

From the Nuclear Medicine Unit, Department of Clinical Physiopathology,<sup>a</sup> University of Florence, Florence, Italy; Nuclear Medicine Unit, Department of Diagnostic Imaging,<sup>b</sup> Division of Cardiology,<sup>c</sup> Misericordia e Dolce Hospital, Prato, Italy.

Received for publication Mar 8, 2010; final revision accepted May 6, 2010.

Reprint requests: Roberto Sciagrà, MD, Nuclear Medicine Unit, Department of Clinical Physiopathology, University of Florence, Viale Morgagni 85, 50134 Florence, Italy; [r.sciagra@dfc.unifi.it](mailto:r.sciagra@dfc.unifi.it). 1071-3581/\$34.00

Copyright © 2010 by the American Society of Nuclear Cardiology.  
doi:10.1007/s12350-010-9247-x

various modalities (such as infarct size in perfusion or magnetic resonance imaging), the measurement of the former value is much more difficult, and is therefore frequently omitted or replaced by indirect markers of improvement achieved during treatment.<sup>4-7</sup> However, the assessment of myocardial salvage is of the utmost importance, mainly in studies comparing different therapeutic options for AMI. In particular, various studies have proven the excellent capability of the salvage index (the ratio of the degree of myocardial salvage to the initial perfusion defect) to demonstrate in relatively small patient populations which is the most effective alternative between different AMI treatments, showing a close relationship with the patient outcome.<sup>3,8-12</sup> Therefore, a readily feasible method that made possible a reliable estimate of the initial risk area, and accordingly of the salvage index, would be highly desirable and would have major implications for the planning of clinical trials.

In a patient subgroup of the BRAVE-2 study, we had explored the possibility to estimate the salvaged

myocardium by comparing the extent of regional functional abnormalities (that represent myocardial stunning) and of perfusion defects (that indicate the residual damage) in a perfusion gated single-photon emission computed tomography (SPECT) with  $^{99m}\text{Tc}$ -sestamibi acquired few days after AMI.<sup>13</sup> Although the results appeared promising, that patient population was not representative of the patients currently submitted to primary percutaneous coronary intervention (PCI) for AMI, because included patients only admitted very late after symptom onset and who in part underwent just spontaneous reperfusion. Therefore, we performed the present study to verify the accuracy of our approach in the correct clinical setting of patients treated by primary PCI early after AMI onset.

## METHODS

### Patient Population

We evaluated 36 consecutive patients with first AMI referred to our catheterization laboratory for primary angioplasty within 6 hours of symptoms onset and who received  $^{99m}\text{Tc}$ -sestamibi injection before mechanical recanalization. AMI diagnosis was based on typical chest pain lasting for >30 minutes associated with >1 mV ST segment elevation in at least two contiguous electrocardiographic leads. Exclusion criteria were: (1) history of previous AMI or other heart disease; (2) presence of atrial fibrillation.

### Study Protocol

At admission, all patients received aspirin, heparin, clopidogrel, and abciximab (bolus of .25 mg/kg body weight followed by a continuous infusion of .125 mcg/kg/minutes, up to a maximum of 10 mcg/minutes, for 12 hours). Then, patients were transferred to the catheterization laboratory where  $^{99m}\text{Tc}$ -sestamibi (740 MBq) was injected. Immediately after tracer injection, patients underwent selective coronary angiography and primary PCI. Admission gated SPECT was acquired within 6 hours of tracer injection to assess the initial perfusion defect (=risk area). Subsequently, patients underwent a post-treatment resting gated SPECT at approximately 5 days of index AMI to assess the changes in myocardial perfusion defect and regional function. Finally, resting gated SPECT was repeated at least one month after index infarction to assess the left ventricular ejection fraction evolution. All patients gave informed consent to participate in the study, which was approved by the Ethics Committee of our institutions.

### Coronary Angiography and Mechanical Revascularization

Immediately after diagnostic angiography, PCI was performed using standard material. The detection of TIMI grade 3 coronary flow in the treated vessel with a residual stenosis of <20% was considered successful PCI.<sup>5</sup>

## Gated SPECT

Scintigraphic images were acquired using a dual-head gamma camera (ADAC Vertex, Milpitas, CA) equipped with high-resolution collimators and with a 15% window centered on the 140 keV photopeak of technetium-99m. SPECT was performed in step-and-shoot mode, with 32 projections over a 180° elliptical orbit, matrix size 64 × 64, 45 second/projection, 8-frames/cardiac cycle. The studies were reconstructed using filtered backprojection without attenuation or scatter correction and realigned along the heart axis. The left ventricular ejection fraction was calculated using the QGS program.<sup>14</sup>

## Data Analysis

For perfusion and function analysis, the left ventricular polar map was divided into 17 segments. Regional myocardial perfusion, and wall thickening were assessed visually by one blinded experienced observer (M.D.), unaware of patient's data and image sequence, and they were scored using a 5-point scale (0 = normal, 1 = mildly reduced, 2 = moderately reduced, 3 = severely reduced, 4 = absent uptake),<sup>15</sup> and a 4-point scale (0 = normal, 1 = mildly impaired, 2 = moderately impaired, and 3 = severely impaired thickening), respectively.<sup>16</sup> Previous data indicate a good reproducibility of these visual estimates in our laboratory.<sup>17</sup>

The segments with abnormal scores (scores 2-4 for perfusion and scores 1-3 for wall thickening)<sup>13</sup> were identified and the abnormalities were expressed as percent extent of the polar maps. Therefore, the extent of any abnormality (perfusion or wall thickening) was:

$$\frac{\text{number of abnormal segments}}{17} \times 100$$

The salvaged myocardium was the difference between the admission (=risk area) and the post-treatment perfusion abnormality extent. The salvaged myocardium divided by the initial risk area defined the salvage index. The reference perfusion salvage index was compared with the wall thickening salvage index. The wall thickening salvage index was: extent of wall thickening abnormalities in post-treatment gated SPECT minus perfusion defect extent in post-treatment gated SPECT divided by extent of wall thickening anomalies in post-treatment gated SPECT.<sup>13</sup>

## Statistical Analysis

Continuous variables are expressed as mean ± standard deviation or as median (25th to 75th percentile range), as appropriate. The comparisons within groups were performed with the Student *t* test for dependent samples or the Wilcoxon matched-pairs signed-rank test, as appropriate. The correlation between variables was assessed using the Spearman's  $\rho$ . The agreement between the different methods in establishing the salvage index was assessed using the Bland-Altman analysis and the kappa statistics. Linear regression analysis was used to check the influence of the delay in post-treatment gated

SPECT on the relationship between perfusion and wall thickening salvage indexes and to establish the predictive value of the salvage indexes for left ventricular ejection fraction evolution. A  $P$  value  $<.05$  was considered statistically significant.

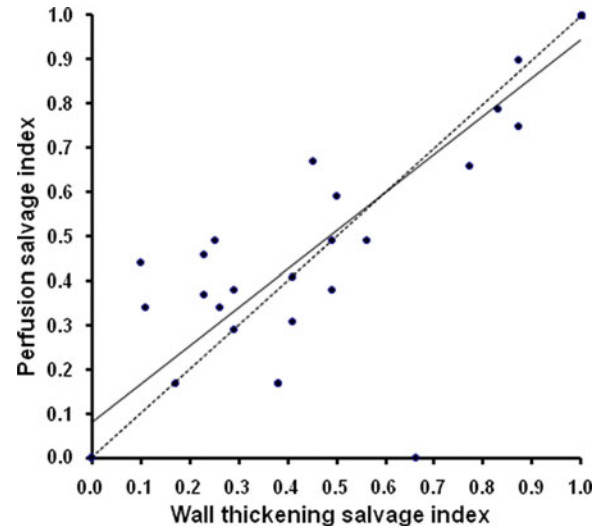
## RESULTS

The patient population included 28 men and 8 women. No patient had history of prior PCI and/or coronary artery bypass grafting. As regards the infarct location, 17 patients had anterior, 13 inferior, and 6 lateral infarction. Table 1 summarizes the main characteristics of the patient population.

At admission, the extent of perfusion abnormalities was 35% (24% to 47%). The post-treatment extent of perfusion abnormalities was 15% (0% to 29%) ( $P < .0001$  vs admission). In the admission gated SPECT the extent of wall thickening abnormalities was 47% (29% to 69.5%) and in the post-treatment scan was 35% (24% to 41%) ( $P < .001$  vs admission). This extent value was not significantly different from the admission extent of perfusion abnormalities. Moreover, there was a significant correlation between post-treatment extent of wall thickening abnormalities and admission extent of abnormal perfusion (Spearman's  $\rho = .78$ ,  $P < .0001$ ).

**Table 1.** Clinical characteristics of the patient population

Age (years, mean $\pm$ SD)	63.6 $\pm$ 10
Risk factors	
Systemic arterial hypertension, n (%)	13 (36%)
Hypercholesterolemia (total cholesterol $>200$ mg/dL), n (%)	16 (44%)
Diabetes mellitus, n (%)	7 (19%)
Smoking, n (%)	19 (53%)
Prior coronary artery by-pass grafting	0
Prior percutaneous coronary intervention	0
Infarct related artery	
Left anterior descending artery, n (%)	18 (50%)
Left circumflex artery, n (%)	4 (12%)
Right coronary artery, n (%)	14 (38%)
TIMI flow grade before PCI, median (25th-75th percentile)	0 (0-1)
TIMI flow grade after PCI, median (25th-75th percentile)	3 (3-3)
Symptoms to PCI delay, minutes (mean $\pm$ SD)	205 $\pm$ 93
Peak CK, U/L (mean $\pm$ SD)	2704 $\pm$ 2130
Delay of post-treatment gated SPECT, days, median (25th-75th percentile)	5 (4-6)

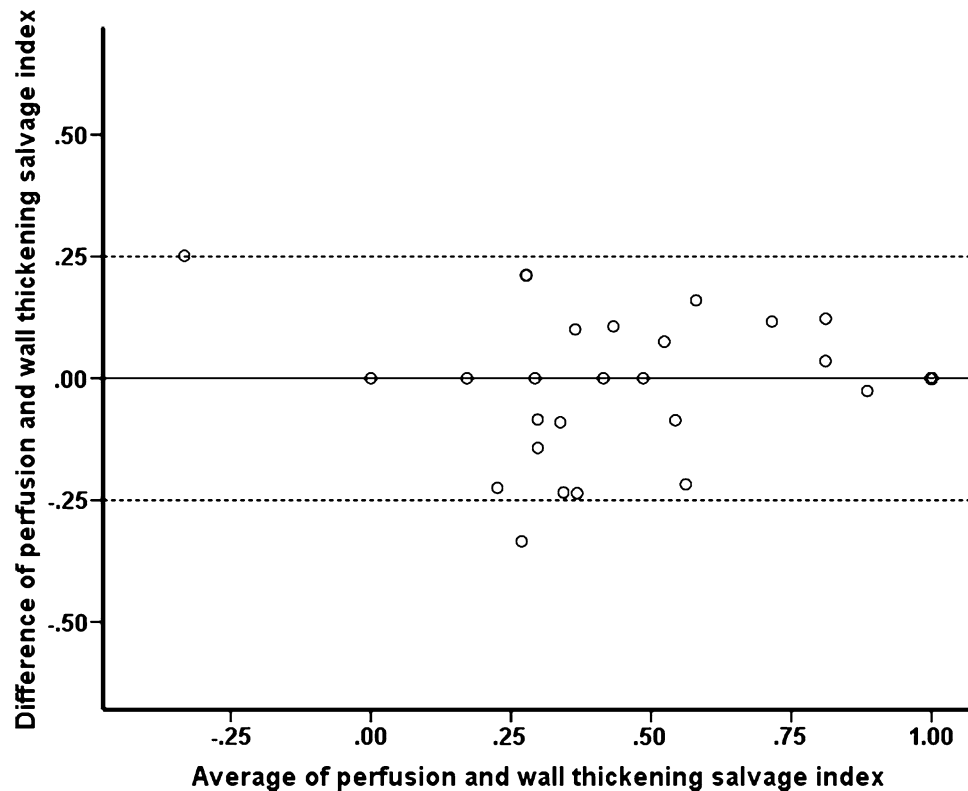


**Figure 1.** Correlation of wall thickening salvage index ( $x$  axis) vs perfusion salvage index ( $y$  axis). The dashed line represents the line of identity.

The salvage index derived from percent extent of perfusion defects was .49 (.26 to 1). The wall thickening salvage index was .49 (.34 to 1) (NS vs perfusion salvage index) and there was a close correlation between the two values: Spearman's  $\rho = .92$  ( $P < .0001$ ) (Figure 1). As shown in Figure 2, the Bland-Altman analysis demonstrates that the 95% limit of agreement between perfusion and wall thickening salvage indexes is  $\pm .25$ . According to univariate regression analysis with wall thickening salvage index as dependent variable, the delay of post-treatment gated SPECT included as covariate did not influence the relationship between the perfusion and the wall thickening salvage indexes (perfusion salvage index  $F = 102.6$ ,  $P < .0001$ , post-treatment gated SPECT delay  $F = .002$ ,  $P = .97$ , model  $R^2 = .98$ ).

We compared the classification in salvage index tertiles of the reference perfusion salvage index and of the wall thickening salvage index. The agreement between the classifications was very good, with kappa = .75. In particular, all patients having a good result according to the reference perfusion salvage index were correctly classified by the wall thickening salvage index. Among the patients with intermediate or poor results according to reference perfusion salvage index, one-fourth only (6/24) was misclassified by the wall thickening salvage index, but the difference was always of one grade only and was evenly distributed between upgrading (3 cases) and underrating (3 cases).

In the one-month gated SPECT there was a left ventricular ejection fraction increase as compared to the admission value (51.9  $\pm$  12.7% vs 38.6  $\pm$  10.5%,  $P < .0001$ ). According to linear regression analysis both the perfusion salvage index and the wall thickening



**Figure 2.** Bland-Altman plot of agreement between the perfusion salvage index and the wall thickening salvage index; the *dashed lines* represent the 95% limits of agreement.

salvage index were significant univariate predictors of the left ventricular ejection fraction evolution: perfusion salvage index  $F = 2.6$ ,  $P < .05$ , model  $R^2 = .45$ , and wall thickening salvage index  $F = 3.6$ ,  $P < .01$ , model  $R^2 = .61$ , respectively.

## DISCUSSION

The present study confirms the findings of our previous report in which we suggested that the extent of the asynergic area in a delayed pre-discharge gated SPECT could still be representative of the size of myocardium at risk before reperfusion, according to the model of myocardial stunning.<sup>13,18</sup> The present results show that with the wall thickening salvage index it is possible to obtain a clinically acceptable estimate for the true salvage index (with a 95% limit of agreement of  $\pm .25$  for a parameter ranging from 0 to 1), and a patient classification in terms of good, intermediate, or poor reperfusion success that is in good agreement with the reference categorization (30/36 patient correctly classified). In agreement with prior reports on larger patient populations,<sup>19</sup> the perfusion salvage index predicts with good accuracy the late left ventricular ejection fraction evolution in the study cohort, and the wall thickening salvage index appears to be equally effective in this

regard. These results have been obtained in a patient population that is representative of the current candidates to primary PCI, including patients who were all treated within 6 hours of symptom onset. Moreover, differently from our previous report, we achieved these results using the presently recommended 17-segment model for polar map evaluation.

We performed the post-treatment acquisition around 5 days after AMI. Myocardial stunning is a time-dependent phenomenon and echocardiographic data demonstrate that the first partial signs of regional functional recovery can be registered within 48 hours of AMI.<sup>20</sup> For that reason, an early acquisition would increase the extent of detectable stunning. On the other hand, another study by the same group indicates that an acquisition at 18-48 hours could overestimate the infarct size as compared to a pre-discharge scan (i.e., at 6 to 14 days of AMI).<sup>21</sup> Therefore, it is difficult to define the optimal timing for gated SPECT. Our results were achieved with a median delay that is intermediate between the two above-mentioned time points. The perfusion salvage index shows median value and inter-quartile range that are comparable with those reported in larger patient population using a longer delay (7 to 14 days).<sup>3,8-10</sup> The same is true for the wall thickening salvage index. Moreover, within our time range (2 to

8 days), the post-treatment gated SPECT delay has no influence on the relationship between perfusion and wall thickening salvage indexes. These results would support the proposition that gated SPECT should be acquired few days after reperfusion (possibly later than 48 hours and within one week of index infarction), taking into account the patient's clinical status.

Our findings are valuable because confirm the possibility to assess the salvage index after primary PCI using a single gated SPECT performed in the first days after reperfusion. This is important in the single patient's evaluation, because it allows identifying the initial area at risk, a parameter that is otherwise very difficult to define without the complicated logistics of a radionuclide tracer injection before acute coronary intervention.<sup>22</sup> However, the possibility to classify the reperfusion results not just in terms of residual damage, but in terms of actual myocardial salvage is far more essential for comparative studies about different therapeutic strategies for AMI, because it could potentially reduce the sample size needed to recognize the treatment effectiveness. Presently, the use of infarct size as surrogate end-point does not allow directly differentiating a small infarction obtained by extensive myocardial salvage from an initially limited risk area without major treatment effects. On the other hand, the adjunct of indirect indicators of reperfusion success that may partly overcome the infarct size limitations requires more complex protocols and introduces additional sources or errors. Although there are no doubts that alternative imaging modalities could be helpful, at present the wide availability and extensive experience of perfusion gated SPECT represent a clear advantage of our proposed approach.<sup>23-25</sup>

Some limitations of the present study must be considered. The patient population is small, as in most studies that require pre-reperfusion tracer injection. There were no patients with prior infarction and it is reasonable to assume that in those patients the reliability of our approach (as that of the infarct size measurement) would be poor because of the possible interference of the asynergic area caused by the old necrosis. The criteria used to compare perfusion and functional data by translating the related scores in extent of abnormalities on the polar maps remain arbitrary. However, the good results obtained in a different patient population reinforce their reliability. It is reasonable to assume that the automatic definition of abnormalities in percent of left ventricle that is offered by various processing algorithms for gated SPECT could improve the reliability and reproducibility of our method. Finally, this approach is based on the detection of prolonged stunning, and therefore might be less reliable in small infarctions, where tethering from adjacent normal tissue could interfere with the recognition of wall motion abnormalities.

In conclusion, this study confirms that by comparing the extent of wall thickening and perfusion abnormalities in a single post-treatment gated SPECT it is possible to easily achieve a reliable assessment of the salvage index in AMI patients treated by primary PCI.

## References

1. Gibbons MK, Mahmarian JJ, Chesebro JH, Wackers FJ. Feasibility of tomographic <sup>99m</sup>Tc-hexakis-2-methoxy-2-methylpropyl-isonitrile imaging for the assessment of myocardial area at risk and the effect of treatment in acute myocardial infarction. *Circulation* 1989;80:1277-85.
2. Santoro GM, Bisi G, Sciagrà R, Leoncini M, Fazzini PF, Meldolesi U. Single photon emission tomography with technetium-99m hexakis 2-methoxyisobutyl isonitrile in acute myocardial infarction before and after thrombolytic treatment: Assessment of salvaged myocardium and prediction of late functional recovery. *J Am Coll Cardiol* 1990;150:301-14.
3. Schömig A, Kastrati A, Dirschinger J, Mehilli J, Schricke U, Pache J, et al. Coronary stenting plus platelet glycoprotein IIb/IIIa blockade compared with tissue plasminogen activator in acute myocardial infarction. Stent versus Thrombolysis for Occluded Coronary Arteries in Patients with Acute Myocardial Infarction Study Investigators. *N Engl J Med* 2000;343:385-91.
4. Santoro GM, Antoniucci D, Valenti R, Bolognese L, Buonamici P, Trapani M, et al. Rapid reduction of ST-segment elevation after successful direct angioplasty in acute myocardial infarction. *Am J Cardiol* 1997;80:685-9.
5. Poli A, Fetiveau R, Vandoni P, del Rosso G, D'Urbano M, Seveso G, et al. Integrated analysis of myocardial blush and ST-segment elevation recovery after successful primary angioplasty. Real-time grading of microvascular reperfusion and prediction of early and late recovery of left ventricular function. *Circulation* 2002;106:313-8.
6. van't Hof AW, Liem A, Suryapranata H, Hoorntje JC, de Boer MJ, Zijlstra F. Angiographic assessment of myocardial reperfusion in patients treated with primary angioplasty for acute myocardial infarction: Myocardial blush grade. Zwolle Myocardial Infarction Study Group. *Circulation* 1998;97:2302-6.
7. Gibbons RJ, Miller TD, Christian TF. Infarct size measured by single photon emission computed tomographic imaging with (<sup>99m</sup>Tc)-sestamibi: A measure of the efficacy of therapy in acute myocardial infarction. *Circulation* 2000;101:101-8.
8. Kastrati A, Mehilli J, Dirschinger J, Schricke U, Neverve J, Pache J, et al. Stent versus Thrombolysis for Occluded Coronary Arteries in Patients With Acute Myocardial Infarction (STOPAMI-2) Study. Myocardial salvage after coronary stenting plus abciximab versus fibrinolysis plus abciximab in patients with acute myocardial infarction: A randomised trial. *Lancet* 2002;359:920-5.
9. Kastrati A, Mehilli J, Nekolla S, Bollwein H, Martinoff S, Pache J. STOPAMI-3 Study Investigators. A randomized trial comparing myocardial salvage achieved by coronary stenting versus balloon angioplasty in patients with acute myocardial infarction considered ineligible for reperfusion therapy. *J Am Coll Cardiol* 2004;43:734-41.
10. Ndrepepa G, Mehilli J, Schwaiger M, Schühlen H, Nekolla S, Martinoff S, et al. Prognostic value of myocardial salvage achieved by reperfusion therapy in patients with acute myocardial infarction. *J Nucl Med* 2004;45:725-9.
11. Parodi G, Ndrepepa G, Kastrati A, Conti A, Mehilli J, Sciagrà R, et al. Beyond 12 hours Reperfusion Alternative Evaluation

- (BRAVE-2) Trial Investigators. Ability of mechanical reperfusion to salvage myocardium in patients with acute myocardial infarction presenting beyond 12 hours after onset of symptoms. *Am Heart J* 2006;152:1133-9.
12. Busk M, Kaltoft A, Nielsen SS, Bøttcher M, Rehling M, Thuesen L, et al. Infarct size and myocardial salvage after primary angioplasty in patients presenting with symptoms for <12 h vs. 12-72 h. *Eur Heart J* 2009;30:1322-30.
  13. Sotgia B, Sciagrà R, Parodi G, Kastrati A, Antonucci D, Schömig A, et al. Estimate of myocardial salvage in late presentation acute myocardial infarction by comparing functional and perfusion abnormalities in predischARGE gated SPECT. *Eur J Nucl Med Mol Imaging* 2008;35:906-11.
  14. Germano G, Kiat H, Kavanagh PB, Moriel M, Mazzanti M, Su HT, et al. Automatic quantification of ejection fraction from gated myocardial perfusion SPECT. *J Nucl Med* 1995;36:2138-47.
  15. Sharir T, Germano G, Waechter PB, Kavanagh PB, Areeda JS, Gerlach J, et al. A new algorithm for the quantitation of myocardial perfusion SPECT. II: Validation and diagnostic yield. *J Nucl Med* 2000;41:720-7.
  16. Germano G, Erel J, Lewin H, Kavanagh PB, Berman DS. Automatic quantitation of regional myocardial wall motion and thickening from gated technetium-99m sestamibi myocardial perfusion single-photon emission computed tomography. *J Am Coll Cardiol* 1997;30:1360-7.
  17. Leoncini M, Marcucci G, Sciagrà R, Frascarelli F, Traini AM, Mondanelli D, et al. Nitrate-enhanced gated technetium 99m sestamibi SPECT for evaluating regional wall motion at baseline and during low-dose dobutamine infusion in patients with chronic coronary artery disease and left ventricular dysfunction: Comparison with two-dimensional echocardiography. *J Nucl Cardiol* 2000;7:426-31.
  18. Braunwald E, Kloner RA. The stunned myocardium: Prolonged, postischemic ventricular dysfunction. *Circulation* 1982;66:1146-9.
  19. Ndrepepa G, Mehilli J, Martinoff S, Schwaiger M, Schömig A, Kastrati A. Evolution of left ventricular ejection fraction and its relationship to infarct size after acute myocardial infarction. *J Am Coll Cardiol* 2007;50:149-56.
  20. Oh JK, Gibbons RJ, Christian TF, Gersh BJ, Click RL, Sitthisook S, et al. Correlation of regional wall motion abnormalities detected by two-dimensional echocardiography with perfusion defect determined by technetium 99m sestamibi imaging in patients treated with reperfusion therapy during acute myocardial infarction. *Am Heart J* 1996;131:32-7.
  21. Pellikka PA, Behrenbeck T, Verani MS, Mahmarian JJ, Wackers FJT, Gibbons RJ. Serial changes in myocardial perfusion using tomographic technetium 99m-hexakis-2-methoxy-2-methylpropylisotrile imaging following reperfusion therapy of myocardial infarction. *J Nucl Med* 1990;31:1269-75.
  22. Pennell D. Myocardial salvage: Retrospection, resolution, and radio waves. *Circulation* 2006;113:1821-3.
  23. Sciagrà R, Leoncini M. Gated single-photon emission computed tomography. The present-day "one-stop-shop" for cardiac imaging. *Q J Nucl Med Mol Imaging* 2005;49:19-29.
  24. Main ML, Magalski A, Chee NK, Coen MM, Skolnick DG, Good TH. Full-motion pulse inversion power Doppler contrast echocardiography differentiates stunning from necrosis and predicts recovery of left ventricular function after acute myocardial infarction. *J Am Coll Cardiol* 2001;38:1390-4.
  25. Aletas AH, Tilak GS, Natanzon A, Hsu LY, Gonzalez FM, Hoyt RF Jr, et al. Retrospective determination of the area at risk for reperfused acute myocardial infarction with T2-weighted cardiac magnetic resonance imaging: Histopathological and displacement encoding with stimulated echoes (DENSE) functional validations. *Circulation* 2006;113:1865-70.