

Original Article

Transverse Dentoskeletal Features of Anterior Open Bite in the Mixed Dentition

A Morphometric Study on Posteroanterior Films

Fabiana Ballanti^a; Lorenzo Franchi^b; Paola Cozza^c

ABSTRACT

Objective: To apply both conventional cephalometric analysis and morphometric analysis (thin-plate spline analysis) to posteroanterior (PA) cephalograms to test the hypothesis that the dentoskeletal features of subjects with anterior open bite in the mixed dentition are no different from those of normal controls.

Materials and Methods: A group of 22 white subjects (6 males, 16 females; mean age, 8.7 ± 0.7 years) with anterior open bite (AOBG) was compared with a control group (CG) of 22 white subjects (11 males, 11 females; mean age, 9.2 ± 0.8 years) with Class I occlusal relationships, and without anterior open bite and sucking habits. Subjects of both groups were in the mixed dentition and had no history of orthodontic treatment. Between-group statistical comparisons were performed with independent sample *t*-tests and permutation tests.

Results: AOBG exhibited statistically significant shape differences with respect to CG that consisted of a transverse contraction of the zygomatic region, of the maxilla (at both skeletal and dentoalveolar levels), and of the mandible (in both condylar and gonial regions), with a downward dislocation of point menton. With conventional cephalometrics, AOBG showed a statistically significant transverse deficiency in the zygomatic region (-4.8 mm), in the maxilla at both skeletal and dentoalveolar levels (-2.0 mm and -3.0 mm, respectively), and in the mandible in both condylar and gonial regions (-3.6 mm and -4.0 mm, respectively).

Conclusion: Subjects with anterior open bite showed transverse deficiencies in the zygomatic region, in the maxilla, and in the mandible when compared with normal subjects. (*Angle Orthod.* 2009;79:615–620.)

KEY WORDS: Anterior open bite; Posteroanterior cephalometrics; Thin-plate spline analysis

INTRODUCTION

Anterior open bite is a complex clinical entity that entails a combination of different 3-dimensional dental and skeletal components. Traditionally, occlusal and craniofacial characteristics of growing subjects with

anterior open bite have been studied in the sagittal and vertical planes^{1–3} with conventional cephalometric analysis on lateral cephalograms. A consensus has been reached on selected dentoskeletal features associated with anterior open bite, such as increases in mandibular plane angle, gonial angle, y-axis, and lower anterior facial height, and a decrease in the interincisal angle.^{4–9} As for the relationship of the palatal plane to the cranial base, Subtelny and Sakuda⁶ found that the palatal plane angle was normal in anterior open bite cases; other authors^{4,9} reported a decrease in the palatal plane angle. Posterior facial height is also controversial. A few studies^{6,9} reported no differences between anterior open bite and control subjects, while others² showed a significant decrease in posterior facial height in anterior open bite cases. Nahoum⁴ and Cangialosi² found that the ratio of upper facial height to total facial height was smaller for subjects

^a Private Practice, Rome, Italy.

^b Assistant Professor, Department of Orthodontics, University of Florence, Florence, Italy; Thomas M. Graber Visiting Scholar, Department of Orthodontics and Pediatric Dentistry, School of Dentistry, The University of Michigan, Ann Arbor.

^c Professor and Head, Department of Orthodontics, University of Rome “Tor Vergata,” Rome, Italy.

Corresponding author: Dr Lorenzo Franchi, Department of Orthodontics, University of Florence, Via del Ponte di Mezzo, 46-48, Florence, Italy 50127
(e-mail: lorenzo.franchi@unifi.it)

Accepted: October 2008. Submitted: July 2008.

© 2009 by The EH Angle Education and Research Foundation, Inc.

with anterior open bite, and that this ratio remained relatively constant with age.

To our knowledge, no data are available in the literature on the transverse dentoskeletal characteristics of subjects with anterior open bite in the mixed dentition. Toutountzakis and Haralabakis¹⁰ analyzed the posteroanterior cephalograms of adult subjects with anterior open bite as related to normal subjects. They found that nasal height and lower facial height were significantly increased in both males and females of the anterior open bite group. No significant differences were found in zygomatic, maxillary, nasal, or mandibular width.

Conventional cephalometrics based on linear and angular measurements has shown, however, an increasing number of limitations,¹¹ along with the proposal and implementation of new biometric analyses of landmark data (eg, elliptic Fourier analysis, finite element analysis, tensor and shape coordinate analysis).¹²⁻¹⁶

A recent morphometric approach to the comparison of configurations of landmarks in 2 or more specimens is known as thin-plate spline (TPS) analysis, as developed by Bookstein.¹⁷ TPS analysis enables the construction of transformation grids that capture the differences in shape and are available for visual interpretation. For a more detailed review of theoretical base, calculation procedures, and assumptions and limitations of TPS morphometrics, see Bookstein,^{17,18} Rohlf and Marcus,¹⁹ and Dryden and Mardia.²⁰ In recent times, TPS analysis has become increasingly important in orthodontics as a means of investigating modifications in shape related to facial growth and treatment.²¹⁻²⁴

The aim of the present study was to evaluate the dentoskeletal features of subjects with anterior open bite in the mixed dentition using both conventional cephalometric analysis and morphometric analysis (TPS analysis) applied to posteroanterior (PA) films.

SUBJECTS AND METHODS

The anterior open bite group (AOBG) consisted of 22 white subjects (6 males, 16 females; mean age, 8.7 ± 0.7 years; age range, 7.9–10.3 years) selected from the files of the Department of Orthodontics of the University of Rome "Tor Vergata." Subjects were selected on the basis of the following inclusionary criteria: anterior open bite (presence of 1 mm or greater anterior open bite), intermediate (permanent incisors and first molars fully erupted, deciduous teeth in the buccal region—canine, first molar, and second molar) or late (canines or premolars erupting) mixed dentitions,²⁵ Class I occlusal relationships, and posteroanterior and lateral cephalograms of good quality. At clinical ex-

amination, all subjects in AOBG showed an atypical pattern of swallowing (tongue thrust). Posterior crossbite and a variable degree of crowding in the upper arch were present in 16 of 22 subjects (73%). Anamnestic records showed that subjects in AOBG had shown prolonged sucking habits (27%) or mouth breathing (36%). Sucking habits had ceased by the time of clinical evaluation.

The control group (CG) consisted of 22 white subjects (11 males, 11 females; mean age, 9.2 ± 0.8 years; age range, 7.7–10.6 years) from the same University in the intermediate or late mixed dentitions with Class I occlusal relationships, and without anterior open bite, crossbite, and crowding. All 22 controls had no experience or presence of oral habits.

Subjects from both groups did not show missing teeth (due to aplasia, trauma, or deep caries), had no history of orthodontic treatment, and did not present with craniofacial syndromes. On the lateral cephalograms, sagittal (ANB angle) and vertical skeletal relationships (mandibular plane angle, FMA) were assessed in both AOBG and CG.²⁶

All posteroanterior cephalograms were taken with the Frankfort plane parallel to the floor, and with the head front and the nose tip in contact with the radiographic cassette. PA cephalograms were hand-traced with a 0.5 mm lead on 0.003 mm matte acetate tracing paper. All tracings were performed by a single investigator and subsequently were verified by another investigator. To analyze the combined error of landmark location and digitization, 25 randomly selected PA cephalograms were retraced and redigitized. The standard error deviation for each dimension was calculated from double determinations using Dahlberg's formula.²⁷ The mean value for the method error was 0.55 ± 0.23 mm.

Traced PA cephalograms were analyzed with a digitizing tablet (Numonics, Lansdale, Pa) and Viewbox digitizing software (version 2.6; dHAL Software, Kifisia, Greece). All cephalograms were converted to a 10% enlargement to standardize the magnification data.

Conventional Cephalometric Analysis

Figure 1 illustrates the bilateral cephalometric landmarks and measurements used in this part of the study.

Skeletal landmarks.

Euryon (Eu): the most lateral point of the cranial vault
Medio-orbitale (Mo): the most medial point of the orbital orifice

Latero-orbitale (Lo): the intersection of the lateral wall

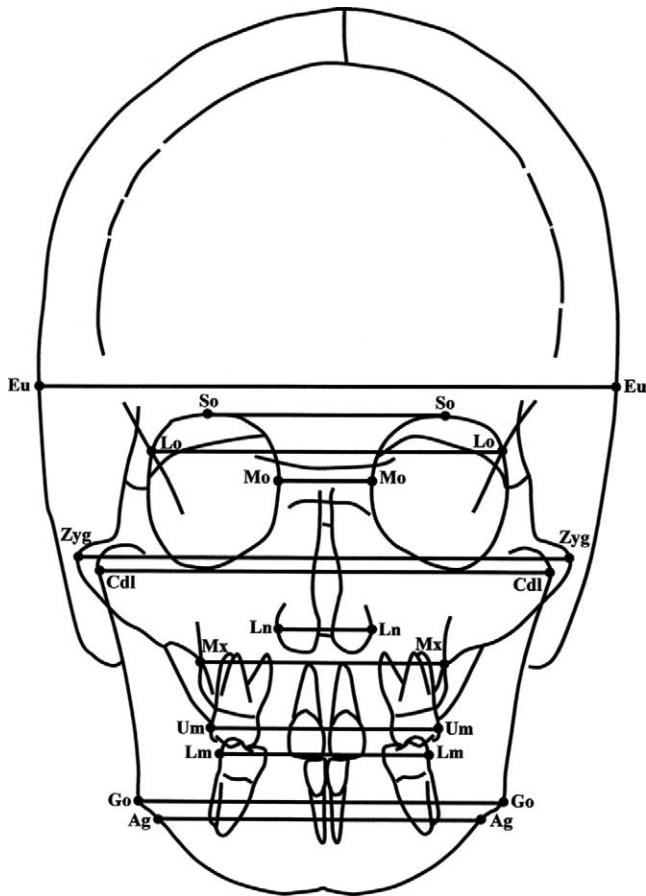


Figure 1. Cephalometric landmarks and measurements for conventional analysis.

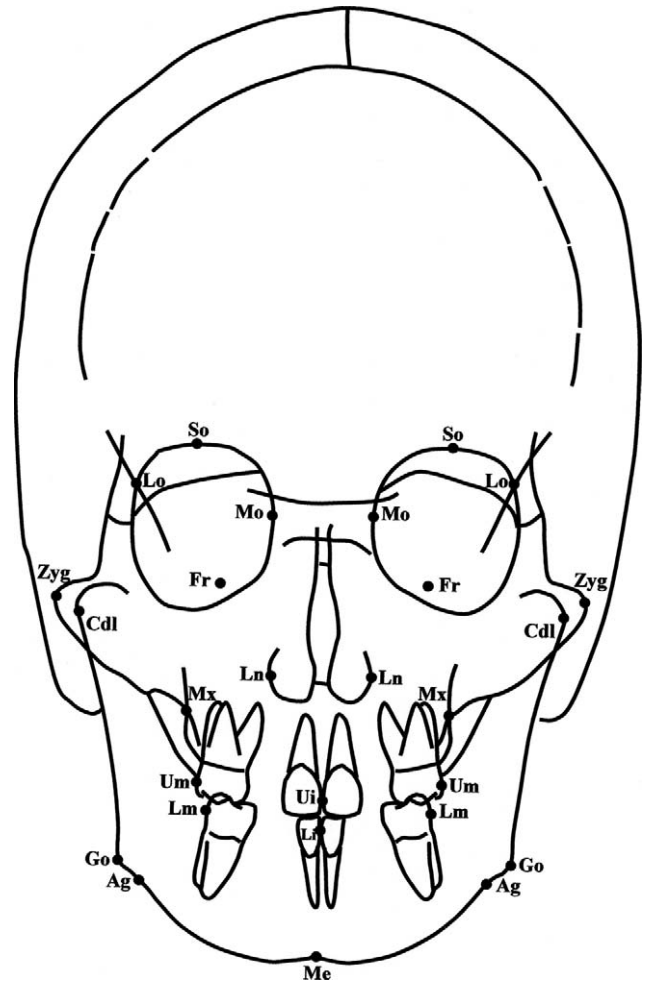


Figure 2. Cephalometric landmarks for thin-plate spline analysis.

- of the orbit and the greater wing of the sphenoid (the oblique line)
- Supraorbitale (So): the most superior point of the orbital orifice
- Zygomatic (Zyg): the most lateral point of the zygomatic arch
- Condylar lateral (Cdl): the point located at the lateral pole of the condylar head
- Maxillare (Mx): the point located at the depth of the concavity of the lateral maxillary contour, at the junction of the maxilla and the zygomatic buttress
- Lateronasal (Ln): the most lateral point of the nasal cavity
- Gonion (Go): the point located at the gonial angle of the mandible
- Antegonion (Ag): the point located at the antegonial notch

Dental landmarks.

- Upper molar (Um): the most prominent lateral point on the buccal surface of the upper first molar
- Lower molar (Lm): the most prominent lateral point on the buccal surface of the lower first molar

From the digitized PA cephalograms, 12 width measurements (10 skeletal and 2 dental) were derived for each patient by connecting bilateral cephalometric landmarks.

Thin-Plate Spline Analysis

In the present study, TPS software²⁸ was used to compute the orthogonal least-squares Procrustes average configuration of landmarks, both in the test and in the control group. When this method is used, each object's coordinates are translated, rotated, and scaled iteratively until the least-squared fit of all configurations cannot be further improved.²⁹ Therefore, all configurations are scaled to an equivalent size (centroid size = 1) and are registered with respect to one another. Additional landmarks with respect to the conventional analysis included the following (Figure 2):

- Foramen rotundum (Fr): the foramen rotundum of the sphenoid bone
- Menton (Me): the central point on the lower border of the mandibular symphysis

Upper interincisal point (Ui): contact point between the upper incisors

Lower interincisal point (Li): contact point between the lower incisors

The morphometric analysis did not include point Euryon. Average craniofacial configurations were subjected to TPS analysis to compare differences in shape between AOBG and CG.

Statistical Analysis

As for conventional cephalometric analysis, statistical comparisons between AOBG and CG were performed by means of an independent sample *t*-test (SigmaStat 3.5, Systat Software Inc., Point Richmond, Calif, USA), after the presence of normal distribution (Kolmogorov-Smirnov test) and equality of variance (Levene median test) was checked for all variables. In TPS analysis, statistical evaluation of shape differences was performed by means of permutation tests, with 1000 random permutations on Wilks' lambda statistics.²⁸

RESULTS

The anteroposterior jaw relationship in AOBG was 36% Class I (1 degree < ANB < 5 degrees), 57% Class II (ANB > 5 degrees), and 7% Class III (ANB < 1 degree); in the control group, it was 50% Class I, 45% Class II, and 5% Class III. No statistically significant difference (z test on proportions) was found between the 2 groups in terms of prevalence rate of skeletal Classes I, II, and III (skeletal Class I: $z = 0.633$, $P = .526$; skeletal Class II: $z = 0.495$, $P = .621$; skeletal Class III: $z = -0.355$, $P = .722$).

The vertical jaw relationship in AOBG revealed 36% normodivergent subjects (22 degrees < FMA < 28 degrees), 57% hyperdivergent subjects (FMA > 28 degrees), and 7% hypodivergent subjects (FMA < 22 degrees); the control group included 67% normodivergent subjects, 23% hyperdivergent subjects, and 10% hypodivergent subjects. A significantly greater prevalence rate of hyperdivergent subjects was found in AOBG ($z = 1.994$, $P = .046$), although no significant difference was found between AOBG and CG in terms of the prevalence rate of normodivergent and hypodivergent subjects (normodivergent: $z = 1.756$, $P = .079$; hypodivergent: $z = -0.184$, $P = .854$).

The AOBG showed a statistically significant reduction in zygomatic width (Zyg-Zyg: -4.8 mm) and in condylar lateral width (Cdl-Cdl: -3.6 mm) when compared with CG (Table 1). Maxillary width, at both skeletal and dentoalveolar levels, was significantly smaller in the AOBG when compared with the CG group (Mx-Mx: -2.0 mm; Um-Um: -3.0 mm). The AOBG showed a statistically significant reduction in gonial width (-4.0

Table 1. Descriptive Statistics and Comparisons Between the Anterior Open Bite Group and the Control Group

Measurements	Anterior Open Bite Group (N = 22)		Control Group (N = 22)		Diff.	<i>t</i> -Test (P Value)
	Mean	SD	Mean	SD		
Eu-Eu, mm	134.8	8.6	137.9	5.7	-3.1	.159
So-So, mm	53.2	3.6	52.2	3	1	.328
Lo-Lo, mm	81.1	4.4	82	4.7	-0.9	.533
Mo-Mo, mm	21.1	2.7	20.2	2.8	0.9	.298
Zyg-Zyg, mm	108.7	7.2	113.5	6.3	-4.8	.023*
Cdl-Cdl, mm	97.5	5.3	101.1	4.9	-3.6	.023*
Ln-Ln, mm	24.3	2.1	25.5	1.8	-1.2	.054
Mx-Mx, mm	53.3	2.6	55.3	3.1	-2	.029*
Um-Um, mm	51.4	2.5	54.4	2.9	-3	<.001**
Lm-Lm, mm	52.4	3.2	53.1	3.3	-0.7	.451
Go-Go, mm	78.8	4.9	82.8	5.6	-4	.016*
Ag-Ag, mm	72.9	4.6	75.2	5.8	-2.3	.142

* $P < .05$; ** $P < .001$.

mm). No other statistically significant difference was detected between the 2 groups for any of the remaining cephalometric measures.

TPS analysis applied to PA cephalograms revealed statistically significant shape differences in the craniofacial configuration of subjects with anterior open bite malocclusion when compared with subjects with normal occlusion in the mixed dentition ($P < .013$) (Figure 3). Shape differences were localized in the zygomatic, maxillary, and mandibular regions. The greatest deformation could be described as a contraction in the zygomatic region (ie, a bilateral compression in the

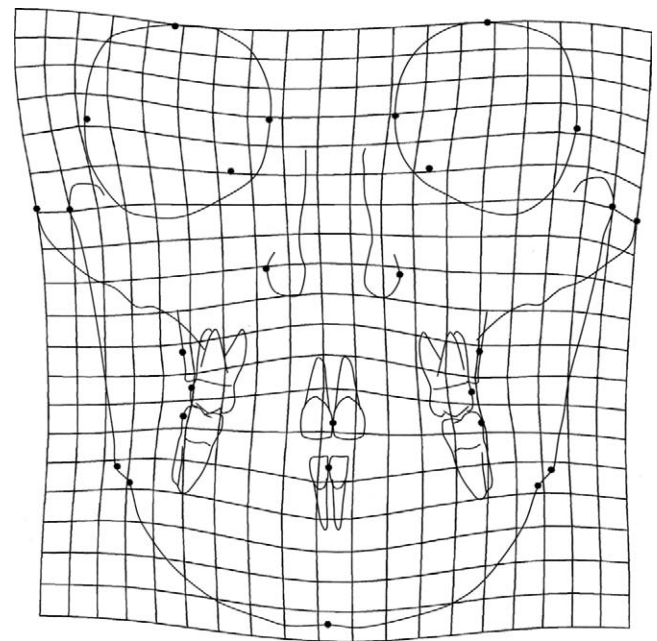


Figure 3. Thin-plate spline (TPS) graphical display of shape differences between the anterior open bite group and the control group (magnification factor, $\times 3$).

horizontal plane at point Zyg). A contraction of the maxilla at both skeletal and dental levels (ie, a bilateral compression in the horizontal plane at point Mx and at point Um bilaterally) was also evident. A slight contraction of the base of the nose was present. In the mandible, a contraction in the condylar and gonial regions with bilateral compression in the horizontal plane at points Cdl and Go was associated with a downward dislocation of point Me. No significant difference in shape could be detected in the orbital region when AOBG was compared with CG.

DISCUSSION

The aim of the present study was to evaluate the dentoskeletal features of subjects with anterior open bite in the mixed dentition using both conventional cephalometric analysis and TPS morphometric analysis applied to PA films. Major advantages of TPS analysis applied to cephalometric landmark configurations with respect to both conventional cephalometrics and previous morphometric techniques (eg, shape coordinate analysis) include the following: (1) optimal superimposition of landmarks for analysis of shape changes independently of size changes in complex skeletal configurations without the use of any conventional reference line, and (2) visual interpretation of craniofacial shape differences independent of size variations with the use of transformation grids.¹⁷

Results of the present study show that the opening hypothesis was rejected. In fact, the subjects in AOBG exhibited significant shape differences in craniofacial configuration in the frontal plane when compared with control subjects. Shape differences mainly consisted of a transverse contraction of the zygomatic region, of the maxilla (at both skeletal and dentoalveolar levels), and of the mandible (in both condylar and gonial regions) in AOBG with respect to CG. The mandible also showed a tendency toward vertical elongation in AOBG when compared with CG. This could be due to a significantly greater prevalence rate of hyperdivergent subjects in AOBG (57%) with respect to CG (23%).

Analysis of the results of conventional cephalometrics showed that AOBG presented transverse deficiency that involved the zygomatic region (-4.8 mm), the maxilla at both skeletal and dentoalveolar levels (-2.0 mm and -3.0 mm, respectively), and the mandible in both condylar and gonial regions (-3.6 mm and -4.0 mm, respectively).

It is interesting to note that no information is available in the literature about the transverse dentoskeletal characteristics of subjects with anterior open bite in the mixed dentition. The transverse dentoskeletal features of Class II and Class III malocclusions were

analyzed by means of conventional cephalometrics and TPS analysis. Franchi and Baccetti³⁰ found that both Class II and Class III malocclusions were characterized by transverse deficiency of the maxilla at both skeletal and dentoalveolar levels (-2.5 mm and -1.8 mm in Class II malocclusion, and -3.8 mm and -3.4 mm in Class III malocclusion, respectively) when compared with Class I occlusion. The present study showed that transverse deficiency in the maxilla at both skeletal and dentoalveolar levels is a typical feature of anterior open bite malocclusion in the mixed dentition. In the AOB group, however, transverse deficiency was not limited to the maxillary region but also involved the zygomatic and mandibular regions.

Several treatment approaches can be found in the literature with regard to early treatment of anterior open bite.³¹ These treatment modalities include functional appliances (FR4 with lip-seal training), repelling magnet splints, bite-blocks, and palatal crib associated with a high-pull chin cup. All these appliances are aimed at inhibiting mechanical factors that maintain anterior open bite (thumb sucking or tongue thrust) and/or at limiting excessive vertical growth of craniofacial skeletal components. It is interesting to note that none of these treatment protocols is aimed at correcting maxillary transverse dentoskeletal deficiency. The results of the current investigation show that transverse dentoskeletal features of subjects with anterior open bite in the mixed dentition may represent indications for treatment protocols aimed at increasing the transverse dentoskeletal dimension of the maxilla. The use of therapeutic devices such as rapid maxillary expanders or a quad-helix with a tongue crib appears to be indicated for the correction of transverse disharmony in patients with anterior open bite. Early treatment with quad-helix with crib assessed a good level of stability for the correction of dentoalveolar anterior open bite, in conjunction with permanent elimination of thumb-sucking habits.³² In addition, significant continued improvement in vertical relationships was detected in the posttreatment period.

CONCLUSIONS

Subjects with anterior open bite malocclusion showed a transverse deficiency in the zygomatic region, in the maxilla (at both skeletal and dentoalveolar levels), and in the mandible (in both condylar and gonial regions) when compared with normal subjects.

REFERENCES

1. Proffit WR. The development of vertical dentofacial problems: concepts from recent human studies. In: McNamara JA Jr, ed. *The Enigma of the Vertical Dimension*. Craniofacial Growth Series, vol 36. Ann Arbor, Mich: Center for

- Human Growth and Development, The University of Michigan; 2000:1–20.
2. Cangialosi TJ. Skeletal morphologic features of anterior open bite. *Am J Orthod.* 1984;5:28–36.
 3. Taibah SM, Feteih RM. Cephalometric features of anterior open bite. *World J Orthod.* 2007;8:145–152.
 4. Nahoum HI. Vertical proportions and the palatal plane in anterior open bite. *Am J Orthod.* 1971;59:273–282.
 5. Richardson AR. Skeletal factors in anterior open bite and deep over bite. *Am J Orthod.* 1969;56:114–127.
 6. Subtelny JD, Sakuda M. Open-bite: diagnosis and treatment. *Am J Orthod.* 1964;50:337–358.
 7. Hapak FM. Cephalometric appraisal of the open-bite case. *Angle Orthod.* 1964;34:65–72.
 8. Jones OG. A cephalometric study of 32 North American black patients with anterior open bite. *Am J Orthod Dentofacial Orthop.* 1989;95:289–296.
 9. Lopez-Gavito G, Little RM, Joondeph DR. Anterior open-bite malocclusion: a longitudinal 10-year postretention evaluation of orthodontically treated patients. *Am J Orthod.* 1985;87:175–186.
 10. Toutountzakis NE, Haralabakis NB. A postero-anterior cephalometric evaluation of adult open bite subjects as related to normals. *Eur J Orthod.* 1991;13:410–415.
 11. Moyers RE, Bookstein FL. The inappropriateness of conventional cephalometrics. *Am J Orthod.* 1979;75:599–617.
 12. Bookstein FL. On the cephalometrics of skeletal change. *Am J Orthod.* 1982;82:177–182.
 13. Cheverud JM, Lewis JL, Bachrach W, Lew WD. The measurement of form and variation in form: an application of three-dimensional quantitative morphology by finite-element methods. *Am J Phys Anthropol.* 1983;62:151–165.
 14. Lavelle CLB. A preliminary study of mandibular shape. *J Craniofac Genet Dev Biol.* 1985;5:159–165.
 15. Moss ML, Skalak R, Pateli H, Sen K, Moss-Salentijn L, Shinozuka M, Vilmann H. Finite element method modeling of craniofacial growth. *Am J Orthod.* 1985;87:453–472.
 16. Lestrel PE, Roche AF. Cranial base shape variation with age: a longitudinal study of shape using Fourier analysis. *Hum Biol.* 1986;58:527–540.
 17. Bookstein FL. *Morphometric Tools for Landmark Data.* New York, NY: Cambridge University Press; 1991:26–39.
 18. Bookstein FL. A hundred years of morphometrics. *Acta Zool.* 1998;44:7–59.
 19. Rohlf FJ, Marcus LF. A revolution in morphometrics. *Trends Ecol Evol.* 1993;8:129–132.
 20. Dryden IL, Mardia KV. *Statistical Shape Analysis.* New York, NY: John Wiley; 1998.
 21. Pae EK, Lowe AA, Fleetham JA. A thin-plate spline analysis of the face and tongue in obstructive sleep apnea patients. *Clin Oral Invest.* 1997;1:178–184.
 22. Singh GD, McNamara JA Jr, Lozanoff S. Spline analysis of the mandible in human subjects with Class III malocclusion. *Arch Oral Biol.* 1997;42:345–353.
 23. Lux CJ, Rübél J, Starke J, Conradt C, Angelika S, Komposch G. Effects of early activator treatment in patients with Class II malocclusion evaluated by thin-plate spline analysis. *Angle Orthod.* 2001;71:120–126.
 24. Franchi L, Baccetti T, Stahl F, McNamara JA Jr. Thin-plate spline analysis of craniofacial growth in Class I and Class II subjects. *Angle Orthod.* 2007;77:595–601.
 25. Björk A, Krebs A, Solow B. A method for epidemiological registration of malocclusion. *Acta Odontol Scand.* 1964;22:27–40.
 26. Merrifield LL, Klontz HA, Vaden JL. Differential diagnostic analysis systems. *Am J Orthod Dentofacial Orthop.* 1994;106:641–648.
 27. Dahlberg G. *Statistical Methods for Medical and Biological Students.* New York, NY: Interscience Publications; 1940.
 28. Rohlf FJ. *Tpsregr, version 1.35.* Stony Brook, NY: University of New York; 2008. Available at: <http://life.bio.sunysb.edu/morph>.
 29. Rohlf FJ, Slice DE. Extensions of the Procrustes method for the optimal superimposition of landmarks. *Systematic Zool.* 1990;39:40–59.
 30. Franchi L, Baccetti T. Transverse maxillary deficiency in Class II and Class III malocclusions: a cephalometric and morphometric study on postero-anterior films. *Orthod Craniofac Res.* 2005;8:21–28.
 31. Lentini-Oliveira D, Carvalho FR, Qingsong Y, Junjie L, Sacconato H, Machado MA, Prado LB, Prado GF. Orthodontic and orthopaedic treatment for anterior open bite in children. *Cochrane Database Syst Rev.* 2007;18:CD005515.
 32. Cozza P, Mucedero M, Baccetti T, Franchi L. Treatment and posttreatment effects of quad-helix/crib therapy of dento-skeletal open bite. *Angle Orthod.* 2007;77:640–645.