

Original article

Annals of Oncology 16: 590–596, 2005

doi:10.1093/annonc/mdi112

Published online 7 February 2005

Tumour-infiltrating gamma/delta T-lymphocytes are correlated with a brief disease-free interval in advanced ovarian serous carcinoma

M. R. Raspollini¹*, F. Castiglione¹, D. Rossi Degl'Innocenti¹, G. Amunni², A. Villanucci², F. Garbini¹, G. Baroni¹ & G. L. Taddei¹¹Department of Human Pathology and Oncology and ²Department of Gynecology, Perinatology and Reproductive Medicine, University of Florence, School of Medicine, Florence, Italy

Received 8 July 2004; revised 2 November 2004; accepted 15 November 2004

Background: Significant progress has been made in understanding the molecular biology of ovarian carcinoma. Along with the molecular characteristics of cancer, the patient's response to the tumour may also contribute to survival; in particular, the effect of the immune system may play an important role on survival of cancer patients.

Patients and methods: We analysed the CD3 positive tumour-infiltrating T cells and direct molecular assessment of T cell receptors (TCRs) gamma and beta in 95 advanced ovarian carcinomas.

Results: Gamma/delta T cells are statistically correlated with a brief disease-free interval ($P=0.036$). CD3 positive tumour-infiltrating T cells are correlated with a brief disease-free interval and with survival ($P=0.004$ and $P=0.0001$, respectively). CD3 positive tumour-infiltrating T cells are associated with clinical responsiveness to chemotherapy ($P=0.003$).

Conclusions: Further studies are required to better understand the role of gamma/delta T cells in ovarian carcinoma, yet these data underline the importance of host immune response to cancer and the need to better study immune mechanisms to modulate the therapeutic treatment of cancer.

Key words: alpha, beta T cell, CD3, gamma, delta T cell, ovarian carcinoma, T cells

Introduction

Among the gynaecologic malignancies, ovarian cancer is the most common cause of death in Europe and North America. Approximately 90% of all patients with ovarian carcinoma underwent surgery followed by chemotherapy. Ovarian cancer is a chemosensitive tumour, and platinum-based chemotherapy can produce objective remissions in several cases. Nevertheless, a considerable diversity in behaviour may be found among cases with similar clinical and pathological characteristics, with some patients experiencing exceptionally long survivals.

In recent years, significant progress has been made in understanding the molecular biology of ovarian carcinoma and in determining the importance that oncogenes and tumour suppressor genes play in carcinogenesis and tumoural progression.

Along with the molecular characteristics of cancer, the patient's response to the tumour may also contribute to shorter or longer survival; in particular the effect of the immune system on tumour development and progression may play an important role in overall survival of cancer patients. Immunologists have hypothesised the possibility that the immune system may eliminate cancers at an early stage and may permit the progression of other tumours. An observation that supports this hypothesis is that patients treated with immunosuppressive drugs have an increased prevalence of malignancies compared with the control population [1].

There is some experimental evidence that the immune system may also be involved in ovarian tumour progression, and consequently in clinical outcome of ovarian cancer patients. In fact, a lymphocytic infiltrate has been described in ovarian carcinoma [2, 3], and recently, Zhang et al. [4] showed that the presence of tumour-infiltrating T lymphocytes have a positive role in overall survival of ovarian carcinoma patients. The presence of infiltrating tumour T lymphocytes correlated with a better prognosis has also been reported for other tumours such as breast, prostate, renal cell, colorectal and hepatocellular carcinoma, and also melanoma [5–10].

*Correspondence to: Dr M. R. Raspollini, Department of Human Pathology and Oncology, University of Florence, School of Medicine, viale G.B. Morgagni, 85, 50134 Florence, Italy. Tel: +39-055-4478138; Fax: +39-055-4379868; E-mail: mariarosaria.raspollini@unifi.it

T lymphocytes carry antigen-recognition molecules, the T cell receptors (TCRs) gamma/delta or alpha/beta, on the cell surface [11]. The gamma/delta T cells and the alpha/beta T cells are commonly viewed as very different, in fact, alpha/beta T cell-deficient mice show defective immunity toward most pathogens [12], whereas gamma/delta T cell-deficient mice show increased susceptibility to solid tumours [13].

In the present study, we analysed the molecular assessment of TCRgamma and TCRbeta of ovarian tumour-infiltrating T lymphocytes and the CD3 positive ovarian cancer infiltrating T cells. We investigated whether there was an association between the presence of CD3 positive T cells and the presence of gamma/delta T cells or alpha/beta T cells and clinical outcome in a series of advanced ovarian serous carcinoma patients exists.

Patients and methods

Case selection

We selected tissue blocks of serous ovarian carcinoma, FIGO (International Federation of Gynecology and Obstetrics) stage III in the files of the Department of Human Pathology and Oncology of the University of Florence. The specimens were obtained from 95 patients with known follow-up, all of whom underwent surgical and chemotherapeutic treatment at the Department of Gynecology, Perinatology and Reproductive Medicine of the University of Florence from 1985 to 1999. Informed consent was obtained from all patients prior to surgery, and tumour samples were collected during surgery. We have compared a group of patients living with no evident disease 3 years after primary surgical treatment to a series of patients who died of progression of disease within 3 years of primary surgical treatment.

The women underwent a laparotomy for debulking of the gross neoplastic masses with abdominal hysterectomy, bilateral salpingo-oophorectomy, appendectomy and omentectomy with examination of the serosal surface and biopsies of any suspected lesions.

All patients were staged retrospectively, according to a modified FIGO staging system for malignant surface epithelial-stromal tumours [14].

A postoperative treatment was performed independently of the presence of residual disease in all patients, consisting of combined chemotherapy regimens with six cycles of cisplatin-based chemotherapy, unless the patients showed disease progression during this adjuvant treatment.

After completion of treatment, follow-up consisted of: a pelvic examination, measurement of tumour markers (CA-125, CEA, CA-19.9), pelvic and abdominal ultrasonography (every 3 months for 2 years, and subsequently every 6 months) and computer tomography (CT) of pelvis and abdomen (annually). The follow-up period for each patient was until death or at least 5 years after surgery.

The brief disease-free interval was defined as recurrence and/or metastasis occurring within 12 months of surgery and primary chemotherapeutic treatment [15, 16]. Patients with recurrent disease within 1 year of surgery have a very poor prognosis.

We evaluated the clinical response to first-line chemotherapy treatment according to CT of the pelvis and the abdomen with WHO (World Health Organisation) methods [17]: complete response (CR), partial response (PR), stable disease (S) and progression (P).

We analysed the following clinical, histopathological and immunohistochemical variables: the age of the patients, the residual disease after sur-

gery assigned as 1 or 2 respectively, with absent/minimal residual disease (<2 cm) or bulk residual disease (>2 cm) on completion of initial surgery prior to chemotherapy, and the grade of differentiation (G1, G2, G3). Moreover, the presence versus the absence of CD3 positive intratumoural T cells, and the presence versus the absence of gamma/delta T cells and alpha/beta T cells in ovarian carcinoma were also measured.

Tissue specimens and immunohistochemistry

The specimens were obtained by surgical resection in all cases and fixed in 10% formalin before being processed in paraffin. Hematoxylin–eosin stained sections from each histological specimen were reviewed by two pathologists to confirm the histological diagnosis and to select one representative paraffin block from each case for further studies. For immunohistochemical analysis, 3 µm sections were prepared, each section was deparaffinized using xylene and subsequently hydrated. The immunohistochemical studies were performed by the streptavidin–biotin–peroxidase method (UltraVision kit, LAB VISION, Fremont, CA) with diaminobenzidine as chromogen and hematoxylin as nuclear counterstain. As primary antibody we used a commercial mouse monoclonal confirm™ anti-CD3 (clone PS1) antibody (Ventana Medical Systems, Tucson, AZ) directed against an epitope present on T cells. All tissue sections then were placed on the Ventana automated stainer BenchMark XT™ ICH system using as revelation system iVIEW DAB Detection Kit. Primary antibody anti-CD3 was placed on the tissue sections and incubated for 32 min at 37°C. A negative control sample was included with each run by omitting the primary antibody and yielded no signal. Sections of positive CD3 tonsilla were used as positive control tissue. The control sections were treated in parallel with the samples in the same run. The immunohistochemically stained sections were evaluated without previous knowledge of the clinical outcome of each patient.

Evaluation of immunohistochemical staining

T cells were counted manually in 20 high-power fields. Intratumoural T cells were graded as 1+, 2+ and 3+ (5, 6–19 or 20 T cells per high-power field, respectively), as previously described [4]. To assess the interobserver variability in the evaluation of immunohistochemical staining, the evaluations of one author were compared with those of one of the other authors. Initially the slides were evaluated independently, and those graded diversely were subsequently reevaluated by the two authors together under a discussion microscope. The immunohistochemical analysis was evaluated in a blinded fashion with regard to the clinical data.

DNA extraction and genetic analysis of TCRgamma and TCRbeta

DNA was isolated from formalin-fixed, paraffin-embedded tissue sections. After dewaxing and proteinase K digestion, the DNA was heated to 96°C for 10 min to destroy proteinase K activity.

The PCR assay for TCRgamma rearrangement was performed in accordance with the previously described method [18], with slight modifications. In brief, the consensus primers were TVgamma (5'-AGGG-TTGTGTTGGAATCAGG-3') and TJgamma (5'-CGTCGACAACAAGT-GTTGTTCCAC-3').

The assay is a two-step PCR. The first reactions were carried out in a volume of 20 µl, with 1.5 mM MgCl₂, 0.125 mM dNTPs, 2 pmol of TJgamma primer and 1 U Taq polymerase (Applied Biosystems, USA) with 200–350 ng of DNA template. The cycle conditions were: 15 s at 94°C, 20 s at 58°C and 20 s at 72°C for 25 cycles.

Later on, 20 µl of fresh PCR reagents were added to the products of the first amplification, at concentration of 1.5 mM MgCl₂, 0.375 mM dNTPs, 12 pmol of TJgamma primer, 18 pmol of TVgamma primer and 1 U Taq

polymerase. The cycles of this second amplification were 31 with the same parameters as the previous reaction.

The PCR for TCRbeta rearrangement was performed in accordance with the previously described method [19]. The primers were D2 (5'-TCATGGTGTAACATTGTGGGGAC-3') and J2 (5'-AGCACBGTGAGCCCKGGTGCC-3'). The reactions were carried out in a volume of 50 μ l, with 1 mM MgCl₂, 0.25 mM dNTPs, 25 pmol of each primer and 1 U Taq polymerase. The cycle conditions were: 30 s at 94°C, 45 s at 64°C and 45 s at 72°C for 34 cycles.

PCR products were analysed by 15% acrylamide gel electrophoresis and visualised under UV illumination after ethidium bromide staining. In this way, a broad smear can be obtained from a sample with infiltration of polyclonal reactive T cells. Instead a discrete band suggests the presence of a monoclonal T lymphocyte proliferation. A PCR not showing smears or bands after polyacrylamide gel electrophoresis means a tissue does not contain reactive T cells.

Statistical analyses

The presence of CD3 positive intratumoural T cells and of the gamma/delta T cells, in the two groups of ovarian carcinoma patients, in relation to the brief disease-free interval, to the survival and to the clinical responsiveness to first line chemotherapy, was calculated according to logistic regression in univariate and multivariate analyses [20]. The shift in location of months of disease-free interval and of survival according to the presence or absence of CD3 positive intratumoural T cells was calculated according to the Wilcoxon Mann–Whitney test [21]. The shift in location of years of age in the ovarian carcinoma patients according to the presence or absence of CD3 positive intratumoural T cells was calculated according to the Wilcoxon Mann–Whitney test. Data analysis was performed using the SPSS Version 11.0 (Chicago, IL) statistical package. A *P* value <0.05 was considered to be statistically significant.

Results

In total 95 patients with advanced ovarian serous carcinoma were included in the analysis. We compared 40 patients living with no evident disease 3 years after primary surgical treatment to 55 patients who died of progression of disease no later than 3 years after primary surgical treatment. The ages of living patients ranged from 40 to 74 years (mean age was 57.6 years and the average was 60 years). Concerning the grade of differentiation, the series of living women was composed of five ovarian serous carcinoma high grade of differentiation (G1), 16 cases of G2, and 19 ovarian serous carcinoma low grade of differentiation (G3). Concerning the residual disease after surgery, 29 women (72.5%) had absent/minimal residual disease after surgery (<2 cm) and 11 (27.5%) had bulk residual disease (>2 cm) on completion of initial surgery prior to chemotherapy. Among the living women, 34 patients (85%) showed a clinical CR to chemotherapy after surgical treatment evaluated according to WHO criteria [17], three patients (7.5%) showed PR, while three patients (7.5%) displayed disease progression (P) during chemotherapy. None of the patients had stable disease.

The ages of deceased patients ranged from 30 to 75 years (mean age was 56.7 years and the average was 57 years). Concerning the grade of differentiation, the series of deceased women was composed of four cases of G1, 16 cases of G2

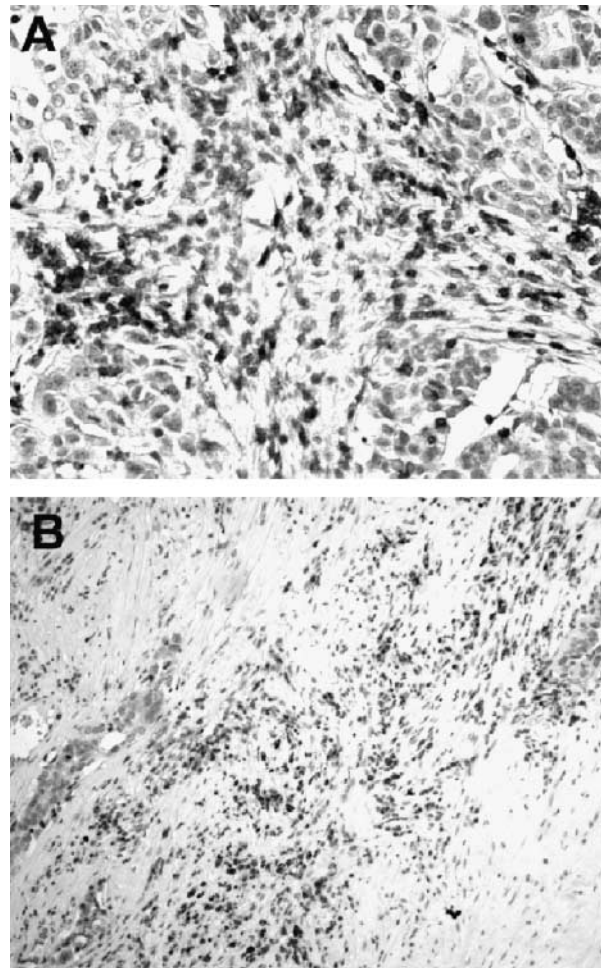


Figure 1. CD3 positive tumour-infiltrating T cells were detected in tumour (A) and in peritumoural stroma (B).

Table 1. Comparison of ovarian cancer patients with disease-free interval >12 months after primary surgical treatment to patients with brief disease-free interval (<12 months) (according to logistic regression in univariate and multivariate analyses)

Variable score	Brief disease-free interval					
	Univariate analysis			Multivariate analysis		
	Odds ratio	95% CI	<i>P</i>	Odds ratio	95% CI	<i>P</i>
CD3 positive intratumoural T cells						
0						
1	0.28	0.1–0.7	0.012	0.21	0.72–0.61	0.004
Residual disease						
0						
1	1.8	0.77–4.63	0.16	2.1	0.82–5.8	0.11
Grade of differentiation						
(G1) 0						
(G2) 1	0.28	0.06–1.1	0.085	0.2	0.41–1.02	0.54
(G3) 2	0.45	0.17–1.1	0.091	0.41	0.15–1.12	0.85

CI, confidence interval.

Table 2. Comparison of ovarian cancer patients living with no evident disease 3 years after primary surgical treatment with patients who had died of progression of disease no later than 3 years after primary surgical treatment (according to logistic regression in univariate and multivariate analyses)

Variable score	Survival					
	Univariate analysis			Multivariate analysis		
	Odds ratio	95% CI	<i>P</i>	Odds ratio	95% CI	<i>P</i>
CD3 positive intratumoural T cells						
0						
1	0.1	0.03–0.3	0.0001	0.05	0.15–0.19	0.0001
Residual disease						
0						
1	2.54	1.06–6.08	0.03	4.62	1.56–13.6	0.005
Grade of differentiation						
(G1) 0						
(G2) 1	0.43	0.1–1.81	0.2	0.21	0.03–1.36	0.1
(G3) 2	0.54	0.22–1.32	0.10	0.44	0.14–1.33	0.1

CI, confidence interval.

and 35 of G3. Concerning the residual disease after surgery, 28 women (50.9%) had absent/minimal residual disease after surgery (<2 cm) and 27 (49.1%) had bulk residual disease (>2 cm) on completion of initial surgery prior to chemotherapy. Among the deceased women, 28 patients (50.9%) showed a clinical CR to chemotherapy after surgical treatment evaluated according to WHO criteria, six patients (10.9%) showed a PR, while in 21 patients (38.2%) the disease pro-

Table 3. Presence of CD3 positive intratumoural T cells in relation to responsiveness to the first line chemotherapy (logistic regression in univariate and multivariate analyses)

Variable score	Responsiveness to first line chemotherapy					
	Univariate analysis			Multivariate analysis		
	Odds ratio	95% CI	<i>P</i>	Odds ratio	95% CI	<i>P</i>
CD3 positive intratumoural T cells						
0						
1	3.08	1.29–7.34	0.01	4.66	1.71–12.71	0.003
Residual disease						
0						
1	0.35	0.14–0.83	0.01	0.24	0.09–0.65	0.005
Grade of differentiation						
(G1) 0						
(G2) 1	1.72	0.39–7.61	0.4	1.91	0.37–9.85	0.43
(G3) 2	2.58	0.98–6.77	0.05	3.13	1.07–9.15	0.03

CI, confidence interval.

gressed during chemotherapy (*P*). None of the patients had stable disease.

The overall 36 month cause-specific survival rate was 57.8%. The brief disease-free interval rate was 65.2%.

Intratumoural T cells and correlation with clinico-pathological data

CD3 positive tumour-infiltrating T cells were detected in tumour and in peritumoural stroma (Figure 1A and B). CD3 positive T cells were counted in 58 cases (89.4%). Among the

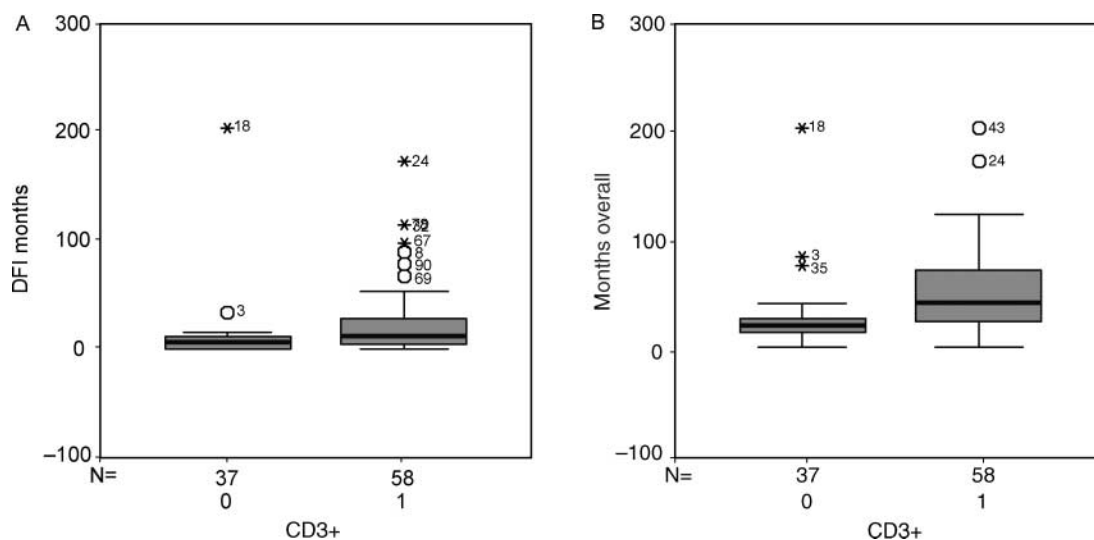


Figure 2. (A) Ovarian cancer patients whose tumours contained CD3 positive tumour-infiltrating T cells had an average duration of progression-free survival of 12 months, while the cancer patients whose tumours did not contain CD3 positive T cells had an average duration of progression-free survival of 6 months ($P=0.004$, according to Wilcoxon Mann–Whitney test). (B) Ovarian cancer patients whose tumours contained CD3 positive tumour-infiltrating T cells had an average duration of overall survival of 43 months, while the cancer patients whose tumours did not contain CD3 positive T cells had an average duration of overall survival of 22 months ($P=0.0001$, according to Wilcoxon Mann–Whitney test). DFI, disease-free interval.

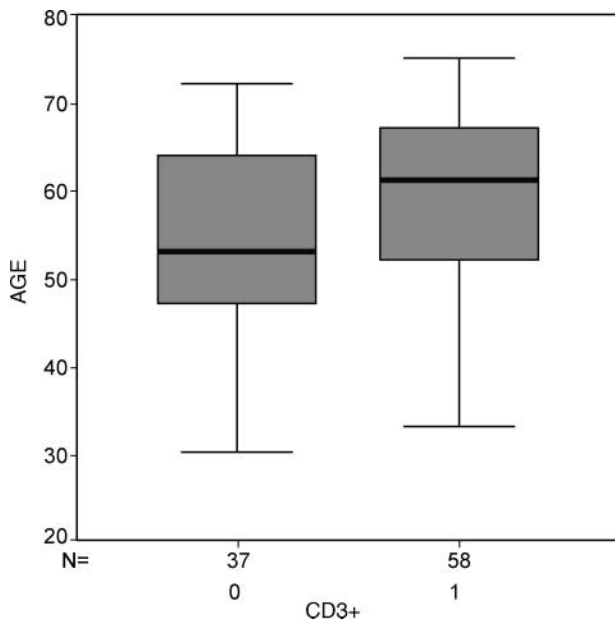


Figure 3. In the cases with CD3 positive tumour-infiltrating T cells, the average age was 61 years (range 33–75 years), while in the cases without CD3 positive tumour-infiltrating T cells the average age was 53 years (range 30–72 years) ($P=0.034$, according to the Wilcoxon Mann–Whitney test).

positive stained cases, 14 (14.7%) were graded 1+, 28 (29.4%) were graded 2+ and 16 (16.8%) were graded 3+.

CD3 positive tumour-infiltrating T cells are statistically correlated with brief disease-free interval and with the survival of the patient according to the logistic regression in univariate analysis ($P=0.012$ and $P=0.0001$, respectively). Using multivariate logistic regression analysis CD3 positive tumour-infiltrating T cells were found to be significant independent predictors of brief disease-free interval and survival ($P=0.004$ and $P=0.0001$, respectively) (Tables 1 and 2). In addition, CD3 positive tumour-infiltrating T cells are significantly associated with clinical responsiveness to first line chemotherapy in univariate and multivariate analyses ($P=0.01$ and $P=0.003$, respectively) (Table 3). Ovarian cancer patients whose tumours contained CD3 positive tumour-infiltrating T cells had a median duration of progression-free survival of 12 months and a median duration of overall survival of 43 months, compared to median duration of progression-free sur-

vival of 6 months and a median duration of overall survival of 22 months in patients without CD3 positive tumour-infiltrating T cells ($P=0.004$ and $P=0.0001$, respectively, according to Wilcoxon Mann–Whitney test; Figure 2A and 2B). In addition, ovarian carcinoma patients whose tumours contained CD3 positive tumour-infiltrating T cells had a median age of 61 years (range 33–75 years), compared to median age of 53 years (range 30–72 years) in women without CD3 positive tumour infiltrating T cells ($P=0.034$, according to Wilcoxon Mann–Whitney test; Figure 3).

Molecular assessment of TCRgamma and TCRbeta

Direct molecular assessment of TCRgamma and TCRbeta was performed. In 86 cases DNA extraction and subsequent PCR reaction were successful. None of the analysed samples revealed a molecular assessment of TCRbeta, while 27 samples (31.3%) revealed a molecular assessment of TCRgamma (Figure 4).

Molecular assessment of TCRgamma and correlation with clinico-pathological data

A molecular assessment of TCRgamma was counted in 27 cases (31.3%). Gamma/delta T cells are statistically correlated with the brief disease-free interval of the serous advanced ovarian carcinoma patients according to the logistic regression in univariate analysis ($P=0.036$, Table 4). We did not find gamma/delta T cells associated with overall survival nor with clinical responsiveness to first line chemotherapy.

Discussion

To the best of our knowledge, a study designed to determine the direct molecular assessment of TCRgamma and TCRbeta of intratumoural T cells in a series of primary advanced untreated ovarian serous carcinomas has never been performed. We observed with PCR no alpha/beta T cells in advanced ovarian serous carcinoma, but we detected gamma/delta T cells in 27 cases (31.3%). In addition, we observed that the presence of gamma/delta T cells was statistically correlated with brief disease-free interval of the serous advanced ovarian carcinoma patients.

In addition, our study confirms that intratumoural T cells have a prognostic role in advanced serous ovarian carcinoma,

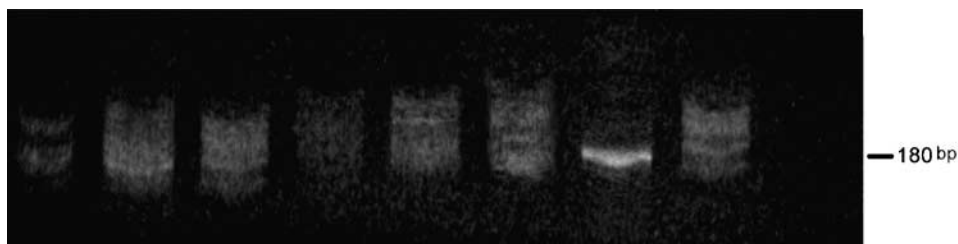


Figure 4. Ethidium bromide stained polyacrylamide gel of PCR products from ovarian serous carcinomas (lanes 1–6), monoclonal control (lane 7), polyclonal control (lane 8) and control without DNA (lane 9).

Table 4. Presence of gamma/delta T cells in relation to brief disease-free interval (logistic regression analysis)

Variable score	Brief disease-free interval		
	Odds ratio	95% CI	<i>P</i>
Gamma/delta T cells			
0			
1	3.23	1.07–9.71	0.036

CI, confidence interval.

as previously described by Zhang et al. [4]. The results of the study showed that CD3 positive tumour-infiltrating T cells detected in tumour and in peritumoural stroma, were statistically strongly correlated both with brief disease-free interval and with survival in logistic regression analysis in univariate and multivariate analyses. In addition, we observed an association between the CD3 positive tumour-infiltrating T cells with clinical responsiveness to first line chemotherapy.

The characterization of tumour-specific antigens has shown that tumours may have antigen determinants which are recognised by the immune system. A recent study indicated that these antigens may be tumour-specific peptides that are absent in all adult normal tissue except germline cells [22]. Immunotherapy using adoptive cell transfer is a promising approach that can result in the regression of bulk, invasive cancer in some patients [23, 24].

Concerning ovarian cancer, there is reported experimental evidence that some ovarian carcinoma specimens show a leukocyte infiltrate [4]. In addition, tumour-associated lymphocytes with polyclonal expansion were demonstrated in ovarian cancer cell lines [25, 26]. In ovarian carcinoma patients, it seems that the clinical outcome may depend on tumour characteristics (FIGO stage of disease, residual disease, histologic type and grade of differentiation) and on host response to cancer. The manipulation of immune mechanisms may offer powerful therapeutic tools for treatment of ovarian carcinoma patients. In recent years, several studies have focused on the possible use of T cells to attack established tumours. Lamers et al. [27] showed a local, but non systemic immunomodulation by intraperitoneal treatment of advanced ovarian carcinoma with autologous T cells. In the years to come, the knowledge of new data regarding T cells, such as the receptor pathway [28, 29] may give further data for the immunomodulation of therapeutic treatment in ovarian carcinoma patients.

In this study, we observed a brief disease-free interval in 81.4% of the cases showing gamma/delta T cells, while the brief disease-free interval rate is 57.6% in cases showing no gamma/delta T cells ($P=0.036$). Moreover, a recent study [30] showed that gamma/delta T cells, involved in inflammatory responses, play a central role in tissue damage.

Further studies are required to better understand the negative prognostic role of gamma/delta T cells in ovarian carcinoma, yet these data underline the importance of immune host response to cancer and the need to better study the immune mechanisms to modulate the therapeutic treatment of cancer.

References

- Dunn GP, Bruce AT, Ikeda H et al. Cancer immunoediting: from immunosurveillance to tumor escape. *Nat Immunol* 2002; 3: 91–998.
- Santin AD, Hermonat PL, Ravaggi A et al. Phenotypic and functional analysis of tumor-infiltrating lymphocytes compared with tumor-associated lymphocytes from ascitic fluid and peripheral blood lymphocytes in patients with advanced ovarian cancer. *Gynecol Obstet Invest* 2001; 51: 254–261.
- Negus RP, Stamp GW, Hadley J, Balkwill FR. Quantitative assessment of the leukocyte infiltrate in ovarian cancer and its relationship to the expression of C-C chemokines. *Am J Pathol* 1997; 150: 1723–1734.
- Zhang L, Conejo-Garcia JR, Katsaros D et al. Intratumoral T cells, recurrence, and survival in epithelial ovarian cancer. *N Engl J Med* 2003; 348: 203–213.
- Coulie PG, Karanikas V, Colau D et al. A monoclonal cytolytic T-lymphocyte response observed in a melanoma patient vaccinated with a tumor-specific antigenic peptide encoded by gene MAGE-3. *Proc Natl Acad Sci USA* 2001; 98: 10290–10295.
- Ikegaki M, Oi K, Hirooka Y, Kaibara N. CD8+ lymphocyte infiltration and apoptosis in hepatocellular carcinoma. *Eur J Surg Oncol* 2004; 30: 53–57.
- Marrogi AJ, Munshi A, Merogi AJ et al. Study of tumor infiltrating lymphocytes and transforming growth factor-beta as prognostic factors in breast carcinoma. *Int J Cancer* 1997; 74: 492–501.
- Vesalainen S, Lipponen P, Talja M, Syrjanen K. Histological grade, perineural infiltration, tumour-infiltrating lymphocytes and apoptosis as determinants of long-term prognosis in prostatic adenocarcinoma. *Eur J Cancer* 1994; 30A: 1797–1803.
- Naito Y, Saito K, Shiiba K et al. CD8+ T cells infiltrated within cancer cell nests as a prognostic factor in human colorectal cancer. *Cancer Res* 1998; 58: 3491–3494.
- Nakano O, Sato M, Naito Y et al. Proliferative activity of intratumoral CD8(+) T-lymphocytes as a prognostic factor in human renal cell carcinoma: clinicopathologic demonstration of antitumor immunity. *Cancer Res* 2001; 61: 5132–5136.
- Brenner MB, Strominger JL, Krangel MS. The gammadelta T cell receptor. *Adv Immunol* 1988; 43: 133–192.
- Mombaerts P, Arnoldi J, Russ F et al. Different roles of alfabeta and gammadelta T cells in immunity against an intracellular bacterial pathogen. *Nature* 1993; 365: 53–56.
- Girardi M, Oppenheim DE, Steele CR et al. Regulation of cutaneous malignancy by gammadelta T cells. *Science* 2001; 294: 605–609.
- Sobin LH, Wittekind Ch (eds): TNM Classification of malignant tumours, 60th edition. Geneva, Switzerland: UICC 2002.
- Markman M, Bookman MA. Second line treatment of ovarian cancer. *Oncologist* 2000; 5: 26–35.
- Markman M. Role of chemotherapy in the management of ovarian cancer. *Expert Rev Anticancer Ther* 2002; 2: 90–96.
- De Vita VT, Hellman S, Rosemberg SA. *Cancer, Principles and Practice of Oncology*, 5th Edition. Philadelphia, New York: Lippincott Raven 1997; 333–347.
- Benhattar J, Delacretaz F, Martin P et al. Improved polymerase chain reaction detection of clonal T-cell lymphoid neoplasm. *Diagn Mol Path* 1995; 4: 108–112.
- McCarthy KP, Sloane JP, Kabarowski JH et al. The rapid detection of clonal T-cell proliferations in patients with lymphoid disorder. *Am J Pathol* 1991; 4: 821–828.
- Hosmer DW, Lemeshow S. *Applied logistic regression*, 2nd edition. Charleston, South Carolina, USA. Wiley Interscience 2000.

21. Fisher LD, Van Belle G. *Biostatistics: A methodology for the health sciences*, 2nd edition. Charleston, South Carolina, USA. Wiley Interscience. 2003; 3rd series.
22. Restifo NP, Rosenberg SA. Developing recombinant and synthetic vaccines for the treatment of melanoma. *Curr Opin Oncol* 1999; 11: 50–57.
23. Rosenberg SA, Yang JC, Robbins PF et al. Cell transfer therapy for cancer: lessons from sequential treatments of a patient with metastatic melanoma. *J Immunother* 2003; 26: 385–393.
24. Finkelstein SE, Heimann DM, Klebanoff CA et al. Bedside to bench and back again: how animal models are guiding the development of new immunotherapies for cancer. *J Leukoc Biol* 2004; 76(2): 333–337.
25. Halapi E, Yamamoto Y, Juhlin C et al. Restricted T cell receptor V-beta and J-beta usage in T cells from interleukin-2-cultured lymphocytes of ovarian and renal carcinomas. *Cancer Immunol Immunother* 1993; 36: 191–197.
26. Hayashi K, Yonamine K, Masuko-Hongo K et al. Clonal expansion of T cells that are specific for autologous ovarian tumor among tumor-infiltrating T cells in humans. *Gynecol Oncol* 1999; 74: 86–92.
27. Lamers CH, Bolhuis RL, Warnaar SO et al. Local but no systemic immunomodulation by intraperitoneal treatment of advanced ovarian cancer with autologous T lymphocytes re-target by a bi-specific monoclonal antibody. *Int J Cancer* 1997; 73: 211–219.
28. Yang G, Mizuno MT, Hellstrom KE, Chen L. B7-negative versus B7-positive P815 tumor: differential requirements for priming of an antitumor immune response in lymph nodes. *J Immunol* 1997; 158: 851–858.
29. Greenfield EA, Nguyen KA, Kuchroo VK. CD28/B7 costimulation: a review. *Crit Rev Immunol* 1998; 18: 389–418.
30. Toth B, Alexander M, Daniel T et al. The role of gammadelta T-cells in the regulation of neutrophil-mediated tissue damage after thermal injury. *J Leukoc Biol* 2004; 76(3): 545–552.