



UNIVERSITÀ
DEGLI STUDI
FIRENZE

FLORE

Repository istituzionale dell'Università degli Studi di Firenze

Immunohistological features of genital warts before and after intralesional human lymphoblastoid alpha-interferon: evidence for a

Questa è la Versione finale referata (Post print/Accepted manuscript) della seguente pubblicazione:

Original Citation:

Immunohistological features of genital warts before and after intralesional human lymphoblastoid alpha-interferon: evidence for a substantial role of cell-mediated immunity in clinical regression / G. Zuccati; M. Mori; N. Pimpinelli; A. Mastrolorenzo; E. Panconesi. - In: CURRENT MEDICAL LITERATURE. VIROLOGY / THE ROYAL SOCIETY OF MEDICINE. - ISSN 0965-7134. - STAMPA. - supp(1993), pp. 104-111.

Availability:

This version is available at: 2158/357252 since:

Terms of use:

Open Access


La pubblicazione è resa disponibile sotto le norme e i termini della licenza di deposito, secondo quanto stabilito dalla Policy per l'accesso aperto dell'Università degli Studi di Firenze (<https://www.sba.unifi.it/upload/policy-oa-2016-1.pdf>)

Publisher copyright claim:

(Article begins on next page)



The Royal Society of Medicine



Current aspects and future perspectives

*Proceedings of the first international symposium on lymphoblastoid
alpha-interferon*

Porto Cervo, Sardinia, May 1992

Ferdinando Dianzani M.D.
*Professor and Chairman
Institute of Virology
University of Rome, Italy*

Supplement to
**Current
Medical
Literature**
Virology

Immunohistological features of genital warts before and after intralesional human lymphoblastoid alpha-interferon: evidence for a substantial role of cell-mediated immunity in clinical regression

Zuccati G, Mori M, Pimpinelli N, Mastrolorenzo A, Panconesi E, Clinica Dermosifilopatica I (STD) and Clinica Dermosifilopatica II; University of Florence, Florence, Italy.

Abstract

The relationship between immune deficiencies and human papilloma virus (HPV) infection is well documented, and the potential therapeutic role of interferons (IFNs) in the treatment of HPV infection has been emphasized in the last few years. In eight patients with genital warts, we performed an immunohistological study of lesional areas before and after treatment with intralesional human lymphoblastoid alpha-IFN (alpha n1-IFN). The aim of the study was to investigate the modifications of the immunohistological pattern, particularly concerning the possible different roles of specific immune cell populations and the expression of functional molecules. The most significant effects were observed after treatment, always resulting in clinically and histologically evident remission; these included:

- 1) a significant reversal of the clear-cut reduction of CD1a+, HLA-DR+ dendritic cells (DCs) in lesional epidermis;
- 2) a significant CD8+ T cell infiltrate underneath and immediately around the lesion;
- 3) a marked increase in the expression of LFA-1 (CD11a/CD18) molecules by both lymphocytes and DCs, presumably due to the indirect action of gamma-IFN;
- 4) HLA-DR and CD36 keratinocyte staining;
- 5) small, but significant, numbers of CD16+, CD56+ NK cells infiltrating the basal lesional epidermis;
- 6) a slight increase in dermal CD68+ macrophages.

The results of this study suggest that alpha n1-IFN mainly affects the cell-mediated immune response against HPV. This speculation is supported by the finding of HPV persistence in previously lesional, presently clinically normal mucosa, raising doubts on the importance of the antiviral effect of alpha n1-IFN.

Introduction

The role of the cell-mediated immune response in the pathogenesis and clinical course of human papilloma virus (HPV) infection is convincingly supported by both clinical evidence and laboratory investigations [1]. Indeed, HPV-related mucocutaneous diseases (common warts, condylomata acuminata, flat condylomata, bowenoid papulosis, epidermodysplasia verruciformis) are definitely more frequent and severe in both primary (Wiskott-Aldrich syndrome, Birtner syndrome, intestinal lymphagiectasia) [2,3] and secondary immunodeficiencies (chronic lymphocytic leukaemia, Hodgkin's and non-Hodgkin's lymphomas, AIDS, SLE, organ transplants, aggressive chemotherapy) [2,4]. An active involvement of the systemic immune response during HPV infection is strongly suggested by both in-vivo and in-vitro studies [5,6]. In fact, most patients with common warts (either active or regressing) show positive skin tests with viral antigens and reduced reaction of the leukocyte migration inhibition test with PPD and concanavalin A; interestingly, subjects with a clinical history of warts show an increased reaction of the leukocyte migration inhibition test and the lymphocyte transformation test after stimulation with HPV antigen. Concerning local cell-mediated immune responses, a clear-cut decrease in the number of HLA-DR+ epidermal Langerhans cells (LC) — 'sentinels' of the skin immune system [7] — has been reported in some in-vivo studies [8-10] but not in others [11,12].

The above findings justify the increasing use of immunomodulating agents in the treatment of HPV-related lesions.

Among these agents, alpha n1-IFN, which exerts both antiviral and immuno-modulating functions, has been reported to obtain the most significant clinical results [1,13-15].

In eight patients with genital warts, we performed an immunohistological study of lesional areas before and after treatment with intralesional alpha n1-IFN. The aim of the study was to investigate modifications of the immunohistological pattern, particularly the possible different roles of specific immune cell populations and the expression of functional molecules.

Materials and methods

We studied eight patients with genital warts (males, aged 18-45 years, median 26). The diagnosis was established according to clinical, histological, and in-situ hybridization (ISH) features. Intralesional alpha n1-IFN (1×10^6 IU, three times per week for six weeks) was given in all patients. After treatment, the patients were followed regularly for six months. The treatment resulted in complete clinical remission in all patients.

Biopsies were taken under local anaesthesia from lesional areas before and after alpha n1-IFN treatment. Each tissue specimen was in part formalin fixed and paraplast embedded for routine histological examination, in part embedded in ornithine carbonyl transferase (OCT) ('Tissue Tek', Miles Scientific, Naperville, IL, USA), snap frozen, and stored at -80°C until sectioning and preparation for immunohistochemistry.

Cryostat sections (6 mm) were air dried, fixed in acetone for 10 minutes, and processed according to an alkaline phosphatase-anti-alkaline phosphatase (APAAP) method [16]. Normal human lymph nodes were stained in parallel as positive controls. Sections incubated with an irrelevant, isotype-matched mouse antibody were used as negative controls.

Table 1. Monoclonal antibodies used in the study

Antibody	Cluster designation	Source
T11	CD2	CC
T3	CD3	CC
T4	CD4	CC
OKT8	CD8	OD
CD45RO	CD45RO	DP
OKT6	CD1a	OD
HLA-DR	-	BD
CL-106	CD54	*
MHM24	CD11a	DP
OKM1	CD11b	OD
LeuM5	CD11c	BD
MHM23	CD18	DP
LeuM3	CD14	BD
OKM5	CD36	OD
CD68	CD68	DP
CD16	CD16	DP
CD56	CD56	DP

CC = Coulter Clone, UK.

BD = Becton & Dickinson, Mountain View, CA, USA.

OD = Ortho Diagnostic Systems, Raritan, NJ, USA.

DP = Dakopatts, Denmark.

* = generous gift of Dr S. Ferrone, New York, USA.

The step section method was used to evaluate the results; serial sections of each tissue specimen were carefully evaluated. For a quantitative analysis, the stained cells were counted in five consecutive microscopic fields ($\times 250$), both in the dermis and the epidermis. The results in the dermis were expressed as the number of stained cells from a total of 100 observed cells; those in the epidermis were expressed as the number of stained cells overlying 100 basal cells. Only cells whose nuclei were contained in the plane of the section were considered. The results were scored independently by the two

authors, and the resulting figures were averaged. The antibodies used are listed in Table 1; their specificities have been reviewed elsewhere [17].

Results

Before alpha n1-IFN treatment

In all cases, the infiltrating cells consisted mainly of T cells and cells of monocyte-macrophage lineage.

In the lesional epidermis, both CD3+, CD45RO+ T cells and CD16+, CD56+ NK cells (Fig. 1) were virtually absent. Compared with clinically healthy mucosa, a marked reduction in the numbers of CD1a+ (Fig. 2) and HLA-DR+ (Fig. 3) dendritic cells (DCs) was found in all examined specimens. CD11c+ and CD14+ cells, more or less dendritic in shape, were found scattered only in the basal layer of lesional epidermis. HLA-DR+ keratinocyte staining was found only focally. No CD54 (ICAM-1)+ staining was found in lesional epidermis.

In the lamina propria, a variably dense infiltrate of CD3+, CD45RO+ T cells, with a CD4/CD8 ratio varying from 3:1 to 2:1, was consistently found at the margins of the lesion (Fig. 4). CD1a+ DCs were always found (Fig. 2) associated with T cells, their number being variable in relation to that of T cells. Both T cells and DCs were heavily HLA-DR+ (Fig. 3). CD54 (ICAM-1) was clearly expressed by dermal vessels and small perivascular clusters of DCs, in almost constant topographic relationship with CD11a+ and CD18+ cells (as judged by the careful evaluation of serial sections). CD36+ DCs (Fig. 5) were always found in similar numbers and location (mostly perivascular) to the skin [18] and oral mucosa [19]. Finally, CD68+ macrophages (Fig. 6) were found in




Figure 1. Before treatment. Virtually no CD56+ cells are present in the infiltrate (APAAP, $\times 160$).




Figure 2. Before treatment. The lesional epidermis is markedly depleted of CD1a+ DCs (Langerhans cells) (APAAP, $\times 100$).



Figure 3. Before treatment. Virtually no HLA DR+ DCs are present in lesional epidermis. In the lamina propria both lymphocytes and DCs strongly express HLA DR (APAAP, $\times 100$).




Figure 4. Before treatment. A few CD8+ T cells are shown in the superficial lamina propria, at the margins of the lesion (APAAP, $\times 160$).




Figure 5. Before treatment. CD36+ perivascular DCs are shown in the lamina propria (APAAP, $\times 100$).




Figure 6. Before treatment. CD68+ macrophages are shown in the lamina propria (APAAP, $\times 100$).




Figure 7. After treatment. A few CD56+ cells infiltrate the basal epidermal layer (APAAP, $\times 400$).




Figure 8. After treatment. Significant numbers of CD8+ T cells underlie and infiltrate the basal epidermis (APAAP, $\times 100$).




Figure 9. After treatment. The number of epidermal CD1a+ DCs is clearly increased (APAAP, $\times 100$).



Figure 10. After treatment. The number of epidermal HLA DR+ DCs is markedly increased (APAAP, $\times 100$).

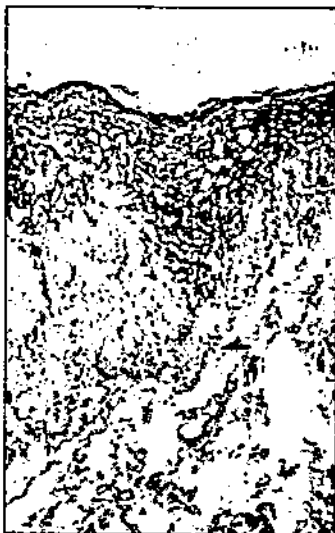


Figure 11. After treatment. No significant differences are evident concerning perivascular CD36+ DCs. A clear-cut CD36+ keratinocyte staining is present (APAAP, $\times 160$).

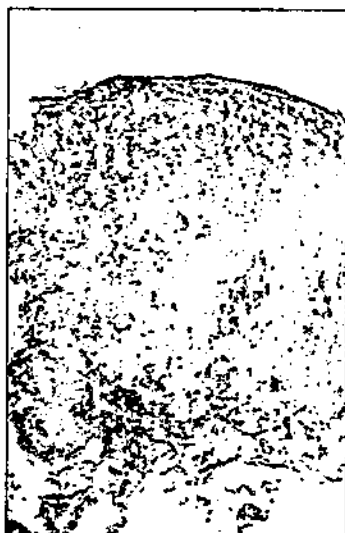

Figure 12. After treatment. A slight, but significant increase in the number of CD68+ cells in the lamina propria is evident (APAAP, $\times 100$).

slightly increased numbers compared with normal skin [20].

After alpha n1-IFN treatment

Intralesional alpha n1-IFN treatment always resulted in complete clinical remission, with almost complete regression of the histological signs typically associated with HPV infection.

In the epidermis, a discrete but significant infiltrate of both CD16+, CD56+ NK cells (Fig. 7) and CD3+, CD45RO+, CD8+ (Fig. 8), CD11a/CD18+ T cells was consistently found in the basal layer. Concerning DCs, an almost complete reversal of the pre-treatment pattern was observed. Indeed, a clear-cut increase in the numbers of CD1a+ (Fig. 9) and HLA-DR+ DCs (Fig. 10) was invariably found. Clear CD36+ (Fig. 11) and HLA-DR keratinocyte staining was consistently found, while keratinocyte staining for CD54 (ICAM-1) antigen was definitely focal or absent.

In the lamina propria, a significant infiltrate of CD3+, CD45RO+, CD8+ (Fig. 8), CD11a/CD18 T cells was found underlying (and infiltrating) the basal epidermis in previously lesional areas, in association with CD11a/CD18+ DCs. CD4+ T cells, associated with CD1a+ DCs, were consistently confined to the margins of previously lesional areas, without any significant difference compared with pre-treatment features. CD54 (ICAM-1) staining was confined to superficial vessels and small perivascular clusters of DCs, without significant differences compared with pre-treatment features. In addition, no differences were found in the numbers and location of CD36+ DCs (Fig. 11). The number of CD68+ macrophages was further increased compared with pre-treatment figures (Fig. 12).

Discussion

In this study, we have investigated the modification of the immunohistological pattern of genital warts after alpha n1-IFN intralesional treatment, with particular reference to the possible different roles of specific immune cell populations and the expression of functional molecules. Our results strongly suggest that the clinical effect of the treatment is mainly due to activation of different elements of the cell-mediated immune response.

The most significant effects were observed after treatment, always resulting in clinically and histologically evident remission; these included:

- 1) A significant reversal of the clear-cut reduction of CD1a+, HLA-DR+ dendritic cells (DCs) in lesional epidermis. These findings confirm the data in the literature [8-10], suggesting an impairment of the epithelial antigen-presenting (MHC class II molecule-mediated) capacity of HPV-related lesions, and indicate that the pharmacological treatment with alpha n1-IFN is capable of restoring the immunological function of epithelial DCs, as judged by the finding of a normal number of class II-expressing DCs [21].
- 2) A significant CD8+ T cell infiltrate underlying and infiltrating the basal epidermis in previously lesional areas.

This finding is in keeping with that reported in regressing warts [22]. In contrast, we could not confirm the recently reported increase in the numbers of infiltrating CD4+ T cells after alpha n1-IFN intralesional treatment of common warts [21]. In particular, infiltrating CD4+ T cells were confined to the margins of the lesion either before or after alpha n1-IFN treatment;

- 3) A marked increase in the expression of LFA-1 (CD11a/CD18) molecules by both lymphocytes and DCs. This phenomenon is possibly due to the indirect release of gamma-IFN [23], and is clearly suggestive of the functional capacity of infiltrating T cells. The LFA-1 expression by epidermal DCs, on the other hand, may have a functional role in the activation of alloreactive T cells [24]. The lack of an increased CD54 (ICAM-1) expression by DCs of the epithelium and lamina propria may be interpreted in the light of dose- and time-dependent differences in the induction of functional adhesion molecules by IFNs;
- 4) Clear-cut induction of HLA-DR and CD36 keratinocyte staining. This finding is also presumably related to the indirect release of gamma-IFN [23], and may have a role in the CD8+ T cell epidermotropism [25];
- 5) Small, but significant, numbers of CD16+, CD56+ NK cells infiltrating the basal epidermis in previously lesional areas. This finding indicates the possibility

that a non-MHC-restricted cytotoxic pathway is operating in this condition as well as in the spontaneous regression of HPV-induced lesions [26];

- 6) A slight increase in CD68+ macrophages in the lamina propria. This finding is in keeping with the reported ability of alpha n1-IFN to restore the impaired intrinsic antiviral activity of macrophages [27], and may be interpreted as the expression of a class I MHC-restricted immune response by macrophages [28].

In conclusion, the results of this study suggest that alpha n1-IFN affects mainly the cell-mediated immune response against HPV. Both class II and class I MHC-restricted pathways and NK cytotoxicity seem actively involved in the clinically evident action exerted — directly and indirectly — by alpha n1-IFN treatment. This speculation is supported by the finding of HPV persistence in lesional mucosa, documented by *in situ* hybridization, raising doubts about the importance of the antiviral effect of alpha n1-IFN.

REFERENCES

- [1] Zuccati G, Tiradritti L, Mastrolorenzo A, Panconesi E. Pharmacological immunotherapy in HPV infection. *J Chemother* 1991; 3 (suppl. 3): 403-5.
- [2] Lutzner MA. Papillomavirus lesions in immunodepression and immunosuppression. In: Jablonska S, Orth G, eds. *Warts/human papillomaviruses*. Philadelphia: Lippincott JB, 1985; 3: 165-9.
- [3] Cobb MW. Human papillomavirus infection. *J Am Acad Dermatol* 1990; 22: 547-66.
- [4] Barr BBB, McLaren K, Smith IW, Benton EC, Bunney MH, Blessing K. Human papilloma virus infection and skin cancer in renal allograft recipients. *Lancet* 1989; i: 124-8.
- [5] Chardonnet Y, Viac J, Staquer MJ, Thivolet J. Cell-mediated immunity to human papillomavirus. In: Jablonska S, Orth G, eds. *Warts/human papillomaviruses*. Philadelphia: Lippincott JB, 1985; 3: 156-64.
- [6] Stanley MA, Oriel JD. Immunobiology of genital warts and molluscum contagiosum. In: Wright DJM, ed. *Immunology of sexually transmitted diseases*. London: Kluwer Academic Publisher, 1988; 209-21.
- [7] Bos JD, Kapsenberg ML. The skin immune system (SIS). Its cellular constituents and their interaction. *Immunol Today* 1986; 7: 235-40.
- [8] Chardonnet Y, Viac J, Thivolet J. Langerhans cells in human warts. *Br J Dermatol* 1986; 115: 669-75.
- [9] Viac J, Haftek M, Chardonnet Y. Langerhans cells and human papillomavirus infections. In: Thivolet J, Schmitt D, eds. *Langerhans cell. Colloque INSERM/ J Libbey Eurotex Ltd*, 1988; 172: 449-60.
- [10] Drijkoningen M, De Wolf-Peeters C, Degreef H, Desmet V. Epidermal Langerhans cells, dermal dendritic cells, and keratinocytes in viral lesions of skin and mucous membranes: an immuno-histochemical study. *Arch Dermatol Res* 1988; 280: 220-7.

- [11] McMillan A, Bishop PE, Fletcher S. An immunohistological study of condylomata acuminata. *Histopathology* 1990; 17: 45-52.
- [12] Bhawan J, Dayal J, Bhan AK. Langerhans cells in molluscum contagiosum, verruca vulgaris, plantar wart, and condyloma acuminatum. *J Am Acad Dermatol* 1986; 15: 645-9.
- [13] Berman B, Frankfort HM. Human interferon system. *Int J Dermatol* 1982; 21: 12-18.
- [14] Blanchet-Bardon C et al. Interferon and retinoid treatment of warts. In: Jablonska S, Orth G, eds. *Warts/human papillomaviruses*. Philadelphia: Lippincott JB, 1985; 3: 195-9.
- [15] Stadler R, Mayer-da Silva A, Bratke B et al. Interferon in dermatology. *J Am Acad Dermatol* 1989; 20: 650-6.
- [16] Cordell JL, Folini B, Erber WN, Stein H, Mason DY. Immunoenzymatic labelling of monoclonal antibodies using immune complexes of alkaline phosphatase and monoclonal antialkaline phosphatase (APAAP) complexes. *J Histochem Cytochem* 1984; 32: 219-26.
- [17] Knapp W, Dorken B, Rieber P, Schmidt RE, Stein H, von dem Borne AEGKr. CD antigens 1989. *Am J Pathol* 1989; 135: 420-1.
- [18] Headington JT, Cerio R. Dendritic cells and the dermis: 1990. *Am J Dermatopathol* 1990; 12: 217-20.
- [19] Pimpinelli N, Borgognoni L, Riccardi R et al. CD36(OKM5)+ dendritic cells in the oral mucosa of HIV- and HIV+ subjects. *J Invest Dermatol* 1991; 97: 537-42.
- [20] Weber-Matthiesen K, Sterry W. Organization of the monocyte/macrophage system of normal human skin. *J Invest Dermatol* 1990; 95: 83-9.
- [21] Ghersetich I, Comacchi C, Lotti T. Studio immunofenotipico ed ultrastrutturale di verruche volgari multiple prima e dopo terapia con interferone alfa. *G Ital Derm Venereol* 1992; 127: 207-10.
- [22] Tagami H, Oguchi M, Ofuji S. Immunological aspects of wart regression with special reference to regression phenomenon of numerous flat warts. An experiment on tumor immunity in man by nature. *J Dermatol* 1983; 10: 1-12.
- [23] Barker JNWN, Allen MH, MacDonald DM. The effect of in vivo interferon-gamma of LFA-1 and ICAM-1 in normal human skin. *J Invest Dermatol* 1989; 93: 439-42.
- [24] Simon JC, Cruz PD, Tigelaar RE, Sontheimer RD, Bergstresser PR. Adhesion molecules CD11a, CD18, and ICAM-1 on human epidermal Langerhans cells serve a functional role in the activation of alloreactive T cells. *J Invest Dermatol* 1991; 96: 148-51.
- [25] Smolle J, Soyer HP, Juettner FM, Torne R, Stettner H, Kerl H. HLA-DR-positive keratinocytes are associated with suppressor lymphocytes epidermotropism. A biomathematical study. *Am J Dermatopathol* 1988; 10: 128-32.
- [26] Tagami H, Aiba S, Rokugo M. Regression of flat warts and common warts. In: Jablonska S, Orth G, eds. *Warts/human Papillomaviruses*. Philadelphia: Lippincott JB, 1985; 3: 170-8.
- [27] Merendino RA, Arena A, Liberto MC et al. Role of exogenous interferons on intrinsic antiviral activity of macrophages from patients affected by neoplasia. *J Chemother* 1990; 2: 116-22.
- [28] Debrick JE, Campbell PA, Staerz UD. Macrophages as accessory cells for class I MHC-restricted immune responses. *J Immunol* 1991; 147: 2846-51.