

Original Article

Mandibular Growth in Subjects with Infraoccluded Deciduous Molars: A Superimposition Study

Maria Leonardi^a; Pamela Armi^b; Tiziano Baccetti^{c,d};
Lorenzo Franchi^{d,e}; Mario Caltabiano^f

Abstract: The aim of this longitudinal cephalometric study was to analyze the growth characteristics of the mandible in subjects with infraocclusion of the mandibular deciduous molars. A group of 28 subjects with bilateral infraocclusion of mandibular deciduous molars (IG) were enrolled in a prospective longitudinal study on the growth characteristics of the mandible and compared with a control group (CG) of 28 subjects. Lateral cephalograms were collected in both groups at T1 and at T2, after a mean 19-month interval in the IG and after a mean 16-month interval in the CG. All subjects were observed in the early mixed dentition before the pubertal peak and did not receive any orthodontic treatment during the observation interval. Cephalometric analysis at T1 and superimposition of tracings at T1 and T2 were performed, and statistical comparisons between the two groups were carried out by means of independent sample *t*-tests. Discriminant analysis on the superimposition data identified Co-Gn angle (angle formed by line Co-Gn at T1 and at T2) as the single discriminant variable between IG and CG. There were significant differences between the two groups as to morphological changes of the mandible and direction of condylar growth, thus demonstrating anterior growth rotation of the mandible in subjects with infraocclusion. Because of the high levels of alveolar bone turnover and remodeling in anterior rotating mandibles, this study suggested that skeletal growth characteristics of the mandible may influence the clinical expression of infraocclusion. (*Angle Orthod* 2005;75:927–934.)

Key Words: Infraocclusion; Deciduous teeth; Mandibular rotation; Cephalometric superimpositions; Bone turnover; Alveolar growth

INTRODUCTION

Infraocclusion of deciduous molars is a dental anomaly consisting of an inferior position of affected

teeth relative to the occlusal plane of the adjacent teeth.^{1,2} The distance between the masticatory surface of the deciduous molar and the occlusal plane may vary considerably. Mild cases of infraocclusion exhibit a distance of 1–2 mm, whereas more severe infraocclusion may present a completely intraosseous position of the affected teeth.^{1,3} The prevalence of infraocclusion of deciduous molars varies between 1.3%⁴ and 38.5%.⁵ The prevalence of infraocclusion in the lower arch is higher than in the upper arch.^{1,6} Several studies have indicated that the mandibular second deciduous molar is more commonly involved than the mandibular first deciduous molar,⁷ whereas other investigations have shown the mandibular first deciduous molar is affected more often.⁶

Two main theories have attempted to clarify the causal agents in the etiology of infraocclusion, the local one and the genetic one. Biederman⁸ advocated that an alteration of metabolism in the periodontal tissues of the infraoccluded teeth could lead to ankylosis and, consequently, infraocclusion. It should be empha-

^a PhD Student, Department of Orthodontics, The University of Catania, Catania, Italy.

^b PhD Student, Department of Orthodontics, The University of Florence, Florence, Italy.

^c Assistant Professor, Department of Orthodontics, The University of Florence, Florence, Italy.

^d Thomas M. Graber Visiting Scholar, Department of Orthodontics and Pediatric Dentistry, School of Dentistry, The University of Michigan, Ann Arbor, Mich.

^e Research Associate, Department of Orthodontics, The University of Florence, Florence, Italy.

^f Professor of Orthodontics, Department of Orthodontics, University of Catania, Catania, Italy.

Corresponding author: Tiziano Baccetti, DDS, PhD, Università degli Studi di Firenze, Via del Ponte di Mezzo, 46–48, Firenze 50127, Italy
(e-mail: t.baccetti@odonto.unifi.it)

Accepted: September 2004. Submitted: July 2004.

© 2005 by The EH Angle Education and Research Foundation, Inc.

sized that ankylosis is not a consistent finding in infraocclusion⁶ and that the extent of the ankylosis may be variable.⁹ The hypothesis of a genetic origin for infraocclusion is supported by the presence of familial recurrence of the defect,^{1,4} by the expression of this dental anomaly in monozygotic twins,¹⁰ and by studies assessing different prevalence of infraoccluded teeth in different races and populations.⁵ Furthermore, it has been suggested that infraocclusion and other dental anomalies of shape, texture, number, and eruption may all represent microsymptoms of an inheritable disturbance because of a general disruption of the tooth developmental structures.^{2,11-13}

Some investigators^{1,3,14-16} have advocated that the pathogenesis of infraocclusion is a disturbance in the remodeling of the alveolar process related to the infraoccluded deciduous molar and could be involved in the development of this dental anomaly. Because of the fundamental role of bone turnover in tooth eruption, an anomaly in resorption/apposition of the alveolar bone could indeed affect the normal shedding of the deciduous teeth along with the physiologic eruption of the corresponding permanent teeth.^{17,18} The turnover of the alveolar bone as a component of growth of the dentoalveolar regions is related to characteristics of craniofacial growth and of mandibular growth in particular. As stated by Kuroi¹ "the developing dentition of a child is characterized by constant movement of teeth in a vertical direction correlated to the growth and development of the face and alveolar processes . . . the aberration of tooth eruption indicates a growth disturbance." In his classical implant studies Björk^{19,20} noted that the growth characteristics of the alveolar process are linked to different types of mandibular rotation. Petrovic and his research group^{21,22} have demonstrated that posteriorly growing mandibles express a lower rate of alveolar turnover, whereas anteriorly growing mandibles are associated with a greater rate of alveolar bone turnover in growing children.

Interestingly enough, the postulated relationship between craniofacial growth, alveolar growth/remodeling and establishment of infraocclusion has never been investigated by a longitudinal cephalometric study. The literature reports only a few cross-sectional studies that analyze the craniofacial features of subjects developing infraocclusion of a deciduous molar.^{11,14,15} Dixon¹⁴ found an increased angulation of the mandibular plane to the cranial base and a greater lower facial height. Kula et al¹¹ described a decreased ratio between posterior and anterior facial heights. Both studies agreed that there was an increased prevalence of augmented vertical dimensions of the face in children showing infraoccluded teeth. Brown¹⁵ did not corroborate these findings in his cross-sectional study.

Therefore, the aim of this longitudinal cephalometric study was to identify any differences in growth characteristics of the mandible in subjects with infraocclusion of mandibular deciduous molars vs a control group.

MATERIALS AND METHODS

Subjects

The examined sample consisted of subjects included in a prospective study at the Departments of Orthodontics of the University of Catania and the University of Florence. To be enrolled in the study, the subjects had to be of Caucasian ancestry and to not have received any previous orthodontic treatment. Subjects with craniofacial syndromes, odontomas, cysts, cleft lip or palate (or both), extensive caries, or sequelae of traumatic injuries were not considered eligible for the study.

The diagnosis of infraocclusion was made when one or more deciduous molars were more than one mm below the occlusal plane of the neighboring teeth as determined at clinical examination, and it was confirmed on panoramic radiographs (Figure 1). To be included in this investigation, subjects had to present with infraoccluded teeth on both sides of the lower arch, with two, three, or all four deciduous mandibular molars involved. Furthermore, all subjects had to be in the mixed dentition with fully erupted lower first permanent molars and upper and lower permanent incisors.

A sample of 28 subjects (nine males and 19 females) with bilateral infraocclusion of lower deciduous molars comprised the infraocclusion group (IG). Detailed characteristics of IG included 14 subjects with infraocclusion of two mandibular deciduous molars, nine with infraocclusion of three mandibular deciduous molars, and five with infraocclusion of four mandibular deciduous molars. Ten subjects presented with associated dental anomalies as diagnosed from the clinical examination and from panoramic radiographs (agenesis of third molars, enamel hypoplasia, ectopic eruption of upper first permanent molars, etc).

Lateral cephalograms at two consecutive time periods were available for the IG. No subject received any orthodontic treatment or extraction of infraoccluded teeth between T1 and T2. The mean age of the IG was eight years and six months at T1 and 10 years and two months at T2, with an average observation interval of 19 months. Individual skeletal maturation was assessed on both T1 and T2 cephalograms using the cervical vertebral maturation method.²³ All subjects showed stage I or II in cervical vertebral maturation at both observation times, thus indicating prepubertal skeletal maturity.

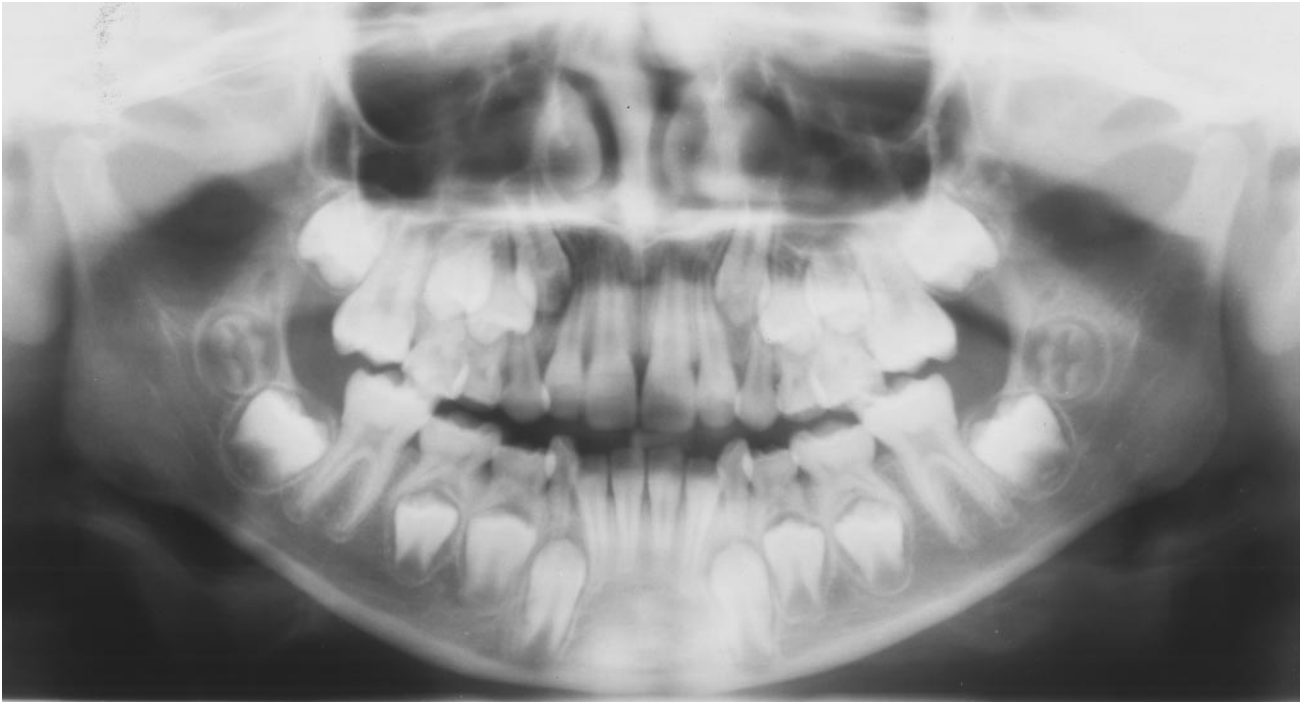


FIGURE 1. Male subject, eight years and 10 months, infraocclusion group. Panoramic radiograph showing infraocclusion of all four mandibular deciduous molars.

A control group of 28 children (CG, 15 males and 13 females) was selected randomly among subjects referred to the Department of Orthodontics of the University of Florence for periodic orthodontic counseling. Lateral cephalograms at two consecutive time periods with no orthodontic treatment were available for the CG as well. The CG matched the IG as to phase of the dentition, mean age at T1 (nine years), mean age at T2 (10 years and six months), mean observation interval without treatment (16 months), and as to CVM stages at T1 and T2. In both, the IG and the CG lateral cephalograms at T1 and T2 were taken with the same X-ray machine. An informed consent was obtained from the parents of all subjects.

Cephalometric analysis

Lateral cephalograms were analyzed for each patient at T1 and T2. Each cephalogram was hand traced with a 0.3-mm lead pencil by one investigator (Dr Leonardi) and subsequently checked by another investigator (Dr Armi). The traced lateral cephalograms were analyzed by a digitizing tablet (Numonics, Lansdale, Pa) and digitizing software (Viewbox, version 3.0, D Halazonetis, Athens, Greece).

Cephalometric regimen for the analysis of starting forms. The cephalometric analysis on the lateral cephalograms at T1 required the digitization of 32 landmarks on dental and skeletal structures and generated 24 variables.^{24,25}

Cephalometric superimpositions. A study superimposing on stable mandibular structures according to the methodology described by Björk¹⁹ and by Björk and Skieller²⁰ was performed in both the IG and CG groups. The modification by Tollaro et al²⁶ to the original procedure by Björk¹⁹ was adopted. Consequently, in the present superimposition study the stable basicranial line (SBL) was substituted for the nasion-sella line (NSL). The SBL passes through the most superior point of the anterior wall of the sella turcica at the junction with tuberculum sellae (point T) and the Fronto-Maxillo-Nasal suture (point FMN).²⁷ The SBL is traced through structures that do not undergo remodeling from the age of four to five years.²⁸

In the present mandibular rotation study, the changes in mandibular morphology and the direction of condylar growth were assessed at T1 and T2 by measuring the following angles formed by the lines on the superimposed tracings (Figure 2):

- Co-Gn angle, where Co-Gn is a line connecting point Condylion to point Gnathion, thus indicating total mandibular length;
- Co-Go angle, where Co-Go is a line connecting point Condylion to point Gonion;
- SBL angle, where SBL is the stable basicranial line;
- RL angle, where RL is the ramus line, ie, the line tangent to the posterior border of the ramus and the condyle;²⁹
- ML angle, where ML is the mandibular line, ie, the

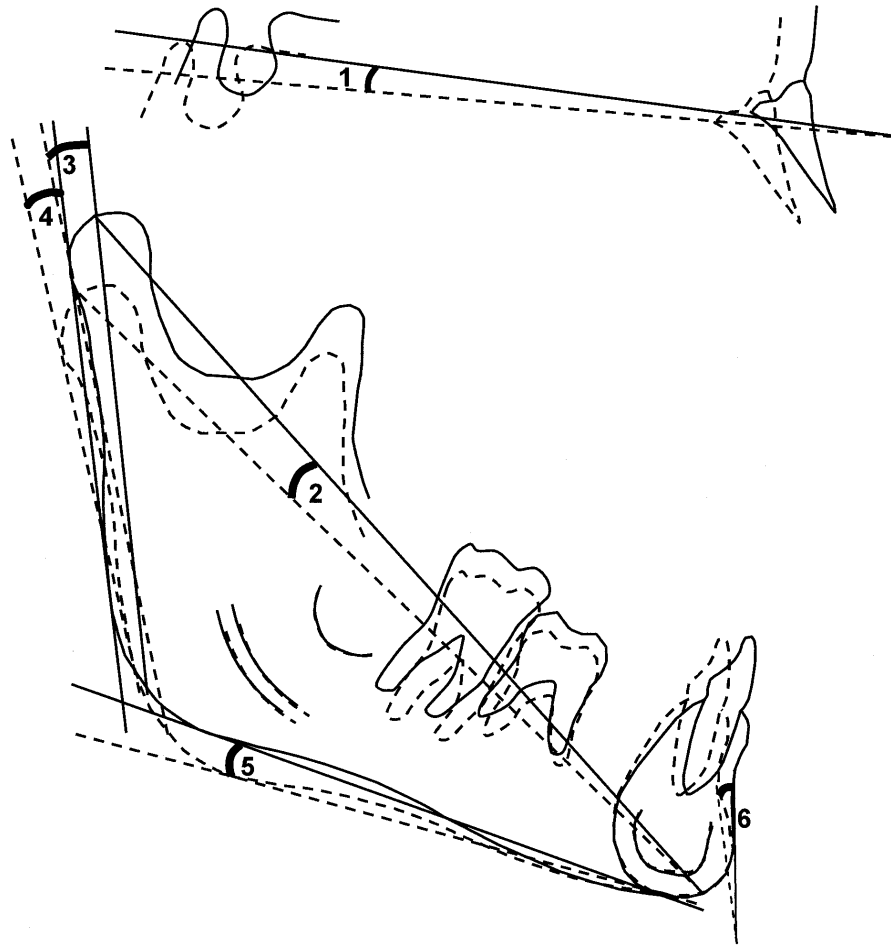


FIGURE 2. Cephalometric analysis on mandibular superimpositions. Dotted line tracing, T1; continuous line tracing, T2. Angular measurements: (1) Stable Basicranial Line angle; (2) Co-Gn angle; (3) Co-Go angle; (4) Ramus Line angle; (5) Mandibular Line angle; and (6) CTL angle.

line tangent to Gnathion and the inferior border of the ramus;²⁹

- CTL angle, where CTL is a line passing through point B and tangent to the anterior contour of the chin.³⁰

Statistical analysis

Descriptive statistics were calculated for the variables in both the cephalometric and superimposition studies. The relatively limited number of subjects in the two groups required assessment of normality for data distribution. Shapiro-Wilk's test was used and revealed normal distribution of the measures in both IG and CG groups. A comparison of starting forms between the IG and the CG was carried out on cephalometric variables at T1 by an independent sample *t*-test. Independent sample *t*-test was used also to evaluate the between-group differences in the craniofacial changes from T1 to T2 on the superimposed lateral cephalograms.

Discriminant analysis was applied to superimposi-

tion data to identify those variables that reflected the most distinctive skeletal growth changes between the two groups. A stepwise variable selection was performed with the goal of obtaining a model with the smallest set of significant discriminant variables between IG and CG. Forward selection procedure with *F*-to-enter and *F*-to-remove equal to four was chosen. When the smallest set of significant discriminant variables was selected, classification power of the model was calculated.

All computations were carried out with the SPSS software package (Statistical Package for the Social Sciences for Windows, version 12.0, SPSS Inc, Chicago, Ill).

Method error

The error of the data acquisition for the cephalometric method at T1 has been described previously.²⁴ The assessment of the method error for the superimposition study was performed with the Dahlberg's formula³¹ on measures repeated after two months on 15

TABLE 1. Comparison of Starting Forms for Infraocclusion Group (IG) and Control Group (CG) at T1^a

Cephalometric Measures	IG (N = 28)		CG (N = 28)		IG vs CG
	Mean	SD	Mean	SD	Significance ^a
<i>Cranial base</i>					
Cranial Flexure (°)	128.7	4.9	131.4	5.1	NS
<i>Maxillary skeletal</i>					
Co-Pt A (mm)	84.0	3.9	83.9	3.9	NS
SNA (°)	79.6	3.6	81.1	4.9	NS
<i>Mandibular skeletal</i>					
Co-Gn (mm)	106.1	4.4	106.6	4.6	NS
SNB (°)	75.7	3.1	76.6	4.3	NS
<i>Maxillary/mandibular</i>					
Max-mand differential (mm)	22.0	3.2	22.7	3.1	NS
ANB (°)	3.9	2.2	4.6	2.7	NS
<i>Vertical skeletal</i>					
S-Go (mm)	69.9	4.1	70.2	4.5	NS
N-Me (mm)	112.0	6.1	111.0	7.2	NS
S-Go/N-Me	62.5	4.4	63.4	4.6	NS
N-ANS (mm)	50.5	3.5	50.0	3.3	NS
ANS-Me (mm)	63.6	4.5	63.3	5.7	NS
ANS-Me/N-Me	56.8	2.1	56.9	2.5	NS
FH-Palatal plane (°)	-3.1	3.2	-3.0	3.8	NS
MPA (°)	25.4	5.0	23.4	5.6	NS
Palatal plane-mand plane (°)	28.5	5.2	26.4	5.4	NS
Gonial angle (°)	127.4	6.9	124.8	6.5	NS
<i>Interdental</i>					
Overjet (mm)	5.9	2.2	5.4	2.7	NS
Overbite (mm)	2.4	3.0	2.4	3.0	NS
Interincisal angle (°)	133.2	10.0	129.4	10.6	NS
<i>Maxillary dentoalveolar</i>					
Upper incisor to A perpendicular (mm)	4.7	1.4	5.1	2.3	NS
Upper incisor to FH (°)	112.1	5.5	114.4	8.0	NS
<i>Mandibular dentolaveolar</i>					
Lower incisor to A-Pg (mm)	1.9	1.6	2.1	2.6	NS
Lower incisor to Mand plane (°)	89.3	7.6	92.9	7.8	NS

^a NS indicates not significant; Max, maxillary; Mand, mandibular.

subjects (10 subjects of the IG group and five subjects of the CG group) randomly selected from the two groups. The standard error ranged from 0.4° for SBL angle to 1.1° for Co-Go angle.

RESULTS

Descriptive statistics for the two groups and comparison of starting forms are shown in Table 1. Statistical analysis did not show any significant difference for any cephalometric variable between IG and CG when compared at T1.

The results of the comparison of T1-T2 changes on cephalometric superimpositions between the two groups are shown in Table 2. There were statistically significant differences between IG and CG in the Co-Gn angle ($P < .001$), Co-Go angle ($P < .01$), RL angle ($P < .05$), and ML angle ($P < .001$). All these angles

increased significantly more in the IG group than in the CG during the observation interval. No statistically significant differences were exhibited between the IG and the CG in the SBL and CTL angles on superimposed tracings.

Discriminant analysis on the superimposition data revealed a single discriminant variable between IG and CG: Co-Gn angle. The classification power of the selected variable was 70%.

DISCUSSION

This study analyzed growth characteristics of the mandible in subjects with infraoccluded deciduous molars at the lower arch with several original investigation features: (1) craniofacial growth changes, namely mandibular rotation, were assessed in subjects with infraocclusion of deciduous molars by a longitudinal

TABLE 2. Comparison of T₁-T₂ Changes as Assessed by Cephalometric Superimpositions

Cephalometric Measures (°)	Infraocclusion Group (N = 28)		Control Group (N = 28)		Difference	Significance
	Mean	SD	Mean	SD		
Co-Gn	2.6	1.5	1.1	1.4	1.5	***
Co-Go	3.3	2.1	1.3	2.3	2.0	**
SBL	2.0	2.0	1.2	2.7	0.8	NS
RL	2.8	2.1	1.3	2.4	1.5	*
ML	2.2	1.6	0.7	1.5	1.5	***
CTL	1.2	3.5	0.6	4.4	0.6	NS

* $P < .05$; ** $P < .01$; *** $P < .001$; NS = not significant.

cephalometric analysis; (2) superimpositions on mandibular stable structures were used as an appropriate cephalometric model to evaluate the morphological changes of the mandible and the direction of condylar growth; and (3) mandibular growth modifications in subjects with infraocclusion were compared with changes in a matched control group.

Because of the higher prevalence of infraocclusion in the lower arch and the specific aim of investigating the relationships between mandibular growth and infraocclusion, all subjects with infraocclusion enrolled in the study presented with affected deciduous molars in the mandibular arch.

The conceptual bases for this investigation were, on one hand, the demonstrated role of bone turnover in both physiologic and anomalous aspects of tooth eruption through resorption/apposition mechanisms of the alveolar bone^{1,2,7,17,18,32,33} and, on the other hand, the differential growth of the dentoalveolar regions as a function of mandibular growth rotation.^{21,22}

The results of the present study identified a significant relationship between infraocclusion of lower deciduous molars and growth changes of the mandible. The IG showed significantly different changes in the morphology and growth direction of the mandible when compared with the controls. In particular, a significantly more anterior direction of condylar growth was found in the IG (significantly greater increases for Co-Gn angle as compared with the CG). The mandibular ramus expressed a similar behavior in the IG (significantly greater increases for RL angle and Co-Go angle, with respect to CG). All these measurements can be considered as significant signs of anterior mandibular rotation. No significant differences between the IG and CG were assessed for the changes in the inclination of the mandible to the cranial base (SBL angle) and for the morphology of the anterior contour of the chin (CTL angle). A significantly greater change in the ML angle in the IG vs the CG revealed a significant remodeling at the lower border of the mandibular body.

The findings need to be interpreted in terms of either morphological or positional changes of mandibular growth according to the definitions by Ødegaard²⁹ and

by Lavergne and Gasson.³⁴ Subjects with bilateral infraocclusion of deciduous molars in the lower arch exhibited a significant morphological rotation of the mandible in an anterior direction, whereas no significant difference with respect to controls was present when considering the positional rotation of the mandible within the craniofacial complex. It must be noted that besides the significant differences in the superimposition data between IG and CG, 100% of the subjects in the IG showed anterior growth direction of condylar growth, whereas only 60% of the subjects expressed this mandibular growth pattern in CG. Finally, discriminant analysis revealed that Co-Gn angle (which is the most appropriate measurement of morphological rotation of the mandible³⁴) was the single cephalometric variable that produced the most efficient separation between subjects with infraocclusion and controls.

Petrovic and coworkers,^{21,22} demonstrated a higher level of alveolar bone turnover in subjects with morphological anterior growth rotation of the mandible when compared with subjects with posterior mandibular rotation. On the basis of these findings, the results of this study indicate that infraocclusion of mandibular deciduous molars is associated with a relatively high level of alveolar bone turnover when compared with a normative control group. The abundant alveolar development in the mandibular dentoalveolar region in subjects with infraocclusion appears to be involved in the clinical manifestation of tooth submergence, thus confirming previous suggestions on the pathogenesis of infraocclusion.^{1,3,14-16} Regardless of the local etiologic factors for infraocclusion (defective enzymatic activity in the periodontal ligament³² or biochemical peculiarities³⁵), the clinical evidence of infraocclusion is derived from the lack of coordination between the remodeling processes at the roots of the deciduous molars and the growth characteristics of the surrounding alveolar bone,^{1,2} which are strictly correlated with mandibular rotational type.

One of the distinctive features of this study was the use of superimpositions on mandibular stable structures to evaluate the morphological changes of the mandible and the direction of condylar growth in the

IG when compared with a CG. Previous cephalometric data,^{11,14} describing the skeletal relationships in subjects with infraocclusion of deciduous molars, reported a tendency for increased vertical dimensions of the face in association with the dental anomaly. However, these studies were all cross-sectional in nature and, consequently, were not able to derive adequate information about the growth characteristics of craniofacial structures. In the sample with infraocclusion examined in this study, no difference was found for the positional inclination of the mandible to the Frankfort Plane at time of first observation with respect to controls.

The findings of this study emphasize the importance of the analysis of growth characteristics of the craniofacial skeleton, of the mandible especially, in subjects with dental anomalies such as infraocclusion of deciduous teeth. Dentoalveolar remodeling processes, because they relate to the growth direction at the skeletal level, can modulate the clinical expression of disturbances in tooth development and eruption.

CONCLUSIONS

- In the present longitudinal study, a group of growing subjects with infraocclusion of deciduous molars in the lower arch presented with significant anterior rotation of the mandible. This significant association involved measurements of morphological mandibular rotation.
- No significant differences between a group with infraoccluded deciduous molars and a control group were found for the changes in the positional inclination of the mandible to the cranial base.
- Because of the demonstrated high levels of alveolar bone turnover and remodeling in anterior rotating mandibles, it is suggested that skeletal growth characteristics of the mandible may influence the clinical expression of infraocclusion.

REFERENCES

1. Kurol J. Infraocclusion of primary molars: an epidemiologic and familial study. *Community Dent Oral Epidemiol.* 1981; 9:94–102.
2. Kurol J, Magnusson BC. Infraocclusion of primary molars: a histologic study. *Scand J Dent Res.* 1984;92:564–576.
3. Baccetti T, Tollaro I. Infraocclusion of primary molars as a dental anomaly of genetic origin. In: Radlanski RJ, Renz H, eds. *Proceedings of 10th International Symposium on Dental Morphology.* Berlin: C&M Brünne Gbr; 1995:428–432.
4. Via WF. Submerged deciduous molars: familial tendencies. *J Am Dent Assoc.* 1964;69:127–129.
5. Koyoumdjisky-Kaye E, Steigman S. Ethnic variability in the prevalence of submerged primary molars. *J Dent Res.* 1982;61:1401–1404.
6. Darling AI, Levers BG. Submerged human deciduous molars and ankylosis. *Arch Oral Biol.* 1973;18:1021–1040.
7. Rygh P, Reitan K. Changes in the supporting tissues of submerged deciduous molars with and without permanent successors. *Trans Eur Orthod Soc.* 1963;39:171–184.
8. Biederman W. The problem of the ankylosed tooth. *Dent Clin North Am.* 1968;409–424.
9. Andersson L, Blomlof L, Lindskog S, Feiglin B, Hammarstrom L. Tooth ankylosis. Clinical, radiographic and histological assessments. *Int J Oral Surg.* 1984;13:423–431.
10. Dewhurst SN, Harris JC, Bedi R. Infraocclusion of primary molars in monozygotic twins: report of two cases. *Int J Pediatr Dent.* 1997;7:25–30.
11. Kula K, Tatum B, Owen D, Smith RJ, Rule J. An occlusal and cephalometric study of children with ankylosis of primary molars. *J Pedod.* 1984;8:146–159.
12. Bjerklin K, Kurol J, Valentin J. Ectopic eruption of maxillary first permanent molars and association with other tooth and developmental disturbances. *Eur J Orthod.* 1992;14:369–375.
13. Baccetti T. A controlled study of associated dental anomalies. *Angle Orthod.* 1998;68:267–274.
14. Dixon DA. Observations on submerging deciduous molars. *Dent Pract.* 1963;13:303–315.
15. Brown ID. Some further observations on submerging deciduous molars. *Br J Orthod.* 1981;8:99–107.
16. Becker A, Karnei-R'em RM. The effects of infraocclusion: part 2. The type of movement of the adjacent teeth and their vertical development. *Am J Orthod Dentofacial Orthop.* 1992;102:302–309.
17. Cahill DR, Marks SC Jr. Tooth eruption: evidence for the central role of the dental follicle. *J Oral Pathol.* 1980;9:189–200.
18. Marks SC Jr, Schroeder HE. Tooth eruption: theories and facts. *Anat Rec.* 1996;245:374–393.
19. Björk A. Prediction of mandibular growth rotation. *Am J Orthod.* 1969;55:585–599.
20. Björk A, Skieller V. Normal and abnormal growth of the mandible. A synthesis of longitudinal cephalometric implant studies over a period of 25 years. *Eur J Orthod.* 1983;5:1–46.
21. Petrovic A, Stutzmann J. Orthodontics: state of the art, essence of the science. In: Lee Graber, ed. *The Concept of Mandibular Tissue-level Growth Potential and Responsiveness to a Functional Appliance.* St Louis, Mo: CV Mosby Co; 1986:659–674.
22. Stutzmann J, Petrovic A. Human alveolar bone turn-over rate: a quantitative study of the spontaneous and therapeutically induced variations. In: Mc Namara JA Jr, Ribbens KA, eds. *Malocclusion and the Periodontium.* Monograph 15, Craniofacial Growth Series. Ann Arbor, Mich: University of Michigan; 1984:185–210.
23. Baccetti T, Franchi L, McNamara JA Jr. An improved version of the cervical vertebral maturation (CVM) method for the assessment of mandibular growth. *Angle Orthod.* 2002; 72:316–323.
24. McNamara JA Jr, Howe RP, Dischinger TG. A comparison of the Herbst and Fränkel appliances in the treatment of Class II malocclusion. *Am J Orthod Dentofacial Orthop.* 1990;98:134–144.
25. Westwood P, McNamara JA Jr, Baccetti T, Franchi L, Sarver DM. Long-term effects of Class III treatment with rapid maxillary expansion and facemask therapy followed by fixed appliances. *Am J Orthod Dentofacial Orthop.* 2003;123: 306–320.
26. Tollaro I, Baccetti T, Franchi L. Mandibular skeletal changes induced by early functional treatment of Class III malocclusion: a superimposition study. *Am J Orthod Dentofacial Orthop.* 1995;108:525–532.

27. Franchi L, Baccetti T, McNamara JA Jr. Treatment and posttreatment effects of acrylic splint Herbst appliance therapy. *Am J Orthod Dentofacial Orthop.* 1999;115:429–438.
28. Melsen B. The cranial base. *Acta Odontol Scand.* 1974;32(suppl):62.
29. Ødegaard J. Growth of the mandible studied with the aid of metal implant. *Am J Orthod Dentofacial Orthop.* 1970;67:145–157.
30. Skieller V, Björk A, Linde-Hansen T. Prediction of mandibular growth rotation evaluated from a longitudinal implant sample. *Am J Orthod.* 1984;86:359–370.
31. Dahlberg G. *Statistical Methods for Medical and Biological Students.* New York, NY: Interscience; 1940.
32. Alexander SA, Swerdloff M. Identification and localization of a mucopolisaccharidase in human deciduous teeth. *J Dent Res.* 1980;59:594–601.
33. Mancini G, Francini E, Vichi M, Tollaro I, Romagnoli P. Primary tooth ankylosis: report of case with histological analysis. *ASDC J Dent Child.* 1995;62:215–219.
34. Lavergne J, Gasson N. Operational definitions of mandibular morphogenetic and positional rotations. *Scand J Dent Res.* 1977;85:185–192.
35. Ureles SD, Chrzan JM, Norton LA, Rossomando EF. A role for TNF in bone resorption of deciduous molars in human beings. *Am J Orthod Dentofacial Orthop.* 2000;118:196–202.