

Original Article

Thin-plate Spline Analysis of Craniofacial Growth in Class I and Class II Subjects

Lorenzo Franchi^a; Tiziano Baccetti^b; Franka Stahl^c; James A. McNamara Jr^d

ABSTRACT

Objective: To compare the craniofacial growth characteristics of untreated subjects with Class II division 1 malocclusion with those of subjects with normal (Class I) occlusion from the prepubertal through the postpubertal stages of development.

Materials and Methods: The Class II division 1 sample consisted of 17 subjects (11 boys and six girls). The Class I sample also consisted of 17 subjects (13 boys and four girls). Three craniofacial regions (cranial base, maxilla, and mandible) were analyzed on the lateral cephalograms of the subjects in both groups by means of thin-plate spline analysis at T1 (prepubertal) and T2 (postpubertal). Both cross-sectional and longitudinal comparisons were performed on both size and shape differences between the two groups.

Results: The results showed an increased cranial base angulation as a morphological feature of Class II malocclusion at the prepubertal developmental phase. Maxillary changes in either shape or size were not significant. Subjects with Class II malocclusion exhibited a significant deficiency in the size of the mandible at the completion of active craniofacial growth as compared with Class I subjects.

Conclusion: A significant deficiency in the size of the mandible became apparent in Class II subjects during the circumpubertal period and it was still present at the completion of active craniofacial growth.

KEY WORDS: Morphometrics; Thin-plate spline analysis; Normal craniofacial growth; Class II malocclusion; Cephalometrics

INTRODUCTION

In recent times, the issue of growth in Class II subjects has become particularly relevant because of the

^a Lecturer, Department of Orthodontics, The University of Florence, Florence, Italy; Thomas M. Graber Visiting Scholar, Department of Orthodontics and Pediatric Dentistry, School of Dentistry, The University of Michigan, Ann Arbor, Mich.

^b Assistant Professor, Department of Orthodontics, The University of Florence, Florence, Italy; Thomas M. Graber Visiting Scholar, Department of Orthodontics and Pediatric Dentistry, School of Dentistry, The University of Michigan, Ann Arbor, Mich.

^c Research Associate, Department of Orthodontics, The University of Rostock, Rostock, Germany.

^d Thomas M. and Doris Graber Endowed Professor of Dentistry, Department of Orthodontics and Pediatric Dentistry, School of Dentistry, and Research Professor, Center for Human Growth and Development, The University of Michigan, Ann Arbor, Mich.

Corresponding author: Dr Tiziano Baccetti, Department of Orthodontics, The University of Florence, Via del Ponte di Mezzo, 46-48, Florence, Italy 50127 (e-mail: t.baccetti@odonto.unifi.it)

Accepted: September 2006. Submitted: July 2006.

© 2007 by The EH Angle Education and Research Foundation, Inc.

increasing interest in optimizing treatment planning in dentofacial orthopedics. Two different study designs have been used previously to compare craniofacial growth changes between Class II subjects and subjects with normal occlusion by means of classical cephalometric investigations. Cross-sectional studies have investigated the data of large craniofacial databases to infer conclusions for growth changes in individuals with Class I and Class II malocclusions.¹⁻³ The most appropriate approach is the longitudinal analysis of the same subject over time.⁴⁻⁸

A recent study found that patterns of craniofacial growth in subjects with untreated Class II malocclusion essentially are similar to those observed in untreated subjects with normal occlusion, with the exception of significantly smaller increases in mandibular length.⁸ The deficiency in mandibular growth in Class II subjects is significant at the growth spurt (interval CS3–CS4 in cervical vertebral maturation), and it is maintained at a postpubertal observation (CS6). These results show that Class II dentoskeletal disharmony does not exhibit a tendency for self-correction along

with growth, in association with a worsening of the deficiency in mandibular dimensions.

New descriptive methods of shape and shape changes have been developed and implemented as major improvements when compared with conventional cephalometrics.^{9,10} Among these methods, Bookstein's innovations (tensor analysis, shape-coordinate analysis, thin-plate spline [TPS] analysis) have been used to investigate modifications in shape related both to facial growth and to treatment.¹¹⁻¹⁴

Shape and dimensions of craniofacial components on lateral cephalograms have been investigated by these types of morphometric approaches. Tensor analysis,¹⁵ shape-coordinate analysis,¹⁶ and TPS analysis¹⁷⁻²¹ have been applied to the study of growth changes in treated and untreated subjects with different types of malocclusions.

The literature lacks the morphometric evaluation of craniofacial growth differences between Class II division 1 and Class I subjects from a prepubertal through a postpubertal stage of skeletal maturity. It is the aim of the present study, therefore, to perform a longitudinal assessment of craniofacial features of untreated subjects with Class II division 1 malocclusion when compared with subjects with normal occlusion by means of the TPS method.

MATERIALS AND METHODS

The files of the University of Michigan Growth Study (UMGS, $n = 706$) and of the Denver Growth Study (DGS, $n = 155$) were searched for availability of longitudinal records of orthodontically untreated subjects with either Class II or Class I malocclusions. Lateral cephalograms of good quality at two developmental intervals (T1 and T2) corresponding, respectively, to a prepubertal stage of skeletal maturity (CS1) and to a postpubertal stage (CS6)²² had to be available for all selected subjects. The examined interval covers the entire circumpubertal period up to completion of active growth. All subjects were of European-American ancestry (Caucasian) and did not present with craniofacial abnormalities or tooth anomalies in number or eruption (supernumeraries, congenitally missing teeth, impacted canines).

Subjects with a Class II division 1 malocclusion were diagnosed according to the following signs at T1: full-cusp Class II molar relationship, excessive overjet (greater than 4 mm), and ANB angle greater than 3° . Subjects with Class I occlusion were selected according to the presence at T1 of Class I molar relationship, normal overjet (between 2 mm and 4 mm), and an ANB angle between 0° and 3° . All subjects in both groups presented with normal vertical relationships²³

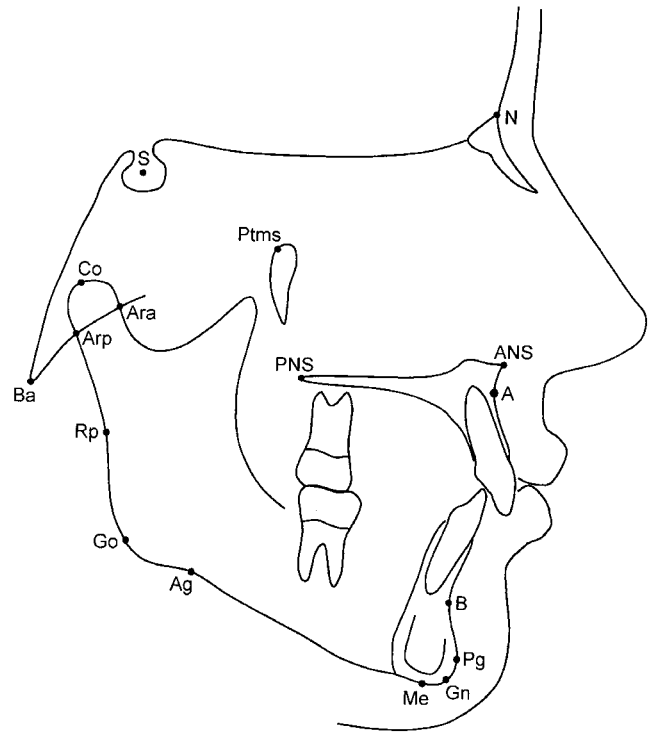


Figure 1. Cephalometric landmarks.

at T1 (FMA $23.6^\circ \pm 5.1^\circ$ in the Class II samples and $23.4^\circ \pm 4.0^\circ$ in the Class I samples).

The Class II division 1 sample consisted of 17 subjects (11 boys and six girls). The Class I sample also consisted of 17 subjects (13 boys and four girls). Mean ages at T1 was 10.1 years \pm 1.2 years for the Class I sample and 10.2 years \pm 1.3 years for the Class II sample.

TPS Analysis

Each lateral cephalogram was traced on 0.03-inch-thick frosted acetate by one investigator and checked by another investigator. To increase the reliability of the landmarks selected, the cephalograms were taped to a light box of uniform brightness in a darkened room. A cross-wires cursor was used to achieve digitization of landmarks. Landmarks for the description of the three craniofacial regions were identified and digitized by means of appropriate software (Dentofacial Planner, version 2.5, Toronto, Ontario, Canada) and a digitizing table (Numonics, Lansdale, Pa) (Figure 1): cranial base (three landmarks), maxilla (four landmarks), and mandible (10 landmarks). The definitions of the landmarks are reported in Table 1.

The magnification of the two data sets was different, with the lateral cephalograms from the UMGS showing a magnification of 12.9% and those from the DGS showing a magnification of 4%. Therefore, the lateral

Table 1. Definitions of Landmarks Used in This Study²³

Abbreviations	Cranial Base Landmarks
Ba	Basion (the most inferior-posterior point on the anterior margin of <i>foramen magnum</i>)
S	Sella (the center of the pituitary fossa of the sphenoid bone)
Na	Nasion (the junction of the frontonasal suture at the deepest point on the curve at the bridge of the nose)
Maxillary Landmarks	
Ptms	Pterygomaxillary fissure superior (the most superior-posterior point on the outline of the pterygomaxillary fissure)
PNS	Posterior nasal spine (the most posterior point on the bony hard palate)
ANS	Anterior nasal spine (the most anterior point on the bony hard palate)
A	Point A (the deepest point of the anterior surface of the maxilla)
Mandibular Landmarks	
Ara	Articulare anterior (intersection of the anterior contour of the condyle and the posterior cranial base)
Co	Condylion (most posterior-superior point of the condyle)
Arp	Articulare posterior (intersection of the posterior contour of the condyle and the posterior cranial base)
Rp	Ramal posterior (the deepest point of the curvature of the posterior surface of the mandibular ramus)
Go	Gonion (midpoint of the angle of the mandible)
Ag	Antegonial notch (the deepest point of the curvature of the lower surface of the mandibular body in the gonial region)
Me	Menton (the most inferior point on the symphyseal outline)
Gn	Gnathion (the most anterior-inferior point on the contour of the bony chin symphysis)
Pg	Pogonion (the most anterior point on the contour of the bony chin)
B	Point B (the deepest point of the anterior surface of the symphyseal outline of the mandible)

cephalograms from the two growth studies were corrected to match an 8% enlargement factor.

TPS software (tpsRegr, version 1.31, Ecology & Evolution, SUNY, Stonybrook, NY) computed the orthogonal least-squares Procrustes average configuration of craniofacial landmarks in both Class I and Class II subjects at T1 and T2 by using the generalized orthogonal least-squares procedures described in Rohlf and Slice.¹¹ Average configurations were calculated for three different craniofacial regions. The average configurations for the three craniofacial regions were subjected to TPS analysis by means of cross-sectional and longitudinal comparisons:

- Cross-sectional comparisons: Class I sample vs Class II sample at T1; Class I sample vs Class II sample at T2.
- Longitudinal comparisons: Class I sample at T1 vs Class I sample at T2; Class II sample at T1 vs Class II sample at T2.

Statistical analysis of shape differences was performed by means of permutation tests with 1000 random permutations on Wilks lambda statistics. Permutation tests were carried out because most landmarks slide along curves when shape changes are analyzed.

Centroid size was used as the measure of the geometric size of each craniofacial region in all subjects and was calculated as the square root of the sum of the squared distances from each landmark to the centroid of each specimen's configuration of landmarks.⁹ Differences in size at the two developmental phases (T1 through T2) were tested by means of Mann-Whitney *U*-tests ($P < .05$) for the cross-sectional comparisons and by means of Wilcoxon tests ($P < .05$) for the longitudinal comparisons. Statistical computations for centroid size analysis were performed with computer software (SPSS, Release 6.1.3, SPSS Inc, Chicago, Ill). For those growth intervals showing significant shape differences, a test for allometry checking for shape depending on size was carried out (tpsRegr, version 1.31, Ecology & Evolution).

Method error in landmark identification is reported elsewhere.¹⁶ The assessment of the stages in cervical vertebral maturation²² on lateral cephalograms for each subject was performed by one investigator and then verified by a second investigator. Any disagreements were resolved to the satisfaction of both observers.

RESULTS

Cranial Base Region

The cranial base showed a significant difference in shape in the Class II sample with respect to the Class I sample at T1 with a significant extension in a posterior direction in the region of point Ba and a vertical compression in the region of point S (Figure 2A). The difference in centroid size was not significant (Table 2), as well as the test for allometry. At T2, shape differences in the cranial base configuration between the two groups were no longer found (Figure 2B), and size differences were not significant either (Table 2).

The longitudinal changes in the shape of the cranial base from T1 through T2 were not significant either in the Class I or in the Class II sample (Figure 2C,D). On the other hand, differences in centroid size changes were significant for both samples ($P < .05$) (Table 2).

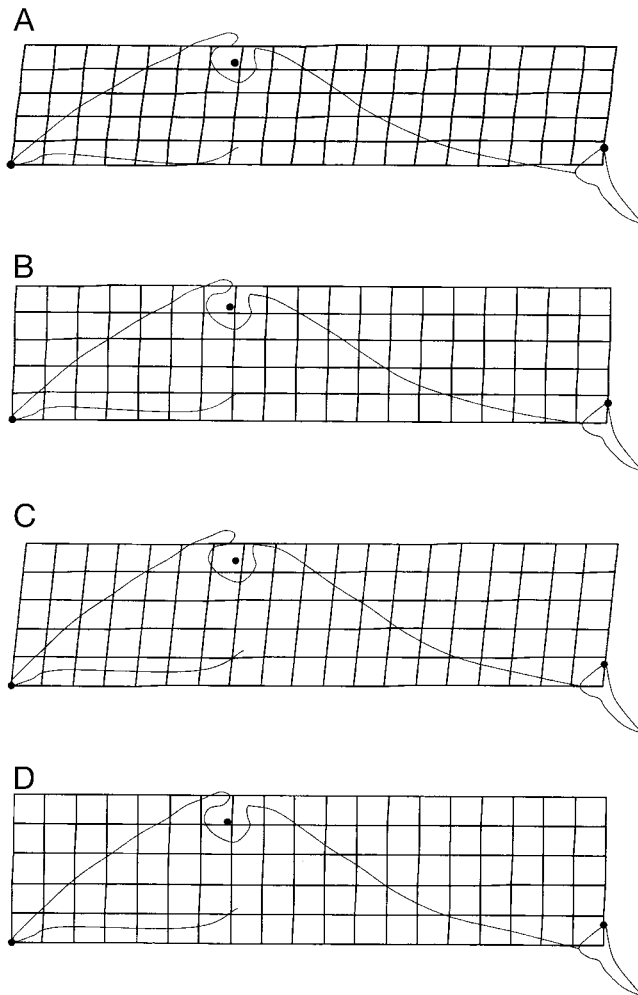


Figure 2. Cranial base region. (A) Thin-plate spline (TPS) graphical display for the Class I vs Class II comparison at T1 (magnification factor 6 \times). (B) TPS graphical display for the Class I vs Class II comparison at T2 (magnification factor 6 \times). (C) TPS graphical display for the Class I at T1 vs Class I at T2 (magnification factor 6 \times). (D) TPS graphical display for the Class II at T1 vs Class II at T2 (magnification factor 6 \times).

Maxillary Region

The average configurations of the maxilla did not show significant differences in either shape (Figure 3A,B) or size (Table 2) between Class II and Class I subjects at the cross-sectional evaluation at T1 and at T2.

The longitudinal changes in the shape of the maxilla from T1 through T2 were not significant either in the Class I or in the Class II sample (Figure 3C,D), whereas differences in centroid size changes were significant in both the Class II sample ($P < .05$) and the Class I sample ($P < .01$) (Table 2).

Mandibular Region

At T1, there were no significant differences in the shape of the mandible between the two examined

Table 2. Results of Cross-sectional and Longitudinal Comparisons of Centroid Size (in Millimeters)^a

Craniofacial Region	Mean	SD	Mean	SD	P
Cranial base					
Class I vs Class II at T1	77.5	5.4	77.9	6.0	NS
Class I vs Class II at T2	83.5	5.9	83.8	6.5	NS
Class I at T1 vs Class I at T2	77.5	5.4	83.5	5.9	*
Class II at T1 vs Class II at T2	77.9	6.0	83.8	6.5	*
Maxilla					
Class I vs Class II at T1	56.3	3.7	57.0	4.9	NS
Class I vs Class II at T2	61.3	4.4	62.3	5.3	NS
Class I at T1 vs Class I at T2	56.3	3.7	61.3	4.4	**
Class II at T1 vs Class II at T2	57.0	4.9	62.3	5.3	*
Mandible					
Class I vs Class II at T1	146.3	8.9	141.1	9.8	NS
Class I vs Class II at T2	168.0	9.0	159.5	11.1	*
Class I at T1 vs Class I at T2	146.3	8.9	168.0	9.0	**
Class II at T1 vs Class II at T2	141.1	9.8	159.5	11.1	**

^a SD indicates standard deviation; NS, not significant; * $P < .05$; ** $P < .01$.

groups (Figure 4A), and the difference in average centroid size was not significant either (Table 2). At T2, though not statistically significant, a horizontal compression in the gonial region of the mandibular configuration was observed in the Class II subjects with respect to the Class I subjects (Figure 4B). A significant difference in centroid size of the mandible became apparent at T2 with a smaller average value for the Class II group (Table 2).

The longitudinal changes in the shape of the mandible in both the Class I and Class II samples showed significant T1-T2 differences that consisted of a horizontal compression in the region of the gonial angle (Figure 4C,D). These significant changes in shape were associated with highly significant differences in centroid size changes for both samples ($P < .01$) (Table 2). Allometry was also significant for both the Class I sample ($F = 8.22$; $P < .01$) and the Class II sample ($F = 5.61$; $P < .01$), thus indicating dependence of shape differences on size differences.

DISCUSSION

Although the Class II division 1 malocclusion represents one of the most prevalent orthodontic problems, very few investigations have analyzed the growth patterns of individuals with both a Class II molar relationship and an excessive overjet. This information is essential to quantify expectations of growth in patients observed at an early developmental phase, as well as for the evaluation of treatment results in growing patients. As a matter of fact, only four major longitudinal studies have described the growth changes in the dentofacial region of orthodontically untreated Class II sample when compared with untreated samples with normal occlusion.⁵⁻⁸ The main outcome

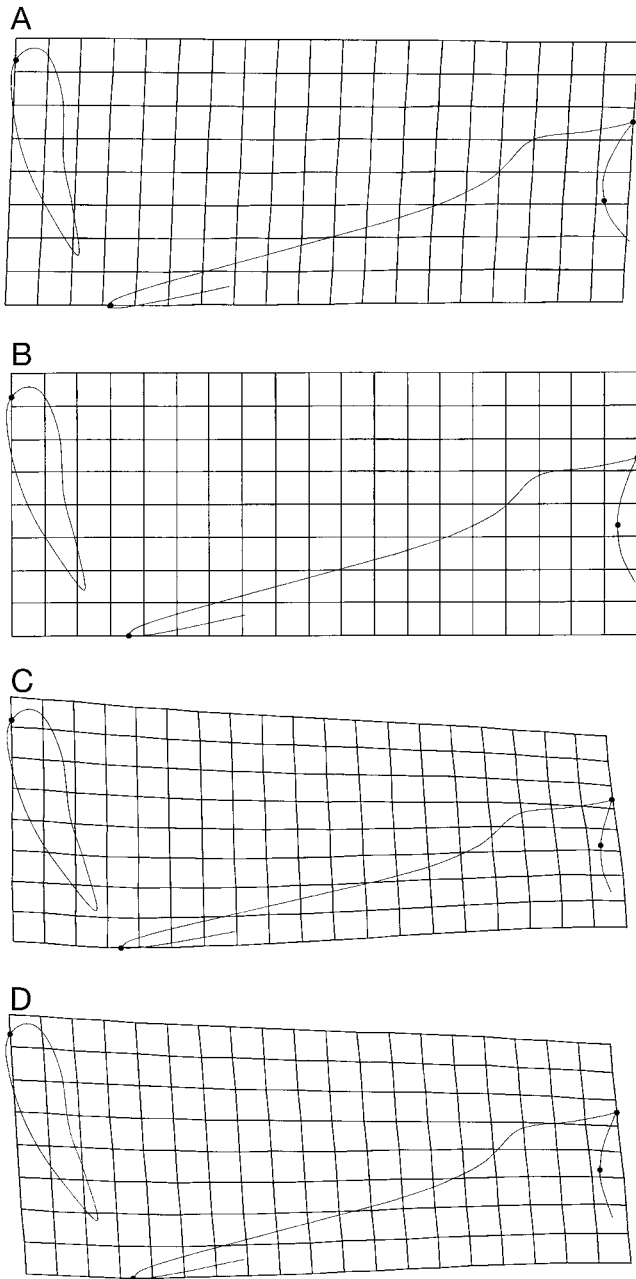


Figure 3. Maxillary region. (A) Thin-plate spline (TPS) graphical display for the Class I vs Class II comparison at T1 (magnification factor 3×). (B) TPS graphical display for the Class I vs Class II comparison at T2 (magnification factor 3×). (C) TPS graphical display for the Class I at T1 vs Class I at T2 (magnification factor 3×). (D) TPS graphical display for the Class II at T1 vs Class II at T2 (magnification factor 3×).

of these studies, with the exception of the study by Bishara et al,⁶ consisted of the evidence of a significant deficiency in mandibular growth in Class II subjects with respect to subjects with normal occlusion. Three⁵⁻⁷ of these four studies, however, did not take into consideration the skeletal maturity of the examined subjects, and all four studies used conventional

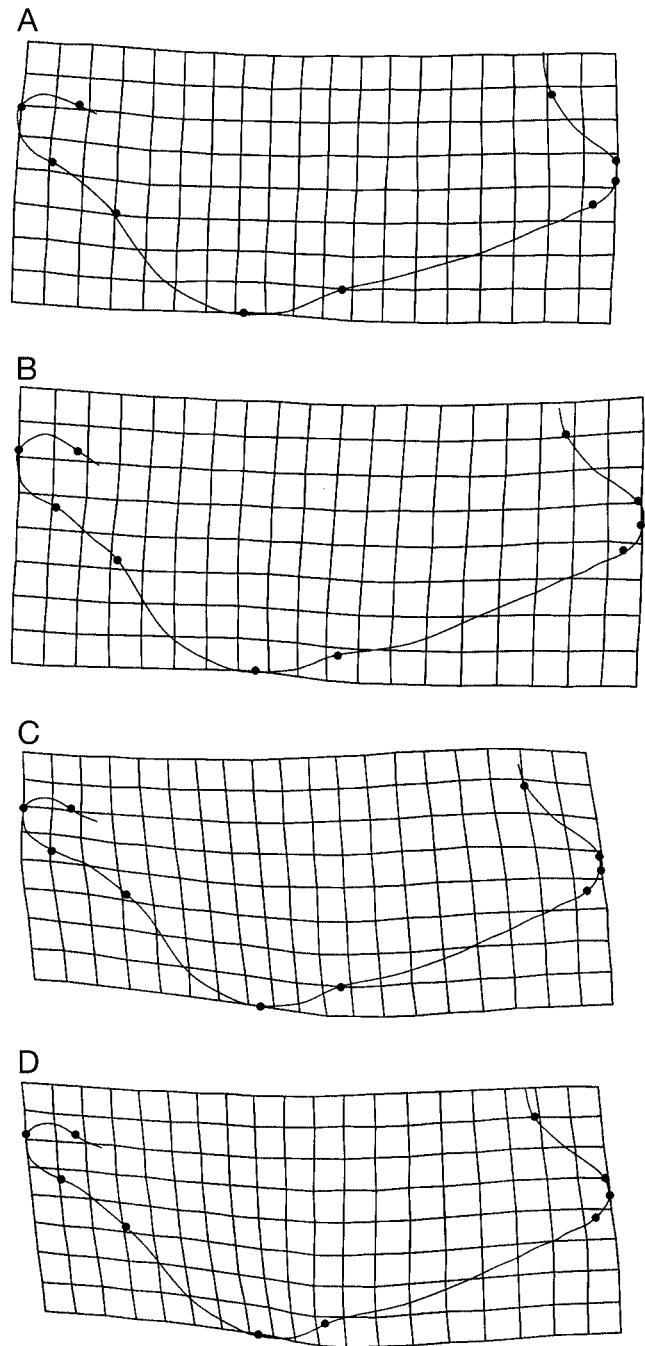


Figure 4. Mandibular region. (A) Thin-plate spline (TPS) graphical display for the Class I vs Class II comparison at T1 (magnification factor 3×). (B) TPS graphical display for the Class I vs Class II comparison at T2 (magnification factor 3×). (C) TPS graphical display for the Class I at T1 vs Class I at T2 (magnification factor 3×). (D) TPS graphical display for the Class II at T1 vs Class II at T2 (magnification factor 3×).

cephalometric analysis for the description of growth changes.

The aim of the current study was to analyze the craniofacial growth changes in untreated subjects with Class II malocclusion with those in subjects with nor-

mal occlusion from the prepubertal through the postpubertal stages of development with the use of a reliable morphometric analysis (TPS).

At the beginning of the observation period (T1), the Class II subjects were characterized by significant shape differences in the cranial base configuration with respect to Class I subjects. The Class II sample, therefore, exhibited a more obtuse cranial base angle when compared with subjects with normal occlusion. This finding is in agreement with previous reports by several authors who found that, during the early developmental phases, Class II malocclusion is significantly associated with the presence of an obtuse cranial base angulation.^{5,8,12,13} No differences in the average configurations of the maxilla or the mandible were present at T1 between Class II and Class I subjects.

The analysis of the longitudinal morphological changes revealed significant differences for the shape of the mandible in both the Class I and II samples associated with significant differences in centroid size that reflected growth in this craniofacial region. The shape change in both groups consisted of a horizontal compression in the region of the gonial angle that can be interpreted as a morphological rotation of the mandible in an anterior direction. This growth modification, defined as "anterior morphogenetic rotation" of the mandible,¹⁴ has been indicated as a biological mechanism aimed to dissipate excessive mandibular growth increments in relation to the maxilla and to compensate for the major increments in mandibular size during the circumpubertal period. Similar findings were reported in a previous morphometric study²⁰ that reported significant anterior morphogenetic rotation in the mandible at the pubertal growth spurt (CS3–CS4) in a longitudinal sample of subjects with normal occlusion.

The change in centroid size of the mandible, though significant in both longitudinal samples examined in the present study, presented with a significantly smaller value for the Class II sample. This outcome confirms previous data^{5,7,8} that demonstrated a significant growth deficiency of the mandible in growing subjects. No significant differences in shape between Class II and Class I samples were found for either the cranial base or the maxillary regions in the transition from a prepubertal observation to a postpubertal observation. The significant differences for the centroid size changes were significant for both the cranial base and the maxillary regions as a result of physiological growth.

At the time of final observation (T2, at the completion of active growth) neither shape nor size differences in any of the three examined craniofacial regions could be detected between the two samples. The only exception was represented by the size of the mandible that was significantly smaller in the Class II sample.

Once again this result emphasizes the role of mandibular deficiency within the growth features that characterize subjects with a Class II division 1 malocclusion.

CONCLUSIONS

- An extension of the posterior portion of the cranial base in relation to the anterior portion of the cranial base (increased cranial base angulation) is a morphological feature of Class II malocclusion at a prepubertal developmental phase.
- Maxillary changes in either shape or size were not significant.
- A significant deficiency in the size of the mandible became apparent in subjects with Class II malocclusion at the completion of active craniofacial growth.

ACKNOWLEDGMENTS

This research was financially supported by the Max-Kade-Foundation and the German Society of Orthodontics. Additional support was obtained through the Thomas M. and Doris Graber Endowed Professorship by the University of Michigan, Ann Arbor, Mich.

REFERENCES

1. McNamara JA Jr. Components of Class II malocclusion in children 8–10 years of age. *Angle Orthod.* 1981;51:177–202.
2. Anderson DL, Popovich F. Lower cranial height vs craniofacial dimensions in Angle Class II malocclusion. *Angle Orthod.* 1983;53:253–260.
3. Riesmeijer AM, Prah-Andersen B, Mascarenhas AK, Joo BH, Vig KW. A comparison of craniofacial Class I and Class II growth patterns. *Am J Orthod Dentofacial Orthop.* 2004;125:463–471.
4. Buschang PH, Tanguay R, Turkewicz J, Demirjian A, La Palme L. A polynomial approach to craniofacial growth: description and comparison of adolescent males with normal occlusion and those with untreated Class II malocclusion. *Am J Orthod Dentofacial Orthop.* 1986;90:437–442.
5. Kerr WJ, Hirst D. Craniofacial characteristics of subjects with normal and postnormal occlusions—a longitudinal study. *Am J Orthod Dentofacial Orthop.* 1987;92:207–212.
6. Bishara SE, Jakobsen JR, Vorhies B, Bayati P. Changes in dentofacial structures in untreated Class II division 1 and normal subjects: a longitudinal study. *Angle Orthod.* 1997;67:55–66.
7. Ngan PW, Byczek E, Scheick J. Longitudinal evaluation of growth changes in Class II division 1 subjects. *Semin Orthod.* 1997;3:222–231.
8. Stahl F, Baccetti T, Franchi L, McNamara JA Jr. Longitudinal growth changes in untreated subjects with Class II and Class I malocclusion. *Am J Orthod Dentofacial Orthop.* In press.
9. Bookstein FL. *Morphometrics Tools for Landmark Data.* New York, NY: Cambridge University Press; 1991.
10. Bookstein FL. On the cephalometrics of skeletal change. *Am J Orthod.* 1982;82:177–182.
11. Rohlf FJ, Slice DE. Extensions of the Procrustes method for the optimal superimposition of landmarks. *Syst Zool.* 1990;39:40–59.

12. Droel R, Isaacson RJ. Some relationships between the glenoid fossa position and various skeletal discrepancies. *Am J Orthod.* 1972;61:64–78.
13. Baccetti T, Antonini A, Franchi L, Tonti M, Tollaro I. Glenoid fossa position in different facial types: a cephalometric study. *Br J Orthod.* 1997;24:55–59.
14. Lavergne J, Gasson N. Operational definitions of mandibular morphogenetic and positional rotations. *Scand J Dent Res.* 1977;85:185–192.
15. McNamara JA Jr, Bookstein FL, Shaughnessy TG. Skeletal and dental changes following functional regulator therapy on Class II patients. *Am J Orthod.* 1985;88:91–110.
16. Baccetti T, Franchi L. Shape-coordinate and tensor analysis of skeletal changes in children with treated Class III malocclusion. *Am J Orthod Dentofacial Orthop.* 1997;112:622–633.
17. Singh GD, McNamara JA Jr, Lozanoff S. Spline analysis of the mandible in subjects with Class III malocclusion. *Arch Oral Biol.* 1997;42:345–353.
18. Baccetti T, Franchi L, McNamara JA Jr. Thin-plate spline analysis of treatment effects of rapid maxillary expansion and facial mask therapy in early Class III malocclusion. *Eur J Orthod.* 1999;21:275–281.
19. Lux CJ, Rubel J, Starke J, Conradt C, Stellzig PA, Komposch PG. Effects of early activator treatment in patients with Class II malocclusion evaluated by thin-plate spline analysis. *Angle Orthod.* 2001;71:120–126.
20. Franchi L, Baccetti T, McNamara JA Jr. Thin-plate spline analysis of mandibular growth. *Angle Orthod.* 2001;71:83–92.
21. Alarashi M, Franchi L, Marinelli A, Defraia E. Morphometric analysis of the transverse dentoskeletal features of Class II malocclusion in the mixed dentition. *Angle Orthod.* 2003;73:21–25.
22. Baccetti T, Franchi L, McNamara JA Jr. The cervical vertebral maturation (CVM) method for the assessment of optimal treatment timing in dentofacial orthopedics. *Semin Orthod.* 2005;11:119–129.
23. Riolo ML, Moyers RE, McNamara JA Jr, Hunter WS. *An Atlas of Craniofacial Growth: Cephalometric Standards from The University School Growth Study, The University of Michigan.* Monograph 2, Craniofacial Growth Series, Center for Human Growth and Development. Ann Arbor, Mich: The University of Michigan; 1974.