



UNIVERSITÀ
DEGLI STUDI
FIRENZE

FLORE
Repository istituzionale dell'Università degli Studi di
Firenze

**Usefulness of ST segment analysis to predict infarct size and functional outcome
in acute myocardial infarction treated with**

Questa è la Versione finale referata (Post print/Accepted manuscript) della seguente pubblicazione:

Original Citation:

Usefulness of ST segment analysis to predict infarct size and functional outcome in acute myocardial infarction treated with primary coronary intervention and adjunctive abciximab therapy / SCIAGRA' R.; PARODI G.; MIGLIORINI A.; VALENTI R.; ANTONIUCCI D.; A. PUPI; B. SOTGIA. - In: THE AMERICAN JOURNAL OF CARDIOLOGY. - ISSN 0002-9149. - STAMPA. - 97(2006), pp. 48-54. [10.1016/j.amjcard.2005.07.109]

Availability:

This version is available at: 2158/309689 since:

Published version:

DOI: 10.1016/j.amjcard.2005.07.109

Terms of use:

Open Access

La pubblicazione è resa disponibile sotto le norme e i termini della licenza di deposito, secondo quanto stabilito dalla Policy per l'accesso aperto dell'Università degli Studi di Firenze (<https://www.sba.unifi.it/upload/policy-oa-2016-1.pdf>)

Publisher copyright claim:

(Article begins on next page)

ST-Segment Analysis to Predict Infarct Size and Functional Outcome in Acute Myocardial Infarction Treated With Primary Coronary Intervention and Adjunctive *Abciximab* Therapy

Roberto Sciagrà, MD^{a,*}, Guido Parodi, MD, PhD^b, Angela Migliorini, MD^b, Renato Valenti, MD^b, David Antoniucci, MD^b, Barbara Sotgia, MD^a, and Alberto Pupi, MD^a

ST-segment resolution is used to classify the response to reperfusion therapy in acute myocardial infarction, but the possibility to predict outcome in individual patients is unclear, particularly in the setting of primary percutaneous coronary intervention (PCI) and abciximab therapy. We studied 213 patients who underwent successful revascularization with PCI. Maximal ST-segment elevation was measured before and 30 minutes after PCI. Patient outcome was defined on the basis of infarct size and left ventricular ejection fraction (EF) as derived from gated single-photon emission computed tomography that was acquired 1 month after infarction. Patients who had $\geq 50\%$ ST resolution showed a smaller infarct ($15.1 \pm 13.6\%$ vs $19.9 \pm 15.7\%$, $p < 0.05$) but not a higher left ventricular EF ($48.7 \pm 12.3\%$ vs $45.2 \pm 11.8\%$) than did patients who had $< 50\%$ resolution. According to cluster analysis of infarct size and left ventricular EF, 132 patients had favorable outcome (central values: infarct size 7.5%, left ventricular EF 55%) and 81 did not (central values: infarct size 30%, left ventricular EF 36%). Using receiver-operating characteristic curve analysis, the optimal ST-resolution cutoff was $> 60\%$, with 77% sensitivity and 51% specificity for predicting favorable outcome. ST-segment elevation ≤ 4.5 mV before PCI was 80% sensitive and 48% specific, and ST-segment elevation ≤ 1 mV after PCI was 74% sensitive and 60% specific for predicting favorable outcome. In conclusion, in the setting of primary PCI and abciximab therapy, ST-segment elevation resolution requires a high threshold ($> 60\%$) to effectively classify patients; the capability of ST-segment analysis to predict patient outcome is limited, with ST-segment elevation after PCI showing the best compromise between sensitivity and specificity. © 2006 Elsevier Inc. All rights reserved. (Am J Cardiol 2006;97:48–54)

Early decrease of ST-segment elevation has been demonstrated to be a marker of myocardial tissue level reperfusion and thus of revascularization success.^{1–4} The prognostic implications of this marker in patients who have acute myocardial infarction are known.^{1–3,5} Other studies have suggested a relation between ST-segment resolution and infarct size and/or postinfarction left ventricular function, but the usefulness of ST-segment changes for predicting infarct extent and severity in the patient population has been questioned.^{6–10} In recent years, important advances in the treatment of infarction have been introduced and an aggressive therapy, based on direct percutaneous coronary intervention (PCI) with stenting plus abciximab administration, is currently the most advanced approach to infarct treatment.^{11–14} Although ST-segment resolution has been used to test these new therapeutic strategies, its relation to objective

parameters of treatment results in the patient population has not been examined. This study evaluated the accuracy of the simplest and quickest approach to ST-segment elevation analysis, i.e., single-lead analysis before and 30 minutes after PCI,⁴ in characterizing the outcome of patients with acute myocardial infarction and who underwent early PCI with direct stenting and adjunctive abciximab therapy, using as the reference 1-month scintigraphic infarct size and left ventricular ejection fraction (EF).

Methods

Study patients: Between January 2001 and September 2004, 213 consecutive patients (155 men; mean 65 ± 12 years of age) who had acute myocardial infarction and underwent primary PCI with direct stenting and adjunctive abciximab therapy were studied at 1 month after the index infarction for the assessment of myocardial perfusion and left ventricular function with gated single-photon emission computed tomography. Inclusion criteria were chest pain that persisted > 30 minutes and was associated with ST-segment elevation ≥ 0.1 mV in ≥ 2 contiguous electrocardiographic leads, admission within 6 hours of symptom

The ^aNuclear Medicine Unit, Department of Clinical Physiopathology, University of Florence, and the ^bDivision of Cardiology, Careggi Hospital, Florence, Italy. Manuscript received June 13, 2005; revised manuscript received and accepted July 26, 2005.

* Corresponding author: Tel: 39-055-794-7682; fax: 39-055-422-4392.

E-mail address: r.sciagra@dfc.unifi.it (R. Sciagrà).

Table 1
Baseline characteristics of the patient population

	All Patients (n = 213)	ST Resolution \geq 50% (n = 171)	ST Resolution <50% (n = 42)	p Value
Age (yrs)	65 \pm 12	69 \pm 14	64 \pm 12	<0.05
Men	155 (73%)	124 (73%)	31 (74%)	NS
Systemic hypertension	93 (44%)	65 (38%)	28 (66%)	NS
Total serum cholesterol >200 mg/dl	71 (33%)	57 (33%)	14 (33%)	NS
Smoker	73 (34%)	58 (34%)	15 (36%)	NS
Diabetes mellitus	28 (13%)	19 (11%)	9 (22%)	NS
Anterior wall acute myocardial infarction	89 (42%)	66 (39%)	23 (55%)	0.05
Cardiogenic shock	6 (3%)	4 (2%)	2 (5%)	NS
Killip's class (median)	1.3 \pm 0.8 (1)	1.3 \pm 0.7 (1)	1.3 \pm 0.8 (1)	NS

Table 2
Angiographic findings

	All Patients (n = 213)	ST Resolution \geq 50% (n = 171)	ST Resolution <50% (n = 42)	p Value
Symptom onset to reperfusion (min)	180 \pm 110	174 \pm 96	208 \pm 154	NS
Infarct-related coronary artery				
Left anterior descending	89 (42%)	66 (39%)	23 (55%)	0.05
Right	95 (45%)	81 (47%)	14 (33%)	NS
Left circumflex	28 (13%)	23 (14%)	5 (12%)	NS
Multivessel coronary disease	104 (49%)	80 (47%)	24 (57%)	NS
Preprocedural TIMI grade flow				
0–1	161 (76%)	127 (74%)	34 (81%)	NS
2	34 (16%)	28 (17%)	6 (14%)	NS
3	18 (8%)	16 (9%)	2 (5%)	NS

TIMI = Thrombolysis In Myocardial Infarction.

onset, and successful revascularization (defined as restoration of Thrombolysis In Myocardial Infarction¹⁵ grade 3 flow and residual stenosis <30%). Exclusion criteria were previous myocardial infarction, conditions that precluded evaluation of ST-segment changes on electrocardiography, previous administration of fibrinolytic or abciximab therapy, history of bleeding diathesis or allergy to abciximab, major surgery within 15 days, and inability to obtain informed consent.

PCI and patient treatment: Before catheterization, patients received 325 mg of aspirin orally or 250 mg intravenously. All patients with a vessel reference diameter \geq 2.5 mm were eligible for stenting. Coronary stenting was performed directly or with predilation at the discretion of the operator. After coronary angiography, patients received abciximab immediately before the procedure as a bolus of 0.25 mg/kg of body weight followed by a 12-hour infusion at a rate of 0.125 μ g/kg/min. Heparin was given as an initial bolus of 70 U/kg, and additional boluses were administered during the procedure to achieve an activated clotting time of 200 to 300 seconds. Immediately after the procedure, patients received 500 mg of ticlopidine or 300 mg of clopidogrel. Patients were routinely treated with aspirin (325 mg/day indefinitely) and with ticlopidine (500 mg/day for 1 month) or clopidogrel (75 mg/day for 1 month).

Electrocardiographic analysis: Standard 12-lead electrocardiograms were registered before PCI and within 30

minutes of the procedure using a speed of 25 mm/s and amplitude of 10 mm/mV. An observer who was blinded to the patients' clinical data evaluated the electrocardiograms. The single lead with the most prominent ST-segment elevation before PCI was identified, and ST-segment elevation was measured at 60 ms after the J point in 3 successive QRS-T complexes. Resolution in ST-segment elevation was defined at 30 minutes after infarct artery recanalization.⁴ Degree of resolution was prospectively categorized by 2 different criteria. A dichotomous classification was performed with a \geq 50% threshold to define ST-segment elevation resolution as present or absent.^{1,4} Alternatively, resolution was defined as complete (\geq 70% decrease in ST-segment elevation), partial (30% to 70%), or absent (\leq 30%).³

Gated single-photon emission computed tomography: Gated single-photon emission computed tomographic (SPECT) acquisition began 60 minutes after injection of technetium-99m sestamibi (740 MBq) using a double-headed camera that was equipped with high-resolution collimators, 180° rotation arc, 32 projections, 8-frames/heart cycle, and 64 \times 64 matrixes. Perfusion defects were quantified as percent left ventricular wall, with the defect threshold set at 60% of peak uptake.^{16,17} Left ventricular end-diastolic and end-systolic volumes were calculated with the QGS program (Cedar Sinai Medical Center, Los Angeles, California) and

Table 3

Correlations between ST-segment parameters and one-month gated single-photon emission computed tomographic data

	Infarct Size	Left Ventricular EF
ST-segment elevation before PCI (mV)	$y = 2.02x + 8.02$ $r = 0.33, p < 0.000001$ SEE = 13.3	$y = -1.99x + 56$ $r = -0.38, p < 0.0000001$ SEE = 11.4
ST-segment elevation 30 min after PCI (mV)	$y = 3.57x + 11.06$ $r = 0.39, p < 0.0000001$ SEE = 13.1	$y = -3x + 52.3$ $r = -0.38, p < 0.0000001$ SEE = 11.4
ST-segment elevation resolution (%)	$y = -0.14x + 25.3$ $r = -0.28, p < 0.00005$ SEE = 13.6	$y = 0.1x + 41.3$ $r = 0.23, p < 0.001$ SEE = 11.9

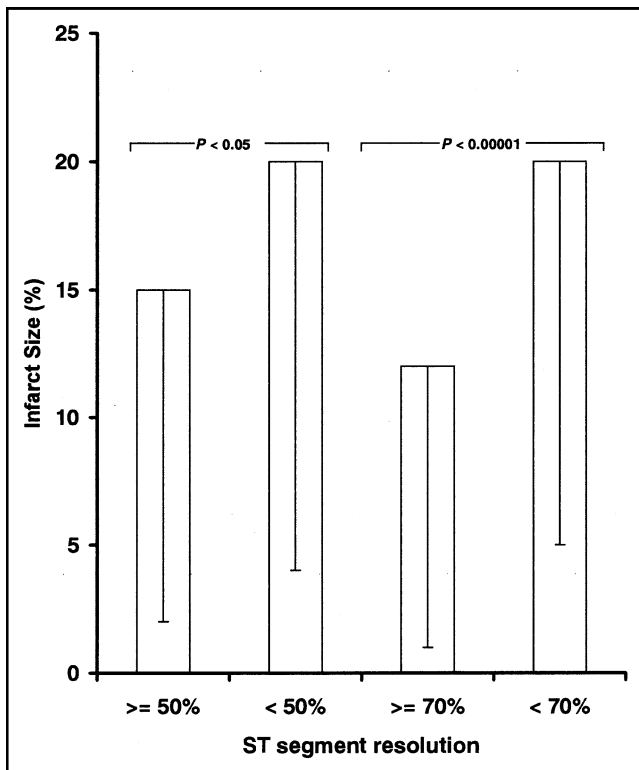


Figure 1. Bar graph of infarct size (percent left ventricular wall) in patients who had $\geq 50\%$ ST-segment elevation resolution versus that in those who had $< 50\%$ ST-segment resolution and in those who had complete ($\geq 70\%$) versus partial ($< 70\%$ and $> 30\%$) or absent ($\leq 30\%$) ST-segment elevation resolution.

EF was calculated from left ventricular volumes according to standard methods.¹⁸

Statistical analysis: Values are presented as mean \pm SD or as median and range, as appropriate. In the case of ordinal variables, the median is also indicated. Continuous variables were compared with 1-way analysis of variance with Tukey's post hoc test for multiple comparisons. Ordinal variables were compared with Kruskal-Wallis analysis of variance. Comparison of proportions was made with the chi-square test and Yates' correction, as appropriate. The relation between the ST-segment parameters of infarct size and left ventricular EF was made with Pearson's correlation

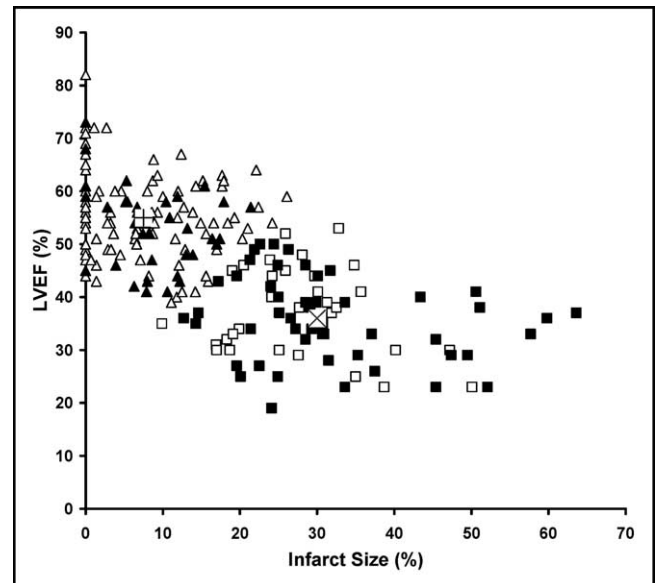


Figure 2. Scatterplot of infarct size (percent left ventricular wall) and left ventricular EF (LVEF) shows results of cluster analysis. Patients in cluster 1 (favorable outcome) are represented by *triangles* and those in cluster 2 (unfavorable outcome) by *squares*. Within each cluster, the *open symbols* indicate patients with ST-segment elevation after PCI ≤ 1 mV and the *solid symbols* indicate patients with ST-segment elevation after PCI > 1 mV. Centers of cluster 1 (+) and cluster 2 (x) are shown.

coefficient. To define outcome after reperfusion, scintigraphic infarct size and left ventricular EF were classified into 2 groups by using k-means cluster analysis. Patient classification after clustering was used as a reference for receiver-operating characteristic curve analysis of a ST segment and as a grouping factor for stepwise multivariate discriminant analysis of ST-segment parameters (ST elevation before and after PCI and ST-segment elevation resolution). A p value < 0.05 was considered statistically significant.

Results

Electrocardiographic findings: Table 1 presents baseline characteristics of the patient population and Table 2 lists the main angiographic findings. Before PCI ST-segment elevation was 1 to 15 mV (median 3.5). On the

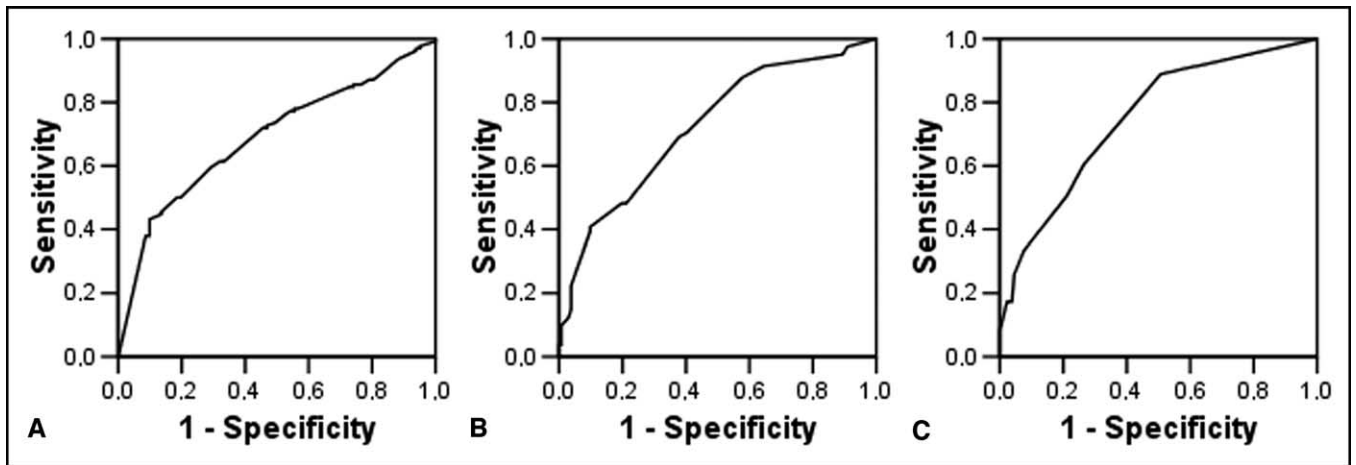


Figure 3. Receiver-operating characteristic curves of ST-segment resolution (A) and ST-segment elevation before PCI (B) and after PCI (C) that were constructed using patient classification according to cluster analysis as reference.

electrocardiogram that was registered 30 minutes after PCI, ST-segment elevation was 0 to 9 mV (median 1), with a ST-segment elevation resolution of $68 \pm 29\%$. A resolution $\geq 50\%$ was observed in 171 patients (80%). Complete resolution was registered in 107 patients (50%), partial in 89 (42%), and absent in 17 (8%).

Gated SPECT findings and ST-segment resolution: On the 1-month gated SPECT study, mean infarct size was $16 \pm 14\%$ (range 0% to 63%) and mean left ventricular EF was $48 \pm 12\%$ (range 19% to 82%). ST-segment elevation before and after PCI and ST-segment elevation resolution were significantly correlated with infarct size and left ventricular EF (Table 3). Patients who had $\geq 50\%$ ST-segment resolution showed a significantly smaller infarct ($15.1 \pm 13.6\%$ vs $19.9 \pm 15.7\%$, $p < 0.05$; Figure 1) but not a significantly higher left ventricular EF ($48.7 \pm 12.3\%$ vs $45.2 \pm 11.8\%$) than did patients who had $< 50\%$ resolution. Conversely, patients who had complete ST-segment elevation resolution had a significantly smaller infarct ($11.8 \pm 11.6\%$) than did patients who had partial ($20.4 \pm 15.1\%$, $p < 0.00005$) or absent ($20.5 \pm 15.7\%$, $p < 0.05$) ST-segment elevation resolution, whereas no significant difference was registered between patients who had partial resolution and those who had absent resolution (Figure 1). Left ventricular EF was significantly higher in patients who had complete ST-segment elevation resolution ($51.1 \pm 12.1\%$) than in those who had partial resolution ($44.6 \pm 10.9\%$, $p < 0.0005$), but, due to the large SD, this difference did not reach significance compared with patients who had absent resolution ($46.6 \pm 14.9\%$, $p = 0.17$). No difference was present between patients who had partial ST-segment elevation resolution and those who had absent resolution.

ST-segment changes and patient outcome: Cluster analysis of infarct size and left ventricular EF identified 2 clusters. The first cluster, which corresponded to a favorable PCI outcome, had as central values an infarct size of 7.5% and a left ventricular EF of 55%. The second

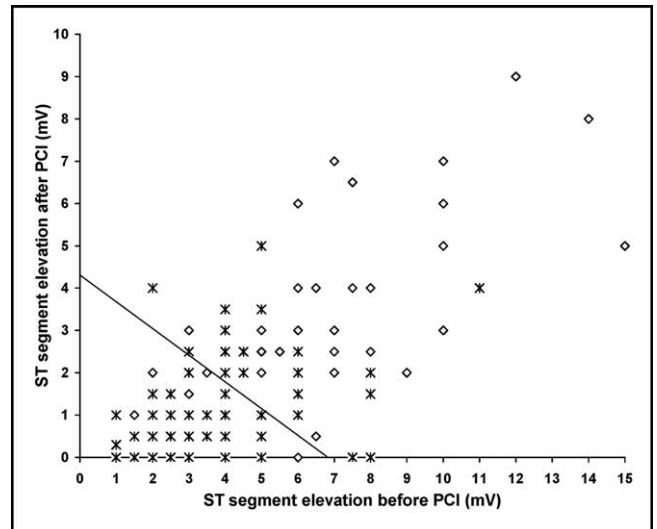


Figure 4. Scatterplot shows the relation between ST-segment resolution and ST-segment elevation after PCI in patients who had favorable outcome (asterisks) and those who had unfavorable outcome (diamonds) according to cluster analysis; the discriminant function (line) is shown.

cluster had as central values an infarct size of 30% and a left ventricular EF of 36% and indicated an unfavorable outcome. One hundred thirty-two patients were included in the first cluster and 81 in the second (Figure 2). Using this patient classification as a reference for receiver-operating characteristic curve analysis of percent ST-segment elevation resolution, the area under the curve was 0.69 (SE \pm 0.036; Figure 3). The optimal cut-off value of ST-segment elevation resolution was $> 60\%$, with 77% sensitivity and 51% specificity for predicting a favorable PCI outcome as defined by the result of cluster analysis. A ST-segment elevation ≤ 4.5 mV before PCI was 80% sensitive and 48% specific for predicting a favorable outcome, with an area under the curve of 0.72 (SE \pm 0.036; Figure 3). Similarly, a ST-segment eleva-

tion ≤ 1 mV after PCI was 74% sensitive and 60% specific, with an area under the curve of 0.75 (SE \pm 0.034; Figure 3).

Multivariate stepwise discriminant analysis selected ST elevation after PCI ($F = 11.4$, $p < 0.001$, standardized coefficient 0.68) and ST elevation before PCI ($F = 4.1$, $p < 0.05$, standardized coefficient 0.42) as variables to include in the discriminant function, which had a highly significant canonical correlation (canonical $R = 0.43$, $p < 0.000001$). The derived classification matrix after jack-knife cross validation correctly classified 107 of 132 patients in cluster 1 (81% sensitivity for a favorable outcome) and 42 of 81 in cluster 2 (52% specificity; Figure 4).

Discussion

In the thrombolytic era, ST-segment elevation resolution was considered a sign of successful recanalization, with $\sim 25\%$ of patients achieving complete resolution using streptokinase¹⁹ and up to 40% using tissue plasminogen activator.²⁰ Patients who had complete ST-segment elevation resolution had $>90\%$ likelihood of having a patent infarct-related artery.^{21,22} However, a large number of patients who had absent or partial ST-segment elevation resolution also had a patent infarct-related artery.^{21,22} In these patients, electrocardiographic findings depicted the status of microvascular perfusion because persistent ST-segment elevation indicates impaired microvascular perfusion in patients who have normal epicardial blood flow.^{23,24} In the current era of primary PCI for acute myocardial infarction, recanalization of the infarct-related artery is directly established, so the main role of analysis of ST-segment changes is to provide additional data about revascularization results in terms of effective reperfusion at the tissue level and of patient outcome.^{1,4}

The easiest approach to ST-segment analysis is to classify ST-segment elevation in broad categories and to include the patient in 1 of these. ST-segment resolution has frequently been classified as present or absent, with 50% as the cut-off value,^{1,4,9} but the possibility that this categorization is insufficient in patients who undergo PCI has been suggested.⁵ The results of our study confirm that, in the setting of direct PCI with abciximab therapy, this classification is no longer optimal. The proportion of patients who had $\geq 50\%$ resolution was similar to or even larger than that in previous studies,^{1,4} which was expected because successful coronary recanalization was always achieved and effective myocardial reperfusion was highly likely.⁵ Nevertheless, the 50% cutoff did not effectively classify patient outcome because, in addition to a just borderline significant difference in infarct size, the 2 groups did not differ significantly in terms of left ventricular EF. With regard to the other widely used classification of complete, partial, or absent ST-segment elevation resolution, with 70% and 30% thresholds,³ in our series, the first group showed a clearly

better outcome than did the other 2, which in turn did not differ significantly from each other. In practice, this implies that, in the setting of direct PCI with abciximab therapy partial ST-segment elevation resolution should be regarded more as a marker of unsuccessful myocardial reperfusion than as a sign of an intermediate result.

We also considered the possibility of using ST-segment data to predict patient outcome. Several studies consistently associated a more complete ST resolution with smaller infarct and increased left ventricular function.^{1,6–10,25} However, scanty data exist about the capability of ST-segment analysis to estimate the extent of myocardial damage in a patient. In 1 study that used scintigraphic infarct size as obtained with positron emission tomography in a small patient population that had been treated with thrombolysis or PCI, the results were rather disappointing, independently from the employed electrocardiographic criteria.¹⁰ Further, no data exist about the value of ST-segment analysis for predicting outcome of patients who undergo stenting and abciximab adjunctive therapy. The latter approach is associated with improved ST-segment resolution, probably because of increased microvascular and tissue level perfusion.^{26,27}

In the present study, we used 1-month gated single-photon emission computed tomography to objectively demonstrate patient outcome according to infarct size and left ventricular EF. We found a relatively low correlation between the ST-segment parameters, the infarct size, and the left ventricular EF. This precluded the use of electrocardiographic findings to estimate infarct size or left ventricular function. Therefore, ST-segment evaluation can be used just to categorize outcome as favorable or unfavorable.

To clarify whether the use of proper thresholding would increase the value of ST-segment analysis for this purpose over that of previously mentioned predefined arbitrary categories, we defined 2 groups of patients according to cluster analysis of infarct size and left ventricular EF; 1 group consisted of patients who had a favorable outcome (small infarct and normal left ventricular EF) and 1 consisted of those who had an ineffective revascularization result. Using this reference classification, we found that the optimal threshold value for ST-segment elevation resolution was $>60\%$, with a good sensitivity but a limited specificity for predicting effective revascularization.

We extended our analysis to other easily achievable ST-segment parameters, such as maximal ST-segment elevation in the lead that was used to explore the infarction before and after PCI.^{5,28,29} Although the value before PCI was even less specific than ST-segment elevation resolution, a postprocedural ST-segment elevation ≤ 1 mm was slightly less sensitive but much more specific than ST-segment resolution because it produced the largest area under the receiver-operating characteristic curve. Therefore, a high degree of ST-segment elevation resolution (and possibly a complete resolution) remains a valuable predictor of effective reperfusion but does not exclude a relatively unfavorable outcome in terms of infarct size and left ventric-

ular EF. In contrast, maximal postprocedural ST-segment elevation seems to be a very accurate and easily measurable ST marker of favorable PCI outcome with small infarct and preserved left ventricular EF, as demonstrated in previous studies in patients who were treated with thrombolysis.^{28,29} The combined use of pre- and postprocedural ST-segment elevation, as suggested by multivariate discriminant analysis, achieves good sensitivity but is still affected by poor specificity.

Different limitations of the present study must be considered. Patient outcome was defined on the basis of 1 gated SPECT study after PCI. Lack of data about the initial risk area before PCI does not allow differentiating between a very successful reperfusion of a large infarction and a small infarction with limited PCI success because either will result in a final infarct size of limited extent.⁷ This could explain, at least in part, the low specificity of decreased ST-segment elevation and the relatively good performance of postprocedural ST-segment elevation. Further, the definition of favorable outcome with 1-month gated single-photon emission computed tomography can be criticized because each infarct size threshold (with the exception of a normal perfusion) is somewhat arbitrary. Similarly, normal left ventricular EF does not exclude some degree of functional impairment in a particular patient because no data were available about functional status before infarction, and we did not assess functional recovery.^{4,8} We used a very simple method to analyze ST-segment changes and more refined (and demanding) methods could have produced different results. However, the single-lead method has been extensively used and validated.^{4,5,28,29} Further, the use of a very early time point for postprocedural evaluation offers advantages in terms of decision making. Moreover, previous comparative studies failed to demonstrate a convincing superiority of more complex measurements.^{5,10,28,29}

- Matetzky S, Novikov M, Gruberg L, Freimark D, Feinberg M, Elian D, Novikov I, Di Segni E, Agranat O, Har-Zahav Y, et al. The significance of persistent ST elevation versus early resolution of ST segment elevation after primary PTCA. *J Am Coll Cardiol* 1999;34:1932–1938.
- de Lemos JA, Braunwald E. ST-segment resolution as a tool for assessing the efficacy of reperfusion therapy. *J Am Coll Cardiol* 2001;38:1283–1294.
- Schroeder R, Dissmann R, Bruggemann T, Wegscheider K, Linderer T, Tebbe U, Neuhaus KL. Extent of early ST segment elevation resolution: a simple but strong predictor of outcome in patients with acute myocardial infarction. *J Am Coll Cardiol* 1994;24:384–391.
- Santoro GM, Antonucci D, Valenti R, Bolognese L, Buonamici P, Trapani M, Boddi V, Fazzini PF. Rapid reduction of ST-segment elevation after successful direct angioplasty in acute myocardial infarction. *Am J Cardiol* 1997;80:685–689.
- McLaughlin MG, Stone GW, Aymong E, Gardner G, Mehran R, Lansky AJ, Grines CL, Tchong JE, Cox DA, Stuckey T, et al. Controlled Abciximab and Device Investigation to Lower Late Angioplasty Complications trial. Prognostic utility of comparative methods for assessment of ST-segment resolution after primary angioplasty for acute myocardial infarction: the Controlled Abciximab and Device Investigation to Lower Late Angioplasty Complications (CADILLAC) trial. *J Am Coll Cardiol* 2004;44:1215–1223.
- Angeja BG, Gunda M, Murphy SA, Sobel BE, Rundle AC, Syed M, Asfour A, Borzak S, Gourlay SG, Barron HV, et al. TIMI myocardial perfusion grade and ST segment resolution: association with infarct size as assessed by single photon emission computed tomography imaging. *Circulation* 2002;105:282–285.
- Dong J, Ndrepepa G, Schmitt C, Mehilli J, Schmieder S, Schwaiger M, Schomig A, Kastrati A. Early resolution of ST-segment elevation correlates with myocardial salvage assessed by Tc-99m sestamibi scintigraphy in patients with acute myocardial infarction after mechanical or thrombolytic reperfusion therapy. *Circulation* 2002;105:2946–2949.
- Nicolau JC, Maia LN, Vitola J, Vaz VD, Machado MN, Godoy MF, Giraldez RR, Ramires JA. ST-segment resolution and late (6-month) left ventricular remodeling after acute myocardial infarction. *Am J Cardiol* 2003;91:451–453.
- Feldman LJ, Coste P, Furber A, Dupouy P, Slama MS, Monassier JP, Tron C, Lafont A, Faraggi M, Le Guludec D, et al. FRENCH Optimal STenting-2 Invest. Incomplete resolution of ST-segment elevation is a marker of transient microcirculatory dysfunction after stenting for acute myocardial infarction. *Circulation* 2003;107:2684–2689.
- Desmet WJ, Mesotten LV, Maes AF, Heidbuchel HP, Mortelmans LA, Van de Werf FJ. Relation between different methods for analysing ST segment deviation and infarct size as assessed by positron emission tomography. *Heart* 2004;90:887–892.
- Zijlstra F, Hoorntje JC, de Boer MJ, Reiffers S, Miedema K, Ottervanger JP, van't Hof AW, Suryapranata H. Long-term benefit of primary angioplasty as compared with thrombolytic therapy for acute myocardial infarction. *N Engl J Med* 1999;341:1413–1419.
- Stone GW, Grines CL, Cox DA, Garcia E, Tchong JE, Griffin JJ, Guagliumi G, Stuckey T, Turco M, Carroll JD, et al. Controlled Abciximab and Device Investigation to Lower Late Angioplasty Complications (CADILLAC) Investigators. Comparison of angioplasty with stenting, with or without abciximab, in acute myocardial infarction. *N Engl J Med* 2002;346:957–966.
- Antonucci D, Rodriguez A, Hempel A, Valenti R, Migliorini A, Vigo F, Parodi G, Fernandez-Pereira C, Moschi G, Bartorelli A, et al. A randomized trial comparing primary infarct artery stenting with or without abciximab in acute myocardial infarction. *J Am Coll Cardiol* 2003;42:1879–1885.
- Topol EJ, Neumann FJ, Montalescot G. A preferred reperfusion strategy for acute myocardial infarction. *J Am Coll Cardiol* 2003;42:1886–1889.
- The TIMI Study Group. The Thrombolysis In Myocardial Infarction (TIMI) trial: phase 1 findings. *N Engl J Med* 1985;312:932–936.
- O'Connor MK, Hammel T, Gibbons RJ. In vitro validation of a simple tomographic technique for estimation of percentage myocardium at risk using methoxyisobutyl isonitrile technetium 99m (sestamibi). *Eur J Nucl Med Mol Imaging* 1990;17:69–76.
- Sciagrà R, Imperiale A, Antonucci D, Migliorini A, Parodi G, Comis G, Pupi A. Relationship of infarct size and severity versus left ventricular ejection fraction and volumes obtained from 99mTc-sestamibi gated single-photon emission computed tomography in patients treated with primary percutaneous coronary intervention. *Eur J Nucl Med Mol Imaging* 2004;31:969–974.
- Germano G, Kiat H, Kavanagh PB, Moriel M, Mazzanti M, Su HT, Van Train KF, Berman DS. Automatic quantification of ejection fraction from gated myocardial perfusion SPECT. *J Nucl Med* 1995;36:2138–2147.
- Schroder R, Zeymer U, Wegscheider K, Neuhaus KL. Comparison of the predictive value of ST segment elevation resolution at 90 and 180 min after start of streptokinase in acute myocardial infarction. A substudy of the Hirudin for Improvement of Thrombolysis (HIT)-4 study. *Eur Heart J* 1999;20:1563–1571.
- de Lemos JA, Antman EM, Gibson CM, McCabe CH, Giugliano RP, Murphy SA, Coulter SA, Anderson K, Scherer J, Frey MJ, et al. Abciximab improves both epicardial flow and myocardial reperfusion

- in ST-elevation myocardial infarction. Observations from the TIMI 14 trial. *Circulation* 2000;101:239–243.
21. de Lemos JA, Antman EM, Giugliano RP, McCabe CH, Murphy SA, Van de Werf F, Gibson CM, Braunwald E, and the Thrombolysis in Myocardial Infarction (TIMI) 14 Investigators. ST-segment resolution and infarct-related artery patency and flow after thrombolytic therapy. *Am J Cardiol* 2000;85:299–304.
 22. Zeymer U, Schroder R, Tebbe U, Molhoek GP, Wegscheider K, Neuhaus KL. Non-invasive detection of early infarct vessel patency by resolution of ST-segment elevation in patients with thrombolysis for acute myocardial infarction; results of the angiographic substudy of the Hirudin for Improvement of Thrombolysis (HIT)-4 trial. *Eur Heart J* 2001;22:769–775.
 23. van't Hof AW, Liem A, Suryapranata H, Hoorntje JC, de Boer MJ, Zijlstra F. Angiographic assessment of myocardial reperfusion in patients treated with primary angioplasty for acute myocardial infarction: myocardial blush grade. Zwolle Myocardial Infarction Study Group. *Circulation* 1998;97:2302–2306.
 24. Santoro GM, Valenti R, Buonamici P, Bolognese L, Cerisano G, Moschi G, Trapani M, Antoniucci D, Fazzini PF. Relation between ST-segment changes and myocardial perfusion evaluated by myocardial contrast echocardiography in patients with acute myocardial infarction treated with direct angioplasty. *Am J Cardiol* 1998;82:932–937.
 25. Saran RK, Been M, Furniss SS, Hawkins T, Reid DS. Saran RK, Been M, Furniss SS, Hawkins T, Reid DS. Reduction in ST segment elevation after thrombolysis predicts either coronary reperfusion or preservation of left ventricular function. *Br Heart J* 1990;64:113–117.
 26. de Lemos JA, Gibson CM, Antman EM, Murphy SA, Morrow DA, Schuhwerk KC, Schweiger M, Coussement P, Van de Werf F, Braunwald E, for the TIMI 14 Investigators. Abciximab and early adjunctive percutaneous coronary intervention are associated with improved ST-segment resolution after thrombolysis: observations from the TIMI 14 Trial. *Am Heart J* 2001;141:592–598.
 27. Sciagrà R, Parodi G, Pupi A, Migliorini A, Valenti R, Moschi G, Santoro GM, Memisha G, Antoniucci D. Gated SPECT evaluation of outcome after abciximab-supported primary infarct artery stenting for acute myocardial infarction: the scintigraphic data of the Abciximab and Carbostent Evaluation (ACE) randomized trial. *J Nucl Med* 2005; 46:722–727.
 28. Schroder K, Wegscheider K, Zeymer U, Tebbe U, Schroder R. Extent of ST-segment deviation in a single electrocardiogram lead 90 min after thrombolysis as a predictor of medium-term mortality in acute myocardial infarction. *Lancet* 2001;358:1479–1486.
 29. Cooper HA, de Lemos JA, Morrow DA, Sabatine MS, Murphy SA, McCabe CH, Gibson CM, Antman EM, Braunwald E. Minimal ST-segment deviation: a simple, noninvasive method for identifying patients with a patent infarction-related artery after fibrinolytic administration. *Am Heart J* 2002;144:790–795.