



UNIVERSITÀ  
DEGLI STUDI  
FIRENZE

## FLORE

# Repository istituzionale dell'Università degli Studi di Firenze

### **Treatment of perianal fistulas in Crohn's disease by local injection of antibody to TNF-alpha accounts for a favourable clinical response in**

Questa è la Versione finale referata (Post print/Accepted manuscript) della seguente pubblicazione:

*Original Citation:*

Treatment of perianal fistulas in Crohn's disease by local injection of antibody to TNF-alpha accounts for a favourable clinical response in selected cases: a pilot study / ASTERIA CR; FICARI F; BAGNOLI S; MILLA M; F. TONELLI. - In: SCANDINAVIAN JOURNAL OF GASTROENTEROLOGY. - ISSN 0036-5521. - ELETTRONICO. - 41(9)(2006), pp. 1064-1072.

*Availability:*

This version is available at: 2158/224356 since:

*Publisher:*

Taylor & Francis Limited: Rankine Road, Basingstoke RG24 8PR United Kingdom: 011 44 1256 813035,

*Terms of use:*

Open Access

La pubblicazione è resa disponibile sotto le norme e i termini della licenza di deposito, secondo quanto stabilito dalla Policy per l'accesso aperto dell'Università degli Studi di Firenze (<https://www.sba.unifi.it/upload/policy-oa-2016-1.pdf>)

*Publisher copyright claim:*

(Article begins on next page)

ORIGINAL ARTICLE

## Treatment of perianal fistulas in Crohn's disease by local injection of antibody to TNF- $\alpha$ accounts for a favourable clinical response in selected cases: A pilot study

CORRADO R. ASTERIA<sup>1</sup>, FERDINANDO FICARI<sup>1</sup>, SIRO BAGNOLI<sup>2</sup>, MONICA MILLA<sup>2</sup> & FRANCESCO TONELLI<sup>1</sup>

<sup>1</sup>Department of Clinical Physiopathology, Surgery Unit and <sup>2</sup>Department of Clinical Physiopathology, Gastroenterology Unit, University of Florence, Italy

### Abstract

**Objective.** Intravenously administered infliximab, a monoclonal antibody directed against tumor necrosis factor- $\alpha$ , has been proven to be efficacious in the treatment of fistulas in patients with Crohn's disease. It has recently been suggested that local injections of infliximab might be beneficial as well. The aim of this study was to assess whether infliximab could play an effective role in the local treatment of perianal fistulas in Crohn's disease. **Material and methods.** Local infliximab injections were administered to 11 patients suffering from Crohn's disease complicated by perianal disease. Eligible subjects included Crohn's disease patients with single or multiple draining fistulas, regardless of status of luminal disease at baseline. Patients, however, were excluded from the study if they had perianal or rectal complications, such as abscesses or proctitis or if they had previously been treated with infliximab. Twenty-milligram doses of infliximab were injected along the fistula tract and around both orifices at baseline and then every 4 weeks for up to 16 weeks or until complete cessation of drainage. No further doses were administered to patients who did not respond after three injections. Efficacy was measured in terms of response (a reduction in fistula drainage of 50% or more) and remission (complete cessation of fistula drainage for at least 4 weeks). Time to loss of response and health-related quality of life were also evaluated. **Results.** Overall, 8/11 patients (72.7%) responded to the therapy and 4/11 (36.4%) reached remission, whereas 3/11 patients (27.2%) showed no response. Response or remission was very much dependent on the location of the fistulas, and time to loss of response was generally longer for patients who reached remission compared to patients in response. Changes in health-related quality of life, as assessed by the Inflammatory Bowel Disease Questionnaire (IBDQ), also reflected response or remission, with more marked improvements associated with remission. After a mean 10.5 months' follow-up (range 7–18 months), 6/11 patients (54.5%) are in response and 4/11 patients (36.4%) are in remission. No adverse events have been observed in this cohort of patients. **Conclusions.** Local injections of infliximab along the fistula tract seem to be an effective and safe treatment of perianal fistulas in Crohn's disease. However, further controlled clinical investigations are warranted.

**Key Words:** Antibody to TNF- $\alpha$  (Infliximab), local injection, perianal Crohn's disease

### Introduction

Treatment of perianal complications in patients suffering from Crohn's disease (CD) still represents a great challenge for surgeons and gastroenterologists, as healing, prevention of relapses and maintenance of a good quality of life are objectives that are difficult to achieve in these patients.

Epidemiological data for perianal CD have recently been reviewed by the American Gastroenterological Association (AGA) [1]. Moreover, the

cumulative frequency of perianal fistulas in CD has been reported to range from 14% to 38% in patients evaluated at several different referral centers [2–7], and from 17% to 28% in patients undergoing surgery for CD [8,9].

CD is a chronic, granulomatous inflammatory disease of the bowel in which the entire thickness of the bowel wall is inflamed and is thought to be caused by a combination of genetic predisposition and a defective immune response to an inflammatory

Correspondence: Corrado R. Asteria, MD, Department of Clinical Physiopathology, Surgery Unit, University of Florence, Via Morgagni 85, IT-50134 Florence, Italy. Tel: +39 055 7947 449. Fax: +39 055 4361 770. E-mail: corrado.asteria@libero.it

(Received 25 October 2005; accepted 24 January 2006)

stimulus. This causes an up-regulated production of pro-inflammatory cytokines, among which TNF- $\alpha$ , IL-1 and IL-6 all contribute to the intestinal lesions characteristic of CD [10].

The TNF- $\alpha$  blocker infliximab has been proven to be safe and effective in the treatment of both luminal and fistulizing CD, particularly when used as maintenance therapy with infusions at fixed intervals [11–15]. Further advantages of infliximab therapy include the steroid-sparing effect, the decrease in concomitant anti-inflammatory medication use (mesalazine, sulfadiazine), as well as the reduction in hospitalizations and surgeries and improved quality of life.

On the other hand, as with all powerful immunomodulators, the use of TNF- $\alpha$  blockers requires adequate training, proper screening and monitoring procedures, in order to preclude an increased risk of infections and other adverse events (AEs), hence some rare cases of anaphylactic reactions (non-IgE-mediated) have occasionally been reported [16].

Some recent pilot studies have reported the potential benefit of local injection of infliximab for the treatment of perianal fistulas in CD [16–18].

We therefore conducted a small study to assess the efficacy and safety of infliximab locally injected in the fistula tract in selected cases. One of our aims when using this local injection technique was also to possibly prevent some of the AEs associated with the systemic infusion

### Material and methods

Eleven CD outpatients with perianal complications were enrolled in the period 2003–04. Eligible patients included men and women with CD with single or multiple perianal and/or ano-vaginal fistulas, in good drainage conditions (i.e. no ongoing abscesses), of at least 6 months' duration (range 8–36 months) and not responding to standard treatments: 5-aminosalicylates, antibiotics (e.g. metronidazole, ciprofloxacin), azathioprine and corticosteroids, regardless of the presence or absence of active bowel disease (Figure 1). Concomitant therapies for CD, including the mentioned drugs, at a dosage that had been stable for more than 4 weeks before screening were permitted. Setons were allowed at screening but were required to be removed at the first injection of infliximab.

Exclusion criteria were complications of CD, such as current abscesses, complex perianal fistula with multiple tracts, concomitant moderate to severe proctitis and previous treatment with infliximab. Patients were also excluded from this study if they had evidence of latent or active tuberculosis (that is, they had to have clear chest X-ray findings and a negative purified protein derivative skin test).



Figure 1. Patient 8: Injection at the external perianal opening.

All patients accepted and signed an informed consent form attesting the experimental nature of the procedure.

Screening procedures included a physical examination, exploration of the fistula by gentle passage of a malleable probe in the fistula tract, and proctoscopy. Ultrasonography (US) or magnetic resonance imaging (MRI) was not carried out routinely at baseline.

Perianal CD was described and classified according to Park's criteria for describing fistulas (intersphincteric, transsphincteric, extrasphincteric), and the Cardiff pathogenetic classification for perianal manifestations, which both differentiate between purely inflammatory lesions from mechanical or septic complications and define the presence of ulceration, fistula/abscess, and stricture (UFS), qualified by numeric values reflecting severity (0 = not present, 1 = limited clinical impact, and 2 = severe) [19]. All outpatients were treated under local anesthesia.

Medical treatment consisted of a three-step procedure: 1) Removal of the seton; 2) injection of anesthetic (5 ml lidocaine 1%, mixed with 3 ml of 8.4% bicarbonate solution); 3) injection of infliximab (20 mg), diluted in 10 ml physiologic solution, injected along the fistula tract and around both orifices with a spinal needle (Figures 1–3).

According to the treatment schedule, steps 2 and 3 were then repeated every 4 weeks up to 16 weeks or until complete remission was reached and maintained.

If the patient did not respond after three doses, no further infliximab was administered.

### The fistula drainage assessment

Classifying fistulas as either open and actively draining or closed, has been used to evaluate efficacy



Figure 2. Patient 6: Injection at the vaginal opening

at each subsequent treatment, before infliximab injection [14]. A response was defined as a reduction of at least 50% from baseline in fistula drainage for at least two consecutive visits 4 or more weeks apart. Percentage reduction of the fistula drainage was indirectly measured by the frequency of having to change sanitary pads or dressing gauzes. A complete response (remission) was defined as the complete absence of drainage from the fistula, despite gentle finger compression, persisting for at least 4 weeks. Loss of response was defined by the recrudescence of the draining fistula.

We specifically decided to define remission as evidence of cessation of fistula drainage rather than complete fistula closure, as this has been suggested as the appropriate terminology for complete response following differences evidenced between clinical (external physical examination) and diagnostic findings (MRI, anorectal US). In order to assess complete closure of the fistula tract, in



Figure 3. Patient 6: Injection at the internal opening.

addition to cessation of drainage, all patients in remission underwent MRI or US examination.

Evaluation of subjective patient outcome in terms of health-related quality of life (HRQoL) was also assessed. A disease-specific HRQoL measure, the Inflammatory Bowel Disease Questionnaire (IBDQ) [20], was administered at baseline and either one month after the last infliximab injection or one month after the patient was judged by the treating physician to be in remission. Responses are graded on a 7-point Likert scale with higher scores indicating a better quality of life. Total IBDQ score ranges from 32 (i.e. very poor HRQoL) to 224 (i.e. perfect HRQoL). A score of  $\geq 170$  corresponds to clinical remission, and an increase of  $\geq 16$  points is considered to indicate a clinically meaningful improvement [21]. Items in the IBDQ are further summarized under four "dimensional" scores that reflect bowel-related symptoms (e.g. loose stools, abdominal pain), systemic complaints (e.g. fatigue, sleep pattern), social function (e.g. ability to attend work and social events) and emotional status (e.g. anger, depression, irritability). The validity, reliability and responsiveness of the IBDQ are well established [20–22]. No case-control matches were included in this pilot study.

## Results

Local injections of infliximab were administered to 11 patients suffering from CD associated with perianal complications (Figure 4). Patients' characteristics, together with the anatomic and clinical pattern of CD, previous medical treatment, type, classification and duration of perianal disease, clinical and HRQoL outcomes of all patients are outlined in Table I.

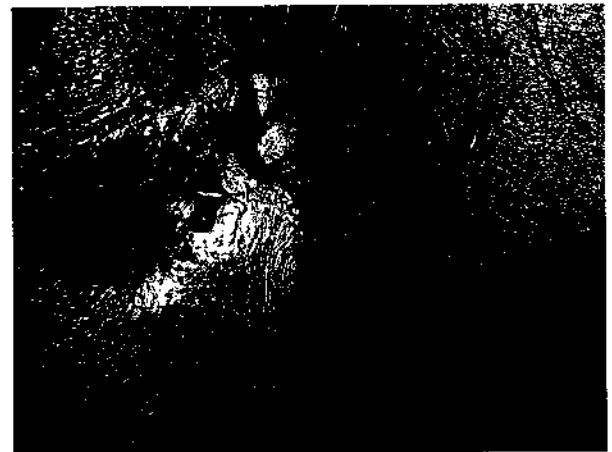


Figure 4. Patient 11: Aspect of external opening showing drainage.

Table I. Patient and clinical characteristics, treatment, clinical outcome and IBDQ assessment.

Patient	Age (years)	Gender	Location CD	Duration luminal CD (years)	Perianal fistulizing type	Duration fistulizing CD (years)	Cardiff Pathological Classification	Previous medical treatments options	Clinical outcome	Change in IBDQ score
1	43	F	Small bowel	26	Low, anterior transsphincteric	2	U0, F1a, S1b	Mesalazine, cortisone	≥ 50% improvement	+9
2	43	M	Small bowel and colon	21	Low, posterior transsphincteric	1	U0, F1a, S1c	Mesalazine	Cessation of drainage	+44
3	32	M	Small bowel	9	Low, blind intersphincteric	0.6	U0, F1c, S0	Mesalazine	No improvement	0
4	43	F	Small bowel	7	Low, transsphincteric, ano-vaginal	1	U0, F1a, d, S0	Mesalazine, azathioprine	No improvement	0
5	39	F	Small bowel	5	Low, posterior transsphincteric	1	U0, F1a, S0	Mesalazine	≥ 50% improvement	+10
6	32	F	Small bowel	8	Low, ano-vaginal transsphincteric	2	U0, F1d, S0	Mesalazine	≥ 50% improvement	+15
7	28	F	Small bowel	9	Low, posterior transsphincteric	1	U0, F1a, S0	Cortisone, mesalazine	Cessation of drainage	+61
8	39	M	Small bowel	7	Low, posterior transsphincteric	3	U0, F1a, S0	Mesalazine	≥ 50% improvement	+17
9	39	M	Small bowel	20	Low, posterior transsphincteric	3	U0, F1a, S0	Mesalazine, cortisone	Cessation of Drainage	+52
10	43	F	Colon	9	Low, anterior transsphincteric, ano-vaginal	2	U0, F2d, S0	Mesalazine, cortisone	No improvement	0
11	44	M	Small bowel	12	Low, posterior transsphincteric	1.6	U0, F1a, S0	Mesalazine, cortisone	Cessation of drainage	+47

Abbreviations: CD = Crohn's disease; IBDQ = Inflammatory Bowel Disease Questionnaire.

Patients received a minimum of 3 and a maximum of 5 injections. Eight out of 11 patients (72.7%) showed reduction in drainage of the fistula of more than 50% compared to baseline, as evidenced by a marked reduction in the number of daily changes of sanitary pads. Of the 8 patients who responded to treatment, 3 reached a complete cessation of fistula drainage (remission) after the second dose of infliximab, whereas another patient reached remission after the third dose. In all the patients who were brought into remission, we decided to administer 1 or 2 more injections as a precautionary measure in order to prevent relapses. In total, 4/11 patients (36.4%) were brought into remission of perianal CD by local infliximab injection. Three out of 11 patients (27.2%) did not show any kind of improvement after therapy (non-responders). Clinical outcome, number of injections and time of MRI or US assessment for each treated patient are depicted in Figure 5. Figure 4 shows external perianal opening of the transsphincteric fistula in patient no. 11 before the start of injections. Figure 6 shows the cessation of drainage in the same patients, despite finger compression.

Changes in HRQoL were in concordance with the patients' clinical outcome. In fact, IBDQ scores remained stable on low values in non-responders (mean change = 0), whereas an improvement, evidenced by an increase in score, was observed in responders, with a mean increase of 12.75 points (range 9–17) for patients in response and 51 points (range 44–61) for patients in remission (Table I). No adverse events were observed in this cohort of patients.

The four patients who reached persistent remission were subjected to either MRI or US examination one month after the last injection, in order to assess whether the treatment allowed a complete fistula closure, not only at the external orifice, but also along the complete fistula tract. The MRI examination showed evidence of complete healing with disappearance of the fistula tract in 2/4 patients (Figures 7 and 8) and persistence of a non-permeable fistula tract in another patient. Endosonographic findings in the last patient showed a non-homogeneous thickening in proximity of the anal sphincter, which, however, in our judgement was not indicative of a fistula tract. Even though US examination does not yield the same accuracy in results as that of MRI, we chose to use US in this specific patient because of the presence of a metal prosthesis in the subject's body.

Patients 1 and 6, the former with low perianal fistulas and the latter with ano-vaginal fistula, experienced a loss of response 6 and 4 months,

respectively, after the last injection. Overall, after a mean of 10.5 months' follow-up (range 7-18 months), 6/11 patients (54.5%) are in response and 4/11 (36.4%) are in remission.

**Discussion**

Perianal fistulas are common but still challenging complications in CD, because they are difficult to treat with standard medical therapy (e.g. 5-aminosalicylates or corticosteroids) and because of a high recurrence rate. Fistulas rarely heal spontaneously.

Treatment with antibiotics (e.g. metronidazole, ciprofloxacin) [23-25] immunosuppressants/immunomodulators (e.g. cyclosporine, tacrolimus, azathioprine, 6-mercaptopurine) [26-31] or dietary therapies [32], although sometimes associated with improvement, has not been demonstrated to result in sustained closure of fistulas in CD and, moreover, has not been shown to have a significant impact on long-term results in prospective controlled studies [1]. The presence of active rectal CD (proctitis) may complicate the clinical situation even more and lower the rates of healing. On the other hand, patients with simple fistulas may experience higher rates of improvement and/or healing compared to complex fistulizing disease [33]. Fistulas decrease quality of life, increase the likelihood of total colectomy and frequently require surgery [34]. Surgery may consist of laying open the fistula tract through 1- or 2-stage fistulotomy (in the case of low fistulas), non-cutting setons (high fistulas involving a significant portion of the external anal sphincter) or endorectal advancement flap (alternative to fistulotomy in patients with low fistulas or an alternative to non-cutting setons in patients with high fistulas who do not have macro-



Figure 6. Patient 11: Gentle finger compression shows cessation of drainage from external opening (shaped as linear scar), one month later, last injection.

scopic evidence of rectal inflammation). Yet, surgical options are often limited by the potential for compromise of anal continence, and are thus mainly employed for drainage of abscesses associated with fistulas. The wide inter-study variability in success rates of surgery probably depends on the non-homogeneity of the sample of patients treated, but might also depend on the type of fistula treated. In fact, Makowiec et al. found healing rates after surgical treatment of low perianal, transsphincteric and high perianal fistulas to be 64%, 40% and 33%, respectively. The presence of active rectal CD may make a simple fistula more complicated to manage. A complex fistula is high, and may have multiple external openings, or it may be associated with pain or fluctuation suggesting a perianal abscess, or with the presence of a rectovaginal fistula, or with the

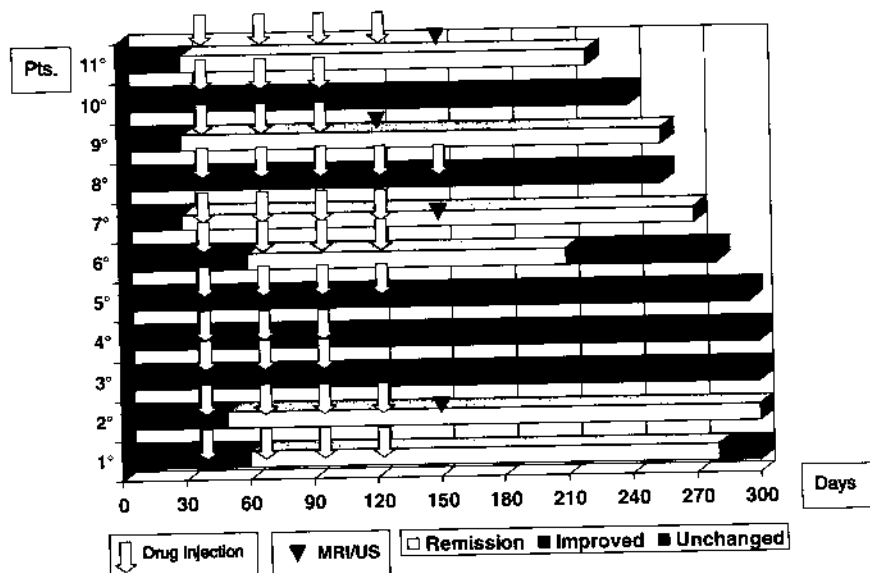


Figure 5. Treatment schedule, clinical outcome and MRI/US assessment.

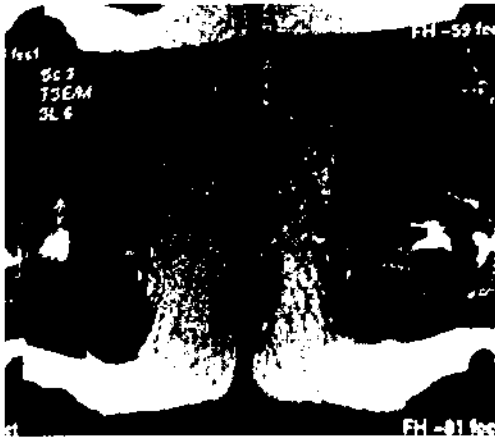


Figure 7. Patient 2: MRI axial scan taken before injection of infliximab shows a low transsphincteric fistula.

anorectal stricture or it may be associated with active rectal disease at endoscopy. Thus, patients with simple fistulas may have higher rates of healing [1]. Exacerbation of perianal disease may occur as a consequence of intestinal inflammation and diarrhea or in isolation from the intestinal activity when the rectum or the anal canal is involved by Crohn's lesions [35]. Moreover, absence of active rectal disease decreased the recurrence rate and increased probability of complete healing. [36].

Hyperbaric oxygen treatment has been reported as an alternative treatment option for perianal CD: a number of 90-min sessions varying from 20 to 67 min at a pressure of 2.5 atm with 100% oxygen seemed to be beneficial in patients with severe perianal CD [37,38]. However, the role of hyperbaric oxygen therapy in perianal CD remains unclear and its efficacy and safety have still to be proven in controlled clinical trials.

More recently, fibrin glue injection has also been proposed as an alternative to classical methods of surgical treatment for obtaining long-term healing of Crohn's anal fistulas [39].

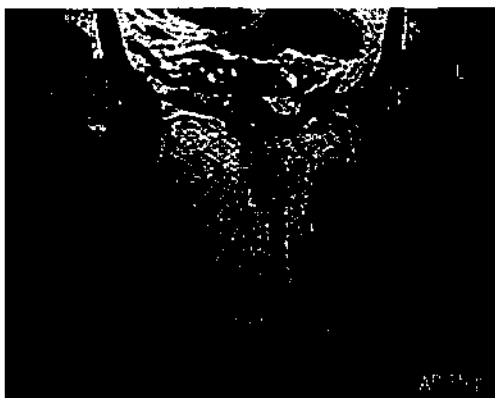

Figure 8. Patient 2: MRI axial scan shows resolution of fistulous tract one month later, last injection.

The long-term safety and efficacy of repeated infusions of infliximab, a monoclonal antibody against TNF- $\alpha$ , has been demonstrated in patients with luminal CD without fistulas in the ACCENT I study [12]. A short-term trial also demonstrated the effectiveness of infliximab for closure of fistulas in patients with fistulizing CD, with a median duration of response of 12 weeks [14]. Finally, the ACCENT II trial evaluated the efficacy and safety of repeated infusions of infliximab in maintaining closure of draining fistulas among CD patients who had single or multiple draining fistula(s) who responded to a three-dose induction regimen of infliximab. This study concluded that, among patients with fistulizing CD whose fistulas closed after infliximab induction therapy, continued infliximab infusions at fixed intervals maintained closure for a longer period than did placebo infusions (more than 40 weeks versus 14 weeks,  $p < 0.001$ ); at week 54, 36% of patients in the infliximab maintenance group had a complete response compared with 19% of patients in the placebo maintenance group [15].

Infliximab has now been marketed for several years in the United States and Europe for the treatment of CD and it has been evidenced, from clinical trials and post-marketing surveillance, that its use can result in the formation of antinuclear antibodies (ANA) or human antichimeric antibodies (HACA) against infliximab [40]. In particular, an analysis of data from ACCENT I, demonstrated that the intermittent or episodic use of infliximab is a less beneficial treatment strategy that is associated with increased antibody formation. Concurrent immunomodulatory therapy reduced antibody formation and the incidence of infusion reactions, particularly in the episodic treatment group, which might improve long-term outcomes of infliximab therapy. However, the use of concomitant immunomodulators must be weighted against the potential for increased toxicity, particularly in patients receiving regular maintenance therapy in which there was a less demonstrable need for and benefit gained from immunomodulatory use. [41]. In general, the results of long-term trials in CD patient populations have shown that antibodies develop in approximately 7–10% of patients receiving regularly scheduled maintenance infusions (i.e. every 4 or 8 weeks) of infliximab [12]. Care must be exercised when re-administering infliximab after a prolonged period (>16 weeks) without treatment, as delayed hypersensitivity reactions (DHRs) may occur. As in the case of infusion reactions, DHRs can be prevented by maintaining a regular regimen of scheduled infliximab infusions. [42].

Besides infusion reactions and DHRs, other infrequent but serious toxicities related to TNF-

neutralizing therapies have emerged. The most worrying are infectious complications, such as tuberculosis (TB) and respiratory tract infections, and the theoretical risk of cancer and lymphoma [43,44]. In particular, an increased risk for TB has been disclosed in post-marketing experience [45], but training, screening and monitoring procedures, together with prophylaxis can markedly reduce the incidence [46]. It is essential that patients are closely monitored for infections including tuberculosis before, during and after treatment with infliximab.

We undertook this pilot study not only to assess the effectiveness of local infliximab injection in some selected cases of patients with perianal CD, but also to try to minimize the AEs associated with the systemic use of infliximab [47].

The use of local injections of infliximab as an alternative to systemic infusions for the treatment of perianal CD has also been explored in a couple of recent publications [17,18].

Lichtiger reported on 9 patients with mild to moderate perianal disease refractory to antibiotics, 6-mercaptopurine or systemic infliximab, treated with a circumferential and intra-fistula injection of infliximab at 1, 2 and 4 weeks. Within 4 weeks, complete healing of the fistulas was observed in 4/9 patients and a partial response in 3/9 patients, whereas no response was observed in the remaining 2 patients [17].

Poggioli et al. modified the technique by injecting infliximab at the internal and external orifices and along the fistula tract in order to allow the closure of the entire tract and to preclude false closure only at the external level, which could lead to new abscess development. Fifteen patients with complex perianal CD in which sepsis was not controllable using surgical or medical therapy were included in the study. Efficacy was measured by a complete morphologic evaluation using a personal score. Ten of 15 patients healed after 3 to 12 infusions, while no major adverse effects were reported, so it was concluded that local injection of infliximab adjacent to the fistula tract of perianal CD is safe and may help in fistula healing [18].

Our experience also corroborates the findings reported in these two studies and shows that local injection of infliximab is safe and feasible. In fact, no adverse events were observed. However, an appropriate patient selection procedure must be adopted; patients eligible for our study were carefully selected, and those presenting with local abscesses and sepsis were excluded. As in the case of the two previously reported studies, analysis of results and drawing any conclusions are limited by the small number of patients and the absence of a control group. Especially owing to the latter point, it is not possible to

define the exact role played by infliximab in the improvement or healing of fistulas. However, at the time of entry into the study, all patients had actively draining fistulas despite concurrent medical therapy, thus even though the mean time of follow-up is short (10.5 months), the overall results obtained in terms of response and remission are encouraging. We have also been able to demonstrate a direct correlation between the mean change in IBDQ scores upon initiation of therapy and clinical outcome, with patients in remission reporting the highest benefits in terms of improvement of HRQL.

In addition, our findings suggest that both Park's anatomical and Hughes-Cardiff's pathophysiological classifications of fistulas are an appropriate tool in describing type and location of lesions in perianal CD. On the basis of these classification criteria, we have observed a direct association between type of fistulas and response to infliximab treatment, with lower responses for blind inter-sphincteric and ano-vaginal fistulas. An association between type of fistulas and clinical outcome after infliximab therapy in patients with fistulous CD has also been recently described by Parsi et al.: in this report, higher rates of closure were observed for external fistulas (including abdominal wall fistulas and perianal fistulas) compared to internal fistulae (including recto-vaginal and entero-vesical fistulas) [48], which is in agreement with our own findings (perianal compared to ano-vaginal fistulas).

A final matter for debate concerning the conducted study is the assessment of outcome. In this study we did not use other types of disease activity indexes, as proposed by Irvine [35] and, more recently, by Pikarsky et al. [49], as those have not been validated or used in clinical trials. [50].

Given the lack of validated methods for measuring the Perianal Disease Activity Index (PDAI), it was difficult to evaluate disease activity at baseline and after treatment, and thus ultimately to draw strong conclusions regarding the benefits of a specific therapy as well as to compare therapies. We used the fistula drainage assessment method as it defines, in a way that is simple to apply in clinical practice as well, the required criteria for fistula response and fistula closure. It must, however, be noted that apparent clinical healing of fistulas may still be associated with ultrasound evidence of persistence of the fistula tract [51]. It is thus important, not only to assess treatment clinical outcome by physical examination, but also by MRI or US examination for a reliable evaluation of complete closure of the fistula tract [52,53]. For this purpose, patients who achieved complete cessation of fistula drainage in our pilot study were also subjected to MRI or US evaluation at a specific time-point (Figure 5). At the



time of follow-up, none of these patients had experienced a reopening and/or restarting of drainage of the fistulas.

## Conclusions

In this pilot study, local infliximab injection seems to be effective, safe and feasible for the treatment of selected cases of perianal CD. This treatment can thus represent an alternative to either standard (and often non-resolving) medical therapies or surgery.

Because of the overall good response to therapy and lack of adverse events in this cohort of patients, we think it could be worthwhile to further explore the effectiveness and safety of this route of administration of infliximab in larger cohorts of patients and in prospective randomized controlled studies.

## References

- [1] Sandborn WJ, Fazio VW, Feagan BG, Hanauer SB. American Gastroenterological Association (AGA) technical review on perianal Crohn's disease. *Gastroenterology* 2003;125:1508-30.
- [2] Farmer RG, Hawk WA, Turnbull RB Jr. Clinical patterns in Crohn's disease: a statistical study of 615 cases. *Gastroenterology* 1975;68:627-35.
- [3] Williams DR, Collier JA, Corman ML, Nugent FW, Veidenheimer MC. Anal complications in Crohn's disease. *Dis Colon Rectum* 1981;24:22-4.
- [4] Fielding JF. Perianal lesions in Crohn's disease. *J R Coll Surg Edinb* 1972;17:32-7.
- [5] Goebell H. Perianal complications in Crohn's disease. *Neth J Med* 1990;37:S47-51.
- [6] Greenstein AJ, Kark AE, Dreiling DA. Crohn's disease of the colon. I. Fistula in Crohn's disease of the colon, classification presenting features and management in 63 patients. *Am J Gastroenterol* 1974;62:419-29.
- [7] Marks CG, Ritchie JK, Lockhart-Mummery HE. Anal fistulas in Crohn's disease. *Br J Surg* 1981;68:525-7.
- [8] van Dongen LM, Lubbers EJ. Perianal fistulas in patients with Crohn's disease. *Arch Surg* 1986;121:1187-90.
- [9] Nordgren S, Fasth S, Hulten L. Anal fistulas in Crohn's disease: incidence and outcome of surgical treatment. *Int J Colorectal Dis* 1992;7:214-8.
- [10] Braegger CP, MacDonald TT. Immune mechanism in chronic inflammatory bowel disease. *Ann Allergy* 1994;72:135-41.
- [11] Targan SR, Hanauer SB, van Deventer SJ, Mayer L, Present DH, Braakman T, et al. A short-term study of chimeric monoclonal antibody cA2 to tumor necrosis factor alpha for Crohn's disease. Crohn's Disease cA2 Study Group. *N Engl J Med* 1997;337:1029-35.
- [12] Hanauer SB, Feagan BG, Lichtenstein GR, Mayer LF, Schreiber S, Colombel JF, et al. and the Accent I Study Group. Maintenance infliximab for Crohn's disease: the ACCENT I randomised trial. *Lancet* 2002;359:1541-9.
- [13] Rutgeerts P, Feagan BG, Lichtenstein GR, Mayer LF, Schreiber S, Colombel JF, et al. Comparison of scheduled and episodic treatment strategies of infliximab in Crohn's disease. *Gastroenterology* 2004;126:402-13.
- [14] Present DH, Rutgeerts P, Targan S, Hanauer SB, Mayer L, van Hogezaand RA, et al. Infliximab for the treatment of fistulas in patients with Crohn's disease. *N Engl J Med* 1999;340:1398-405.
- [15] Sands BE, Anderson FH, Bernstein CN, Chey WY, Feagan BG, Fedorak RN, et al. Infliximab maintenance therapy for fistulizing Crohn's disease. *N Engl J Med* 2004;350:876-85.
- [16] Sandborn WJ, Hanauer SB. Antitumor necrosis factor therapy for inflammatory bowel disease: a review of agents, pharmacology, clinical results, and safety. *Inflamm Bowel Dis* 1999;5:119-33.
- [17] Lichtiger S. Healing of perianal fistulae by local injection of antibody to TNF. *Gastroenterology* 2001;120(Suppl):A3154.
- [18] Poggioli G, Laureti S, Pierangeli F, Rizzello F, Ugolini F, Gionchetti P, et al. Local injection of infliximab for the treatment of perianal Crohn's disease. *Dis Colon Rectum* 2005;48:768-74.
- [19] Hughes LE. Clinical classification of perianal Crohn's disease. *Dis Colon Rectum* 1992;35:928-32.
- [20] Irvine EJ, Feagan B, Rochon J, Archambault A, Fedorak RN, Groll A, et al. Quality of life: a valid and reliable measure of therapeutic efficacy in the treatment of inflammatory bowel disease. *Gastroenterology* 1994;106:287-96.
- [21] Gregor JC, McDonald JWD, Klar N, Feagan BG. An evaluation of utility measurement in Crohn's disease. *Inflamm Bowel Dis* 1997;3:265-76.
- [22] Guyatt G, Mitchell A, Irvine JE, Singer J, Williams N, Goodacre R, et al. A new measure of health status for clinical trials in inflammatory bowel disease. *Gastroenterology* 1989;96:804-10.
- [23] Jakobovits J, Schuster MM. Metronidazole therapy for Crohn's disease and associated fistulae. *Am J Gastroenterol* 1984;79:533-40.
- [24] Bernstein LH, Frank NS, Brandt LJ, Boley SJ. Healing of perineal Crohn's disease with metronidazole. *Gastroenterology* 1980;79:357-65.
- [25] Brandt LJ, Bernstein LH, Boley SJ, Frank NS. Metronidazole therapy for perineal Crohn's disease: a follow-up study. *Gastroenterology* 1982;82:383-7.
- [26] Egan LJ, Sandborn WJ, Tremaine WJ. Clinical outcome following treatment of refractory inflammatory and fistulizing Crohn's disease with intravenous cyclosporine. *Am J Gastroenterol* 1998;93:442-8.
- [27] Present DH, Lichtiger S. Efficacy of cyclosporine in treatment of Crohn's disease. *Dig Dis Sci* 39:374-80.
- [28] Sandborn WJ, Present DH, Isaacs KL, Wolf DC, Greenberg E, Hanauer SB, et al. Tacrolimus for the treatment of fistulas in patients with Crohn's disease: a randomized, placebo-controlled trial. *Gastroenterology* 2003;125:380-8.
- [29] Present DH, Korelitz BI, Wisch N, Glass JL, Sachar DB, Pasternack BS. Treatment of Crohn's disease with 6-mercaptopurine: a long-term, randomized, double-blind study. *N Engl J Med* 1980;302:981-7.
- [30] Pearson DC, May GR, Fick GH, Sutherland LR. Azathioprine and 6-mercaptopurine in Crohn's disease: a meta-analysis. *Ann Intern Med* 1995;123:132-42.
- [31] Korelitz B. Successful treatment of Crohn's disease with an immunosuppressive drug (6-mercaptopurine). In: Pena AS, Weterman IT, Booth CC, Strober W, editors. Recent advances in Crohn disease. The Hague: Nijoff; 1997. pp 478-85.
- [32] Malchow H, Steinhardt HJ, Lorenz-Meyer H, Strohm WD, Rasmussen S, Sommer H, et al. Feasibility and effectiveness of a defined-formula diet regimen in treating active Crohn's disease. European Cooperative Crohn's Disease Study III. *Scand J Gastroenterol* 1990;25:235-44.
- [33] Bell SJ, Williams AB, Wiesel Pilkinson K, Cohen RCG, Kamm MA. The clinical course of fistulating Crohn's disease. *Aliment Pharmacol Ther* 2003;17:1145-51.

- [34] Lapidus A, Bernell O, Hellers G, Löfberg R. Clinical course of colorectal Crohn's disease: a 35 year follow-up study of 507 patients. *Gastroenterology* 1998;114:1151-60.
- [35] Irvine EJ. Usual therapy improves perianal Crohn's disease as measured by a new disease activity index. McMaster IBD Study Group. *J Clin Gastroenterol* 1995;20:27-32.
- [36] Makowiec F, Jahle EC, Starlinger M. Clinical course of perianal fistulas in Crohn's disease. *Gut* 1995;37:696-701.
- [37] Noyer CM, Brandt LJ. Hyperbaric oxygen therapy for perineal Crohn's disease. *Am J Gastroenterol* 1999;94:318-21.
- [38] Lavy A, Weisz G, Adir Y, Ramon Y, Melamed Y, Eidelman S. Hyperbaric oxygen for perianal Crohn's disease. *J Clin Gastroenterol* 1994;19:202-5.
- [39] Vitton V, Gasmi M, Barthet M, Dejeux A, Orsoni P, Grimaud JC. Long-term healing of Crohn's anal fistulas with fibrin glue injection. *Aliment Pharmacol Ther* 2005;21:1453-7.
- [40] Vermeire S, Noman M, Van Assche G, Baert F, Van Steen K, Esters N, et al. Autoimmunity associated with anti-tumor necrosis factor alpha treatment in Crohn's disease: a prospective cohort study. *Gastroenterology* 2003;125:32-9.
- [41] Hanauer SB, Wagner CL, Bala M, Mayer L, Travers S, Diamond RH, et al. Incidence and importance of antibody response to infliximab after maintenance or episodic treatment in Crohn's disease. *Clin Gastroenterol Hepatol* 2004;2:543-53.
- [42] Kugathasan S, Levy MB, Saeian K, Vasilopoulos S, Kim JP, Prajapati D, et al. Infliximab retreatment in adults and children with Crohn's disease: risk factors for the development of delayed severe systemic reaction. *Am J Gastroenterol* 2002;97:1408-11.
- [43] Remicade® (Infliximab). Summary of product characteristics. The Netherlands: Centocor, B.V. Leiden; June 2005.
- [44] Colombel JF, Loftus EV Jr, Tremaine WJ, Egan LJ, Harmsen WS, Schleck CD, et al. The safety profile of infliximab in patients with Crohn's disease: the Mayo clinic experience in 500 patients. *Gastroenterology* 2004;126:19-31.
- [45] Keane J, Gershon S, Wise RP, Mirabile-Levens E, Kasznica J, Schwieterman WD, Siegel JN, Braun MM. Tuberculosis associated with infliximab, a tumor necrosis factor alpha-neutralizing agent. *N Engl J Med* 2001;345(15):1098-104.
- [46] Carmona L, Gomez-Reino JJ, Rodriguez-Valverde V, Montero D, Pascual-Gomez E, Mola EM, et al. Effectiveness of recommendations to prevent reactivation of latent tuberculosis infection in patients treated with tumor necrosis factor antagonists. *Arthritis Rheum* 2005;52:1766-72.
- [47] Fiocchi C. Closing fistulas in Crohn's disease: should the accent be on maintenance or safety? *N Engl J Med* 2004;350:934-6.
- [48] Parsi MA, Lashner BA, Achkar JP, Connor JT, Brzezinski A. Type of fistula determines response to infliximab in patients with fistulous Crohn's disease. *Am J Gastroenterol* 2004;99:445-9.
- [49] Pikarsky AJ, Gervaz P, Wexner SD. Perianal Crohn's disease: a new scoring system to evaluate and predict outcome of surgical intervention. *Arch Surg* 2002;137:774-7.
- [50] Sandborn WJ, Feagan BG, Hanauer SB, Lochs H, Löfberg R, Modigliani R, et al. A review of activity indices and efficacy endpoints for clinical trials of medical therapy in adults with Crohn's disease. *Gastroenterology* 2002;122:512-30.
- [51] Poritz LS, Rowe WA, Koltun WA. Remicade® does not abolish the need for surgery in fistulizing Crohn's disease. *Dis Colon Rectum* 2002;45:771-5.
- [52] Bell SJ, Halligan S, Windsor AC, Williams AB, Wiesel P, Kamm MA. Response of fistulating Crohn's disease to infliximab treatment assessed by magnetic resonance imaging. *Aliment Pharmacol Ther* 2003;17:387-93.
- [53] Rasul I, Wilson SR, MacRae H, Irwin S, Greenberg GR. Clinical and radiological responses after infliximab treatment for perianal fistulizing Crohn's disease. *Am J Gastroenterol* 2004;99:82-8.