



1957

# Radiographic Aspects of Whiplash Injury of the Cervical Spine

Robert R. Wise

Follow this and additional works at: <https://engagedscholarship.csuohio.edu/clevstlrev>

 Part of the [Health Law and Policy Commons](#), and the [Medical Jurisprudence Commons](#)

**How does access to this work benefit you? Let us know!**

---

## Recommended Citation

Robert R. Wise, Radiographic Aspects of Whiplash Injury of the Cervical Spine, 6 Clev.-Marshall L. Rev. 499 (1957)

This Article is brought to you for free and open access by the Law Journals at EngagedScholarship@CSU. It has been accepted for inclusion in Cleveland State Law Review by an authorized editor of EngagedScholarship@CSU. For more information, please contact [library.es@csuohio.edu](mailto:library.es@csuohio.edu).

## *Radiographic Aspects of Whiplash Injury of the Cervical Spine*

*Robert E. Wise, M. D.\**

**W**HILE THE MECHANISM OF SUDDEN FORCEFUL FLEXION or extension of the neck producing injuries to the ligaments, bones, and nerves of the neck has long been known, the term "whiplash injury" appears not to have been used in the medical literature until 1945 when it was first used by Davis.<sup>1</sup> In his paper he analyzed 134 injuries of the cervical spine resulting from automobile accidents. Since then the term has been used to designate injuries to the neck or cervical spine which result from sudden forward or backward motion of the head, excluding the obviously catastrophic injuries resulting in complete paralysis or death from severe dislocation or fracture. The accident frequently appears trivial and the victim may not be aware of serious injury to the neck immediately following the incident but later may be afflicted with disabling or annoying pain.

In the medical literature these injuries have been attributed to either extreme backward or forward forceful bending of the neck, usually the result of automobile accidents, in which the vehicle strikes an object while in forward motion or is struck from the rear. In the familiar accidents occurring in heavy traffic, in which multiple vehicles in a line are involved in a succession of crashes, it is obvious that both mechanisms may apply; the vehicle being struck from behind, producing sudden backward bending or extension of the neck, and in turn the vehicle being propelled forward, striking the vehicle in front, which produces a sudden forward bending or flexion of the neck. Although any of these mechanisms may produce injuries of this

---

\* B.S., University of Pittsburgh; and M.D., University of Maryland. Interned at U. S. Naval Hospital in Philadelphia. Training in Radiology at the Cleveland Clinic. Former member of the Faculty of University of Pittsburgh School of Medicine; and later a member of the Staff of the Lahey Clinic and the New England Baptist Hospital in Boston, Massachusetts. Member of American Medical Association, Massachusetts Medical Society, New England Roentgen Ray Society, Radiologic Society of North America, American College of Radiology, and American Roentgen Ray Society. Certified as a diplomate of the American Board of Radiology.

<sup>1</sup> Davis, A. G.: Injuries of the cervical spine. 127 *J. A. M. A.*, 149-156 (Jan. 20, 1945).

**ILLUSTRATIONS** appear at end of article.

type, the work of James and Hamel<sup>2</sup> in an analysis of 63 cases, of which 86 per cent were produced by rear-end collisions, indicates that the majority are produced when a vehicle is struck from the rear. The ever increasing problem of all injuries due to automobile accidents is apparent to both the medical and legal professions when one considers that in 1954 there were 5,200,000 reported accidents in this country, with 1,500,000 injuries.<sup>3</sup>

### Anatomy

To both the medical and legal mind a knowledge of the anatomy involved is a prerequisite to an understanding of these injuries. The neck is an extremely complicated anatomical structure and only those parts commonly concerned in whiplash injury will be described.

The cervical spine serves two basic functions. It is a semi-rigid support for the head and also a bony tube surrounding and protecting the delicate spinal cord. It is composed of seven separate and distinct bony segments, several with a specialized function; nevertheless it performs as a unit. The first cervical segment or atlas articulates or joins with the base of the skull by means of a movable joint. This is the first bony ring through which the spinal cord passes after it emerges from the skull. Articulating with the atlas is the second segment or axis, which is a specialized bony structure adding stability to the spine by means of the odontoid process, an important structure frequently involved in fractures of the spine. Below the axis are five additional segments aligned one above the other and all of essentially the same structure. At the anterior aspect of each of the lower five segments is a cylindrical bony mass termed the body. Posterior to the body and attached to it is a bony ring termed the neural arch which surrounds the spinal cord. It is composed of a pedicle and lamina on each side, and extending from the lateral aspect of each side of the arch is a bony projection termed the transverse process. From the posterior aspect of the arch, in the mid-line, is another bony projection termed the spinous process. At each side of the arch are specialized joint surfaces termed the facets. These function to add stability while permitting backward and forward motion of the neck as well as turning of the head. On each side, between each segment, formed by the undersurface of

<sup>2</sup> James, O. E., Jr. and Hamel, H. A.: Whiplash injuries of the neck. 52 Missouri Med., 423-426 (June, 1955).

<sup>3</sup> Shelden, C. H.: Prevention, the only cure for head injuries resulting from automobile accidents. 159 J. A. M. A., 981-986 (Nov. 5, 1955).

one arch and the upper surface of the arch below, is the intervertebral foramen through which the cervical nerves emerge from the spinal cord. Between each vertebral body is a structure composed of fibrous cartilaginous material such as is found in the ear or tip of the nose, known as the intervertebral disc. These serve as cushions between the vertebral bodies, cushioning shock and participating in the motions of the neck. Surrounding the entire spine is a series of fibrous structures, the ligaments, binding the segments into a semi-rigid structure while permitting the usual motions of the neck. All of these structures may be involved in the traumatic episodes associated with whiplash injuries.

### Injuries

Discussion of the symptomatology, treatment and prognosis of whiplash injuries I shall leave to my colleagues who are contributing to this symposium, and I shall confine this report to the morbid anatomy of these injuries.

In his original discussion of the subject, Davis listed the common radiographic findings in these injuries as (1) dislocation of the facets, (2) narrowing of the space between the vertebral bodies, (3) narrowing of the intervertebral foramina or (4) combinations of any two or all of the above. Shelden<sup>3</sup> emphasized the tearing of ligaments and muscle attachments. Gay and Abbott<sup>4</sup> in an analysis of 50 cases of whiplash injury described 13 cases of protruded intervertebral disc diagnosed clinically (as distinguished from radiologic diagnosis), and one fracture of the lamina. Schaefer<sup>5</sup> places emphasis on hemorrhage as well as fibrosis and adhesions surrounding nerve roots following injury. James and Hamel describe loss of the normal curvature of the spine secondary to whiplash injury. Gotten<sup>6</sup> surveyed 100 cases of this type which occurred in the city of Memphis, Tennessee and placed considerable emphasis upon the emotional factors involved in these accidents especially as they related to litigation.

From a consideration of the above it is apparent that there is little unanimity of opinion or findings in these injuries. The author therefore proposes a description of the various patho-

<sup>4</sup> Gay, J. R. and Abbott, K. H.: Common whiplash injuries of the neck. 152 J. A. M. A., 1698-1704 (Aug. 29, 1953).

<sup>5</sup> Schaefer, J. H.: Whiplash injuries of neck. 153 J. A. M. A., 974 (Nov. 7, 1953).

<sup>6</sup> Gotten, N.: Survey of one hundred cases of whiplash injury after settlement of litigation. 162 J. A. M. A., 865-867 (Oct. 27, 1956).

logical and anatomical findings to serve as a working basis in the handling and understanding of these cases without regard to statistical factors.

*Radiographic or x-ray findings fall into two major groups, that is, the direct or positive signs and the indirect signs. Positive signs include fracture or dislocation and are usually readily demonstrable by good radiographic technique. The indirect signs are frequently minimal and are generally more difficult to interpret. In a consideration of all radiographic findings, a major problem confronting the physician immediately, and the lawyer later, is to determine whether an injury is present, and if so whether the injury as seen on the radiographic films was present prior to the time of the accident or was sustained at the time of the accident. In the case of fracture, if the films were made immediately following the alleged injury, this can usually be determined. Not only can the diagnosis of fracture usually be made with considerable accuracy, but the time at which it took place can frequently be estimated within certain rather broad limits. Minor degrees of dislocation, not resulting in paralysis or other neurological signs, frequently cannot be interpreted as having occurred within any given time limit.*

There has never been published in the medical literature a valid statistical study of the various radiographic findings including the negative studies in any large series of injuries of this type. However, it is the impression of the author, admittedly without statistical evidence, that the majority of these patients *show at least a loss and at times a reversal of the normal curvature of the spine. This is generally conceded to be due to muscle spasm and very likely associated with some degree of "sprain" or tearing of the ligamentous structures surrounding the spine. Some support to this opinion is found in the studies of James and Hamel. Spasm in the muscles of the back of the neck was found in 66 per cent, and the majority of their cases showed straightening of the spine which they believed was due to this muscle spasm. Unfortunately this sign is frequently seen on routine examinations of the cervical spine in which there is no known history of trauma. It is obviously possible that a patient may have had loss of this curvature from some long-forgotten accident or other coincidental reason such as muscular inflammation. If radiographs were made on this patient immediately following an accident, it is apparent that this could be erroneously interpreted as a sign of recent injury. Straightening or loss of the normal*

curvature, therefore, may be considered an indirect sign of injury, provided it can be established as occurring at the time of or shortly following any given accident.

Direct signs of injury to the cervical spine are more numerous and can be detected in most instances without difficulty. The most obvious alteration which may occur in any bony structure is fracture and this may occur with or without associated dislocation. Any of the bony parts which have been described are susceptible to fracture. There is, however, a paucity of cases of fracture described in the medical literature in those articles dealing with whiplash injury. James and Hamel in their studies of 63 cases, although they describe radiographic alterations in 62 per cent of cases, describe only one case of questionable fracture of the neural arch. Gershon-Cohen and others<sup>7</sup> describe 14 cases of fracture of the spinous process resulting from automobile accidents with sudden forced forward bending of the neck. Gay and Abbott in a study of 50 whiplash injuries found only one fracture of the neural arch. However, serious fractures of the neck in automobile accidents are well known. It is very likely that these cases are excluded from discussions of whiplash injuries since they are frequently catastrophic, are immediately hospitalized for treatment, or perhaps result in death and thus do not present themselves with the symptomatic picture usually described under this heading.

With violent forward or backward bending of the neck, fracture may be produced either by direct pressure of one bony part upon the other or from violent pull upon the bony parts by the ligaments or muscles which are attached to them.

Compression fracture of the vertebral body is the best example of fracture due to direct pressure of one bony part upon the other as a result of violent forward bending. It may vary from minimal compression of the body without injury to the spinal cord or nerves to severe crushing with complete paralysis secondary to pressure upon the spinal cord.

Fracture of the facets may well be due to a combination of direct pressure and ligamentous pull. From a radiographic standpoint, fractures in this region as well as the closely associated pedicles or lamina are the most difficult to visualize and are the most frequently overlooked by the radiologist due to the

---

<sup>7</sup> Gershon-Cohen, J., Budin, E. and Glauser, F.: Whiplash fractures of cervicodorsal spinous processes; resemblance to shoveler's fracture. 155 *J. A. M. A.*, 560-561 (June 5, 1954).

small size of the structures involved and multiplicity of overlying structures. Fractures of the spinous process are readily visualized and are not commonly overlooked.

Although relatively permanent dislocations of the spine may occur, it is very likely that the majority are momentary, with associated ligamentous tear, and result in no visible direct findings on the radiograms. This, of course, is a concept which can be substantiated only from a theoretical consideration of the mechanism of the injury. On rare occasions only is a true dislocation without fracture found, although with films made in the lateral view with the neck bent forward or backward, minor degrees of malalignment of the segments constituting minimal dislocations may be seen.

Injuries to the intervertebral disc secondary to violent bending occur occasionally and frequently are demonstrated indirectly by narrowing of the space between the bodies. These are serious conditions if there is an associated protrusion of the disc substance producing nerve root pressure, as the condition may demand surgical removal for relief of symptoms. Although a protruded intervertebral disc may be suspected clinically, it is usually necessary to insert an opaque oil into the spinal canal to render the protruded disc substance visible on the radiogram. This procedure, the myelogram, is generally accepted as a relatively harmless one and today comparatively few surgeons are willing to operate for a suspected disc protrusion without myelographic confirmation. It must be borne in mind, however, that narrowing of a cervical intervertebral space, usually the fourth, fifth or sixth, is a very common finding in routine radiographic examination of the cervical spine. It is frequently due to simple degeneration as part of the aging process without a history of injury to the neck. This presents a serious problem to the physician in his decision as to whether any given narrowed interspace is the result of a specific traumatic episode. As a general rule, the longer a narrowed interspace has been present the greater the likelihood that associated bony spurs will be present. There is no specific information available as to the length of time necessary for spur formation but it is generally a matter of many months. Thus, if radiographs made immediately following an injury show spurring it would tend to constitute evidence that the injury or degeneration producing the narrowed interspace was not due to the accident. Conversely, if no spurring is present it would tend to substantiate a claim that

the accident was responsible for the narrowing. This, of course, does not preclude the possibility that aggravation of an existing injury cannot take place.

Another indirect sign of injury to the cervical spine with which the author has had no personal experience has been described by Birsner and Leask<sup>8</sup> in a review of 9 cases of whiplash injury in which they describe a displacement of the air passages which lie anterior to the spine. This, they believe, is due to bleeding into or swelling of the tissues between these structures. The illustrations which they present are convincing, and particularly so if subsequent radiograms should show a regression of this displacement, and would very likely constitute valid evidence of injury in a court of law.

### Radiographic Technique

A working knowledge of the common use of radiography in examination of the cervical spine for the detection of whiplash injury is essential to the lawyer concerned with these cases.

The minimum acceptable views for a routine examination of the cervical spine are one made with the beam directed from front to back and a second made with the beam directed laterally, designated the anteroposterior and lateral views respectively. In addition, oblique views made with a 45 degree angulation are usually added. For further evaluation of any possible aberration of motion a lateral view with the neck in flexion and one in extension are frequently made. As mentioned above, the myelogram is essential for confirmation or exclusion of intervertebral disc protrusion. It is very likely that in the future, radiographic movies or cine-radiography will be introduced into courts of law to prove the presence or absence of limitations or alterations of motion, but to date this procedure has not come into general usage. An interesting aspect of its advent will be a possible detection of the malingerer, for although a patient may deliberately restrain motion, he cannot produce abnormal motion.

### Summary

This discussion has been presented in an effort to provide the lawyer with a basic working knowledge of the radiographic problems inherent in the diagnosis of structural changes secondary to whiplash injury of the cervical spine. The primary pur-

<sup>8</sup> Birsner, J. W. and Leask, W. H.: Retropharyngeal soft tissue swelling due to whiplash injury. 68 Arch. Surg., 369-373 (July, 1954).



pose has not been to provide a statistical analysis of the various types of injuries but rather to provide a basic knowledge of the radiographic findings which may constitute evidence of injury produced by a given accident. It is not intended to analyze the degree of associated disability.

It is apparent that there are no valid statistics relative to the incidence of specific radiographic findings secondary to these accidents. In the experience of the author, fractures have been extremely rare and the majority of these cases have shown nothing more than a loss of curvature and in some cases there have been no visible findings in spite of pain or disability.

It is well to remember that radiographic findings by and large do not indicate the degree of disability, but serve only as a guide to possible disability. By the same token, an absence of changes on the radiographic picture does not indicate absence of pain or disability, nor does an absence of findings necessarily indicate psychoneurosis or malingering. It is quite possible to have serious nerve damage or other soft tissue damage without demonstrable radiographic changes. The estimation of disability quite properly remains the function of the orthopedic surgeon and the neurosurgeon.

### **Table**

#### **Radiographic Findings in Whiplash Injury**

1. Occasionally no demonstrable radiographic findings.
2. Loss or reversal of cervical curvature.
3. Dislocation.
  - A. Without associated fracture.
  - B. With associated fracture.
4. Fracture.
  - A. All of the bony structures are susceptible to fracture.
5. Hemorrhage or edema.
  - A. Manifested radiographically as displacement of air passages anterior to cervical spine.
6. Sprain—ligamentous tears or stretching not visible radiographically except as loss of curvature due to spasm.

*(Illustrations follow, in the next three pages.)*

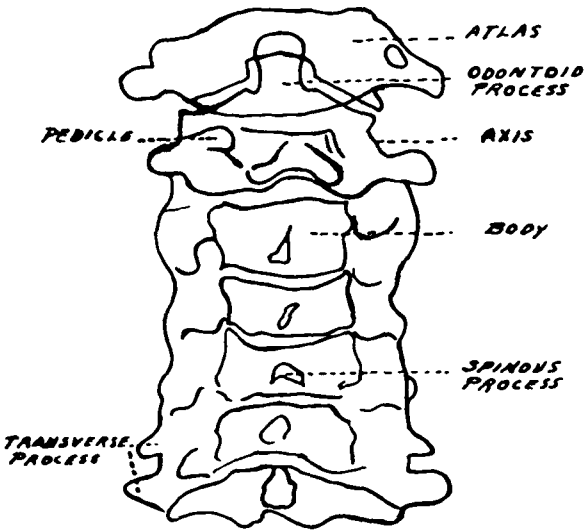


Figure 1

Antero-posterior view of normal cervical spine. (Sketch made from an actual radiograph.) Due to the multiplicity of overlying structures anatomical detail is difficult to interpret. The view is particularly useful for evaluation of alignment of the segments and for visualization of possible fracture of the odontoid process.

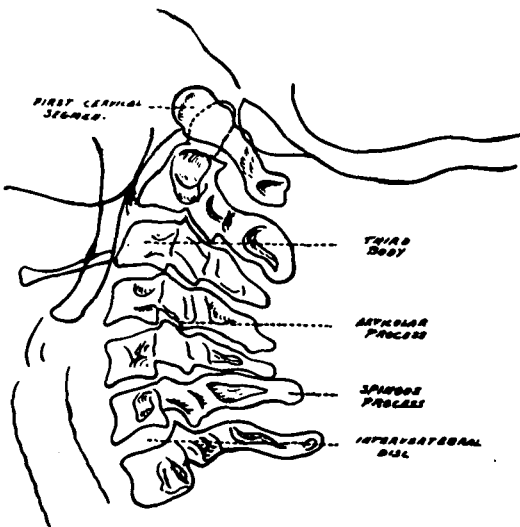
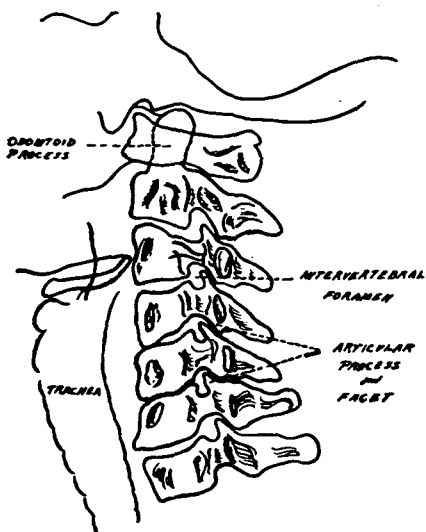


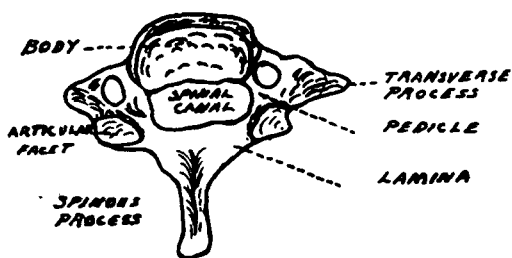
Figure 2

Lateral view of normal cervical spine. Note the regular convex curve designated the lordotic curvature. Intervertebral spaces between the bodies are of approximately the same width. From this view alterations of the cervical curvature may be estimated. It is also valuable for evaluation of interspace narrowing as well as fractures of the vertebral bodies and spinous processes.



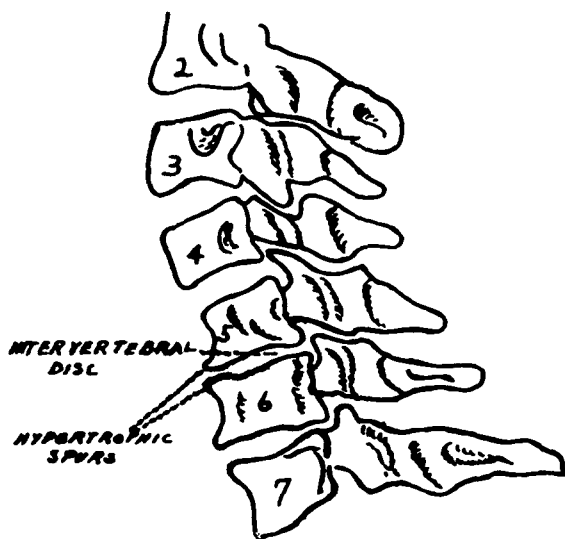
**Figure 3**

Oblique view. This view is particularly valuable for estimation of the size of intervertebral foramina through which the spinal nerves pass. It is the most useful view for visualization of fractures of the articular processes.



**Figure 4**

Schematic drawing of a typical cervical vertebra (with the exception of the first and second which are specialized as shown in Figs. 1 and 2) viewed from above. The spinal cord passes through the portion labeled "spinal canal." All of the labeled bony parts are susceptible to fracture.



**Figure 5**

Lateral view showing narrowing of the intervertebral space between the fifth and sixth bodies. Note the associated reversal of the lordotic curvature. This narrowing could be due to a single degenerative process not associated with a significant injury. The hypertrophic spurs seen anteriorly indicate that the narrowing is not of recent origin. This is a common finding in routine examination of the cervical spine and would not constitute evidence of "whiplash injury" per se.

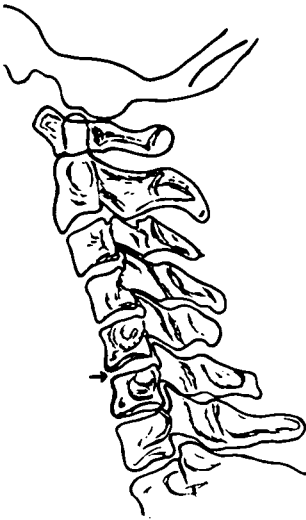

Figure 6(a)

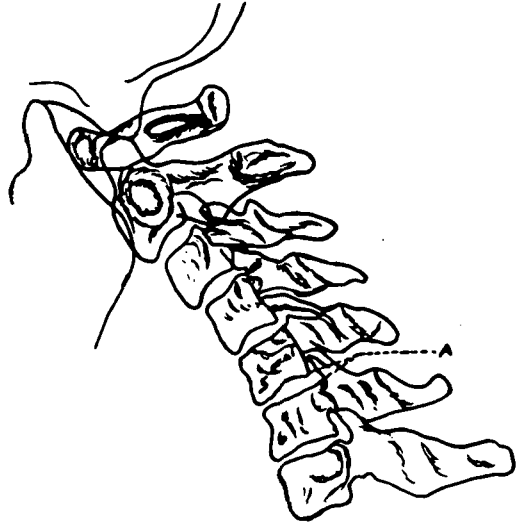


Figure 6(b)

**Lateral views showing frequent findings in "whiplash injury."\***

(a) Lateral view made in the neutral position. Note (arrow) moderate narrowing of the interspace between the fifth and sixth bodies indicative of injury or degeneration of the disc. Absence of hypertrophic spurring indicates probable recent origin. Note also reversal of the lordotic curvature suggestive of associated spasm.

(b) Same patient as Fig. 6(a) with the neck in flexion. Note narrowing between fifth and sixth bodies and minimal forward displacement of the fifth segment with respect to the sixth (shown at A) in association with the narrowing.

\* Radiographs made several days following injury. Vehicle driven by patient was struck from the rear.

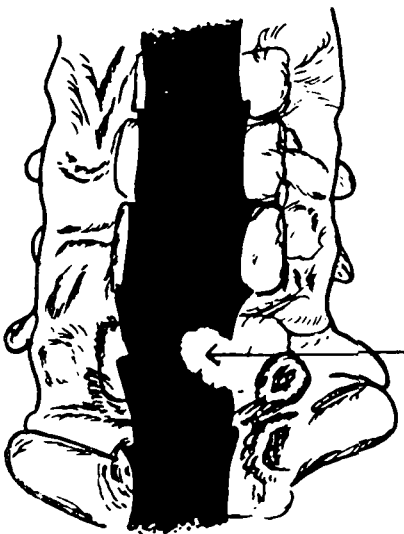


Figure 7

Myelogram. (Antero - posterior view.) Drawing made from radiograph showing typical defect (at arrow) produced by a typical protruded intervertebral disc. Shaded area represents the spinal canal filled with iodized oil. (Pantopaque.)

