



Cedarville University
DigitalCommons@Cedarville

Kinesiology and Allied Health Faculty Publications

Department of Kinesiology and Allied Health

3-1-2009

Optimizing Limb Position for Measuring Knee Anatomical Axis Alignment from Standing Knee Radiographs

T. Derek V. Cooke

Elizabeth A. Sled

Cedarville University, esled@cedarville.edu

Follow this and additional works at: http://digitalcommons.cedarville.edu/kinesiology_and_allied_health_publications

 Part of the [Exercise Science Commons](#)

Recommended Citation

Cooke, T. Derek V. and Sled, Elizabeth A., "Optimizing Limb Position for Measuring Knee Anatomical Axis Alignment from Standing Knee Radiographs" (2009). *Kinesiology and Allied Health Faculty Publications*. 5.
http://digitalcommons.cedarville.edu/kinesiology_and_allied_health_publications/5

This Editorial is brought to you for free and open access by DigitalCommons@Cedarville, a service of the Centennial Library. It has been accepted for inclusion in Kinesiology and Allied Health Faculty Publications by an authorized administrator of DigitalCommons@Cedarville. For more information, please contact digitalcommons@cedarville.edu.



*Une promesse pour la vie

HUMIRA[®]
adalimumab

 **Abbott**
A Promise for Life[™]

The Journal of Rheumatology

The Journal of Rheumatology

Volume 36, no. 3

Optimizing Limb Position for Measuring Knee Anatomical Axis Alignment from Standing Knee Radiographs

T. DEREK V. COOKE and ELIZABETH A. SLED

J Rheumatol 2009;36;472-477

<http://www.jrheum.org/content/36/3/472>

1. Sign up for our monthly e-table of contents
<http://www.jrheum.org/cgi/alerts/etoc>
2. Information on Subscriptions
<http://jrheum.com/subscribe.html>
3. Have us contact your library about access options
Refer_your_library@jrheum.com
4. Information on permissions/orders of reprints
<http://jrheum.com/reprints.html>

The Journal of Rheumatology is a monthly international serial edited by Duncan A. Gordon featuring research articles on clinical subjects from scientists working in rheumatology and related fields.

Optimizing Limb Position for Measuring Knee Anatomical Axis Alignment from Standing Knee Radiographs



There is abundant literature describing approaches to radiographic measurement of alignment of the lower limb and the knee. This is timely in the context of the current transition to digital imaging applications and software for taking and recording measurements¹⁻⁹. It is obviously beneficial to move toward uniformity of methods for defining alignment, and we have supported approaches toward this end¹⁰. Yet, while touched on in these and other accounts¹⁰⁻¹³, limited emphasis has been placed on the importance of limb positioning for radiographic measurements.

Limb positioning is prone to errors that often arise from a lack of standardization, most notably the poor control of limb rotation during patient set-up for imaging. These errors may be exacerbated in the presence of limb deformities, especially those that obscure reference bone landmarks useful in the control of rotation. Therefore, recognition of deformities and control of rotation in the context of both health and disease are important goals for reproducible radiography. Certainly, variations of limb position, especially rotation, significantly influence the alignment measures^{14,15}. The purpose of our editorial is to discuss practical ways to minimize positional errors. This arises from our experience of measurements using a supporting frame to limit positioning variations, thereby improving imaging reliability. Using a positioning frame can limit measurement errors for angles, such as the hip-knee-ankle (HKA) angle, to less than 2° and, with parallax corrected, leg-length distances within 2 mm¹⁴.

Alignment and limitation of positional error

Long radiographic views of the whole limb in stance are ideal for measuring alignment of the knee, in terms of both the HKA angle and the other joint angles that may contribute to any deformity (Figure 1). In practice, femorotibial alignment is commonly assessed from *short* views of the knee (Figure 1, hatched area) from which the *anatomic* (shaft) axes of the femur and tibia (FS, TS) may be located. The femoral mechanical (FM) axis is not available from these views, but may be approximated since FS and FM have a conservative angular offset from each other (about 4°–5°, with low variance)¹⁵⁻²⁰. Correlations (*r*) between the femorotibial angle from knee radiographs and the mechanical axis angle obtained from full-limb radiographs are

reported to range from 0.65 to 0.88^{17,18,21}. Thus, the estimation of FM from short views may be described as useful rather than definitive in terms of revealing the mechanical alignment. Although the femorotibial angle is sensitive and specific enough to differentiate varus and valgus knee alignment in most cases¹⁷, in limbs with proximal or distal bone deformity predictions from truncated views are likely not reliable^{11,12}. It is self-evident that the shorter the view of the knee the greater the chance of missing such deformities, and with that the greater risk of ending up with faulty limb alignment parameters. It is unfortunate that the prevalence of such deformities, and hence the associated error risk, is not well documented. While error analyses have been undertaken for alignment measures obtained from long-limb images using a positioning frame¹⁴, we are unaware of any similar evaluation for more limited views of the limb. All this points to the need for surveys of alignment data comparing short-length with full-length radiographs^{11,12,22,23}.

Toward the reproducibility of alignment data through adequate control of positional error, long-limb views have the advantage of locating hip, knee, and ankle positions. From these may be computed the mechanical axes of the limb. Integral to this approach, we use a frame/platform structure to standardize placement of the entire limb including the measurement of foot rotation angles. Since the platform turns, the patient may be rotated 90° between frontal and lateral views without upset of positioning^{11,13,14}. Using such a system our general approach is to start with the patient's ankles set over fixed marks on the platform: the heels are placed on sagittal lines spaced 6 inches apart. Technologists are trained to flex each limb in turn, rotating the limb to bring the plane of knee flexion within the sagittal plane (Figure 2). Foot rotation angles are then recorded as degrees of deviation of the second toe from the center (sagittal) line. For this purpose there is a reference template on the platform¹¹ (Figure 3). Images are generally obtained with the knee extended, but Sanfridsson, *et al*¹⁵ have shown that controlled semiflexed views can be obtained using the frame. In an analysis of HKA and femoral shaft-tibial shaft (FS-TS) angle measurements in healthy volunteers¹⁵, the authors found differences of less than 1° between the semiflexed and extended positions attributable to femorotibial

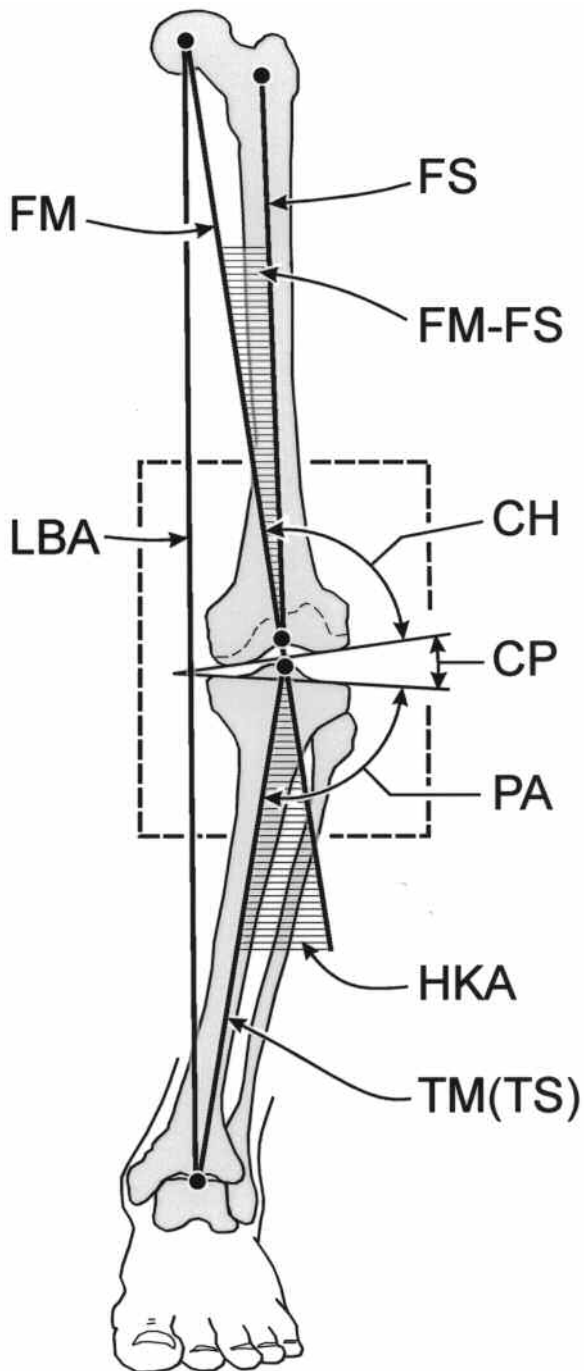


Figure 1. The angles that portray knee alignment (modified from Cooke, *et al*¹⁰). The rectangular hatched region illustrates the limitations imposed on angular measurements of limb alignment when a short view of the knee is obtained. The tibial mechanical (TM) axis and the anatomic tibial shaft (TS) axis are typically coincident. However, the femoral mechanical (FM) axis and the anatomic femoral shaft (FS) axis are *not* coincident, although the angle between them (FM-FS angle) is generally conserved at 4°–5°. This means that, in the event FM and TM cannot be located from radiographs (e.g., short views), the hip-knee-ankle angle (HKA or FM-TM) can be approximated from the measured FS-TS angle by correcting for an assumed angular offset of 4°–5°. LBA: load-bearing axis; CH: condylar-hip angle: the angle of the femoral condylar tangent with respect to the femoral mechanical axis, varus negative, valgus positive; PA: plateau-ankle angle: the angle between the tibial margin tangent and the tibial mechanical axis, varus negative, valgus positive; CP: condylar-plateau angle: the angle between the femoral and tibial joint surface tangents, narrowing medially negative and laterally positive; HKA: hip-knee-ankle angle: the angle between the femoral and tibial mechanical axes, varus negative, valgus positive; FM: femoral mechanical axis; TM: tibial mechanical axis; FS: femoral shaft axis; TS: tibial shaft axis; FM-FS: angle between the femoral mechanical axis and the femoral shaft axis.

rotation. The varus angle was decreased in extension compared to semiflexion.

To optimally align the limb the orientation of the patella is not the prime consideration, since patellar malalignment is quite common in arthritic knees, especially in the presence of varus deformity²⁴. In such knees, to align the patella in the forward-pointing position is to put the flexion angle outside of the sagittal plane²⁵, and a commonly associated lateral shift in the location of the tibial tubercle reduces the reliability of this landmark as a positional reference^{24,25}.

Similarly, fixed foot rotation is not a reliable consideration in positioning. When foot rotation is fixed (e.g., 10° of external rotation using the Synarc frame), there is the likelihood of malrotating the limb should there be excessive external or internal tibial torsion²⁶. Finally, we refer to the common practice of positioning according to the colinearity of the posterior profiles of the femoral condyles²⁷. This approach is also one that we do not favor, since condylar asymmetry tends to be exaggerated in individuals with knee osteoarthritis²⁸⁻³⁰.

As a basis for control of positioning, alignment of the limb according to the orientation of the knee flexion plane lends itself naturally to reproducibility. When the knee is moved through some degree of flexion, the lower leg tracks around the condyles on the knee's flexion axis (an orientation well approximated to the transepicondylar line)^{20,28-31} and perpendicular to the flexion plane.

Healthy limbs are remarkably symmetrical, and with the frame/platform assembly both knees may be imaged simultaneously, with cassettes positioned to the rear, preferably for hips and ankles as well. In situations where the limbs are very deformed (e.g., severe varus or valgus deformities or in the rarer case of a "windswept deformity"), it is better to use a separate image for each limb. Asymmetric rotational malalignments of the tibia may require positioning such that each foot has a different degree of rotation in order to bring the flexion plane into coincidence with the sagittal plane. In contrast, proximal femoral rotational variations (anteversion or retroversion) do not influence foot positioning, which depends on rotation alignment only at the distal end of the femur as the technologist rotates the knee to bring the flexion plane into the desired orientation. Femoral ante/retroversion may, however, be reflected in small changes in the measured femoral anatomic and mechanical axis angles.

Even without a positioning frame, these principles for

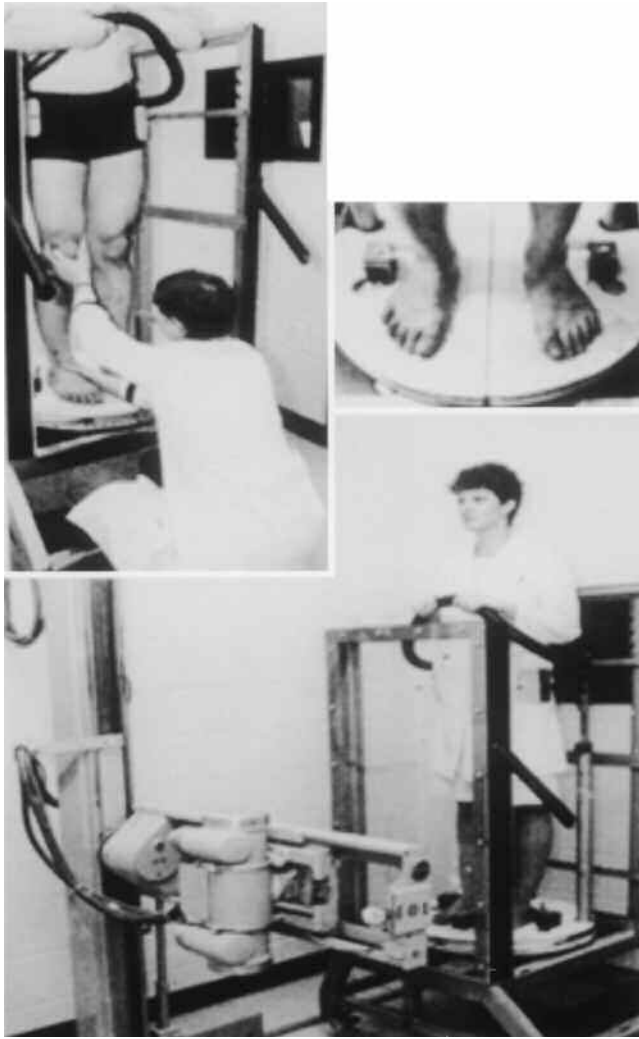

Figure 2. A standardized imaging frame and the set-up used to obtain reliable limb positioning. The technologist is shown evaluating the direction of the knee flexion plane.

controlling positional errors may be successfully adapted to other radiographic configurations to yield a reduction of positional errors.

Recognizing limb deformity and positional error

Technologists need to acquire the skills not only to control against positional errors, but also to recognize malpositioning when reading radiographic knee images. Considering a knee with mild medial compartment osteoarthritis, if it is correctly aligned in the frame the image will show symmetry of the femoral condylar outlines and of the femoral intercondylar notch viewed frontally (Figure 4a). On the frontal view the tibiofibular gap is also evident, with the proximal tibiofibular joint partly covered by the lateral tibial margin. The outline of the patella is usually central. In the orthogonal lateral view the femoral condyles overlap and the medial articular surface (slightly larger than the lateral) is typi-

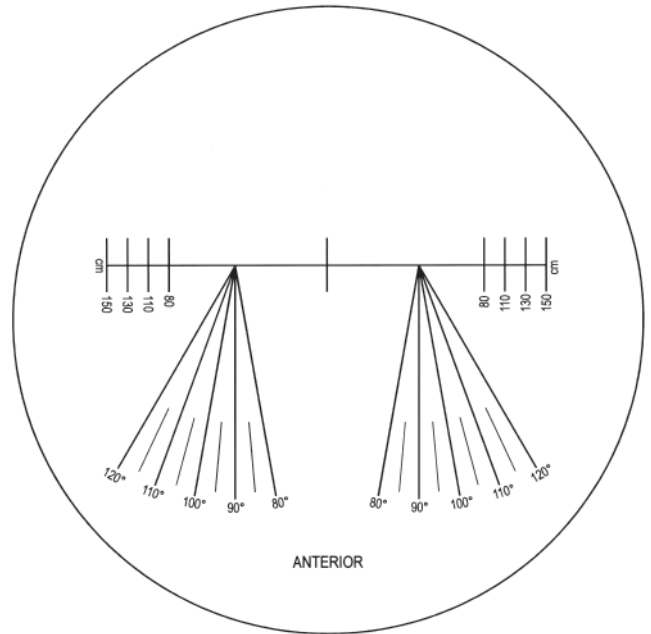


Figure 3. Example of a positioning decal used to locate the feet and record foot rotation. Both limbs are set up with equal weight and each knee flexion plane ahead. The feet are positioned with the heels on their respective sagittal lines spaced 6 inches apart. After rotating the knees to correctly align the flexion plane, foot rotation is recorded as degrees of deviation of the second toe from the center (sagittal) line.

cally more distal and posterior to the lateral surface (Figure 4b). The fibular shaft is evident posteriorly, slightly separated from the posterior tibial shaft, with the tibiofibular joint overlapped by the proximal posterior tibia.

In the same knee that has been positioned with excessive external rotation, the frontal view reveals the medial femoral condyle to have become more prominent while the lateral femoral condyle becomes more vertical (Figure 5a). The femoral notch is now asymmetric, with the lateral wall of the notch more vertical. The tibiofibular interval is narrow and the joint more covered. The patella has moved to a more lateral position. Conversely, in a knee positioned with too much internal rotation (Figure 5b), the opposite applies.

While the illustrations used here are of a knee that is not severely affected by osteoarthritis, the same features are evident in those with more advanced arthritis when malpositioned.

Summary

Standard, accurate, and reliable measurements of knee alignment, while desirable, are too frequently unavailable. The main drawbacks are the diversity of methods for imaging measurements and the variety of imaging set-ups in which imaging error is unknown or not well defined. It is obviously desirable to work toward uniformity in these areas. Regarding radiographic configurations, short views are commonly used, but fail to locate the mechanical axes

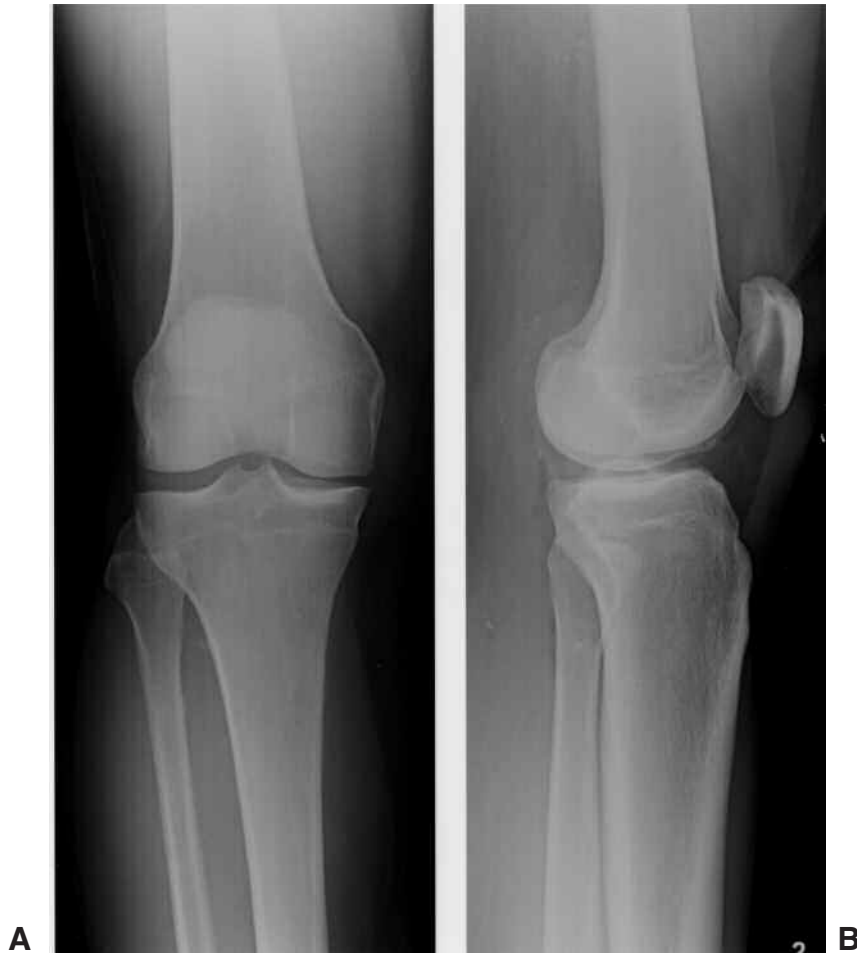

Figure 4. A. Anterior-posterior standing view of a knee with mild medial compartment osteoarthritis. Note the condylar symmetry of the femoral condylar projections and the intercondylar notch. A distinct tibiofibular interval is present, with slight overlap of the proximal tibiofibular joint. B. The same knee viewed standing from the 90° lateral perspective. Note the asymmetry of the femoral condylar projections, with the medial surface being more distal and posterior. Note the slim tibiofibular gap.

(at least directly), which is a limitation that becomes serious in the presence of many limb deformities. Long views overcome these limitations, providing locations for the hip, knee, and ankle centers from which the limb mechanical axes, along with the orientations of the knee's articulating surfaces, may be computed.

Whatever methods are used, there is a universal requirement to reduce errors by control of positioning, and we have described our use of a special frame to this end. The basic approach to positioning is important and we have outlined a procedure where the knee's plane of flexion is the common reference for positioning, specifically to align it within the sagittal plane. We have discussed our reasons, notably heightened risk of error in the presence of deformities, for distrusting the use of other positioning guides that include positioning the limbs according to the orientation of the patella, tibial tubercle, foot, and condylar outlines. Finally,

the importance of technologist training has been emphasized, in the context of correct positioning of patients, and in identification of (and compensation for) mal-rotation errors in the radiographic images. Thus, as in every field, training and experience are both critical elements of good radiography.

T. DEREK V. COOKE, MB, BChir, FRCSC,
Adjunct Professor;

ELIZABETH A. SLED, PhD, MSc, BScPT,
Assistant Professor,
School of Rehabilitation Therapy,
Queen's University,
Kingston, Ontario, Canada

Address reprint requests to Dr. T.D.V. Cooke, 797 Princess Street,
Suite 404, Kingston, Ontario K7L 1G1. E-mail: derek@cookes.ca

ACKNOWLEDGMENT

The editorial assistance of Dr. Allan Scudamore during the preparation of the manuscript is gratefully acknowledged.

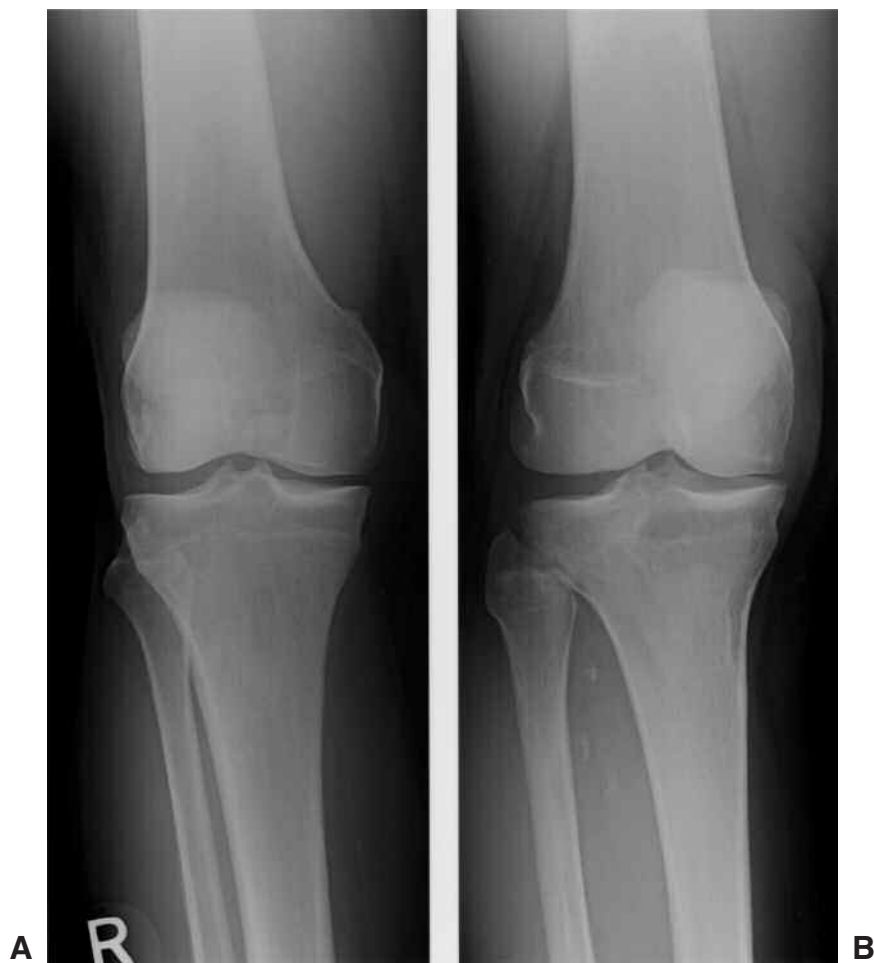

Figure 5. A. In this view the same knee (Figure 4) has been repositioned in the frame with a small degree of external rotation. Note the prominence of the medial femoral condyle and the asymmetry of the intercondylar notch. The patella is seen more lateral to the midline. Note narrowing of the tibiofibular interval with more overlap of the proximal tibiofibular joint. B. The same knee viewed from the front, but repositioned with some internal rotation. Note the more medially disposed patella, the greater prominence of the lateral femoral condyle, the asymmetry of the intercondylar notch, and the widened tibiofibular interval.

REFERENCES

- Hankemeier S, Gosling T, Richter M, Hufner T, Hochhausen C, Krettek C. Computer-assisted analysis of lower limb geometry: higher intraobserver reliability compared to conventional method. *Comput Aided Surg* 2006;11:81-6.
- Prakash U, Wigderowitz CA, McGurty DW, Rowley DI. Computerised measurement of tibiofemoral alignment. *J Bone Joint Surg Br* 2001;83:819-24.
- Rozzanigo U, Pizzoli A, Minari C, Caudana R. Alignment and articular orientation of lower limbs: manual vs computer-aided measurements on digital radiograms. *Radiol Med* 2005;109:234-8.
- Sailer J, Scharitzer M, Peloschek P, Giurea A, Imhof H, Grampp S. Quantification of axial alignment of the lower extremity on conventional and digital total leg radiographs. *Eur Radiol* 2005;15:170-3.
- Sanfridsson J, Ryd L, Eklund K, Kouvarasa Y, Jonsson K. Angular configuration of the knee. Comparison of conventional measurements and the QUESTOR Precision Radiography system. *Acta Radiol* 1996;37:633-8.
- Sled E, Costigan P, Cooke TDV, et al. Measuring malalignment in knee OA. *Osteoarthritis Cartilage* 2005;13:S120.
- Sled E, Cooke TDV, Sheehy L, et al. Reliability of lower limb frontal plane alignment measures obtained with the use of a computer program and electronic tools. *J Bone Joint Surg Br* 2009; (in press).
- Specogna AV, Birmingham TB, DaSilva JJ, et al. Reliability of lower limb frontal plane alignment measurements using plain radiographs and digitized images. *J Knee Surg* 2004;17:203-10.
- Takahashi T, Yamanaka N, Komatsu M, Ogawa Y, Yoshida S, Yamamoto H. A new computer-assisted method for measuring the tibio-femoral angle in patients with osteoarthritis of the knee. *Osteoarthritis Cartilage* 2004;12:256-9.
- Cooke TD, Sled EA, Scudamore RA. Frontal plane knee alignment: a call for standardized measurement. *J Rheumatol* 2007;34:1796-801.
- Cooke TD, Scudamore RA, Bryant JT, Sorbie C, Siu D, Fisher B. A quantitative approach to radiography of the lower limb. Principles and applications. *J Bone Joint Surg Br* 1991;73:715-20.

12. Cooke TD, Li J, Scudamore RA. Radiographic assessment of bony contributions to knee deformity. *Orthop Clin North Am* 1994;25:387-93.
13. Cooke TDV, Scudamore A. Measuring the X-ray: Problems and solutions. *COA Bulletin ACC* 2004; May/June:30-1.
14. Siu D, Cooke TD, Broekhoven LD, et al. A standardized technique for lower limb radiography. Practice, applications, and error analysis. *Invest Radiol* 1991;26:71-7.
15. Sanfridsson J, Ryd L, Svahn G, Friden T, Jonsson K. Radiographic measurement of femorotibial rotation in weight-bearing. The influence of flexion and extension in the knee on the extensor mechanism and angles of the lower extremity in a healthy population. *Acta Radiol* 2001;42:207-17.
16. Hsu RW, Himeno S, Coventry MB, Chao EY. Normal axial alignment of the lower extremity and load-bearing distribution at the knee. *Clin Orthop Relat Res* 1990;255:215-27.
17. Issa SN, Dunlop D, Chang A, et al. Full-limb and knee radiography assessments of varus-valgus alignment and their relationship to osteoarthritis disease features by magnetic resonance imaging. *Arthritis Rheum* 2007;57:398-406.
18. Kraus VB, Vail TP, Worrell T, McDaniel G. A comparative assessment of alignment angle of the knee by radiographic and physical examination methods. *Arthritis Rheum* 2005;52:1730-5.
19. Moreland JR, Bassett LW, Hunker GJ. Radiographic analysis of the axial alignment of the lower extremity. *J Bone Joint Surg Am* 1987;69:745-9.
20. Yoshioka Y, Siu D, Cooke TD. The anatomy and functional axes of the femur. *J Bone Joint Surg Am* 1987;69:873-80.
21. Hinman RS, May RL, Crossley KM. Is there an alternative to the full-leg radiograph for determining knee joint alignment in osteoarthritis? *Arthritis Rheum* 2006;55:306-13.
22. Cooke TD, Harrison L, Khan B, Scudamore A, Chaudhary MA. Analysis of limb alignment in the pathogenesis of osteoarthritis: a comparison of Saudi Arabian and Canadian cases. *Rheumatol Int* 2002;22:160-4.
23. Cooke TD, Scudamore A, Greer W. Varus knee osteoarthritis: whence the varus? *J Rheumatol* 2003;30:2521-3.
24. Harrison MM, Cooke TD, Fisher SB, Griffin MP. Patterns of knee arthrosis and patellar subluxation. *Clin Orthop Relat Res* 1994;309:56-63.
25. Cooke TDV, Price N, Fisher B, et al. The inwardly pointing knee. An unrecognized problem of external rotational malalignment. *Clin Orthop Relat Res* 1990;260:56-60.
26. Yoshioka Y, Siu DW, Scudamore RA, Cooke TDV. Tibial anatomy and functional axes. *J Orthop Res* 1989;7:132-7.
27. Buckland-Wright C. Protocols for precise radio-anatomical positioning of the tibiofemoral and patellofemoral compartments of the knee. *Osteoarthritis Cartilage* 1995;3 Suppl:71-80.
28. Cooke TDV, Scudamore A. Healthy knee alignment and mechanics. In: Callaghan JJ, Rosenberg AG, Rubash HE, et al. editors. *The adult knee*. Philadelphia: Lippincott Williams & Wilkins; 2003:175-86.
29. Elias SG, Freeman MA, Gokcay EI. A correlative study of the geometry and anatomy of the distal femur. *Clin Orthop Relat Res* 1990;260:98-103.
30. Yoshioka Y, Cooke TD. Femoral anteversion: assessment based on function axes. *J Orthop Res* 1987;5:86-91.
31. Churchill DL, Incavo SJ, Johnson CC, Beynon BD. The transepicondylar axis approximates the optimal flexion axis of the knee. *Clin Orthop Relat Res* 1998;356:111-8.

J Rheumatol 2009;36:472-7; doi:10.3899/jrheum.080732