



Technological University Dublin
ARROW@TU Dublin

Articles

School of Biological Sciences

2012

Use of Colour Duplex Ultrasound as a First Line Surveillance Tool Following EVAR is Associated with a Reduction in Cost Without Compromising Accuracy

C. Gray

Technological University Dublin

Pat Goodman

Technological University Dublin, Pat.Goodman@tudublin.ie

C. C. Herron

Department of Vascular Surgery, Mater Misericordiae University Hospital, Suite 5, 69 Eccles Street, Dublin 7, Ireland

L. P. Lawler

Department of Radiology, Mater Misericordiae University Hospital, Dublin, Ireland

Follow this and additional works at: <https://arrow.tudublin.ie/scschbioart>



K. O'Malley
Part of the [Surgery Commons](#)

Department of Vascular Surgery, Mater Misericordiae University Hospital, Suite 5, 69 Eccles Street, Dublin 7, Ireland

Recommended Citation

Gray, C. et al. (2012) Use of Colour Duplex Ultrasound as a First Line Surveillance Tool Following EVAR is Associated with a Reduction in Cost Without Compromising Accuracy. *European journal of vascular and endovascular surgery*, 44 (2012) 145e150. doi:10.1016/j.ejvs.2012.05.008

This Article is brought to you for free and open access by the School of Biological Sciences at ARROW@TU Dublin. It has been accepted for inclusion in Articles by an authorized administrator of ARROW@TU Dublin. For more information, please contact yvonne.desmond@tudublin.ie, arrow.admin@tudublin.ie, brian.widdis@tudublin.ie.



This work is licensed under a [Creative Commons Attribution-NonCommercial-Share Alike 3.0 License](#)



Authors

C. Gray, Pat Goodman, C. C. Herron, L. P. Lawler, M. K. O'Malley, M. K. O'Donohoe, and C. O. Mc. Donnell



Use of Colour Duplex Ultrasound as a First Line Surveillance Tool Following EVAR is Associated with a Reduction in Cost Without Compromising Accuracy **CME**

C. Gray^{a,c}, P. Goodman^c, C.C. Herron^a, L.P. Lawler^b, M.K. O'Malley^a, M.K. O'Donohoe^a, C.O. McDonnell^{a,*}

^a Department of Vascular Surgery, Mater Misericordiae University Hospital, Suite 5, 69 Eccles Street, Dublin 7, Ireland

^b Department of Radiology, Mater Misericordiae University Hospital, Dublin, Ireland

^c School of Physics, Dublin Institute of Technology, Ireland

WHAT THIS PAPER ADDS

- This study demonstrates that duplex ultrasound can supplant CT as the postoperative surveillance tool of choice following EVAR without any compromise in accuracy of imaging and resulting in significant cost savings.

ARTICLE INFO

Article history:

Received 8 November 2011

Accepted 6 May 2012

Available online 19 June 2012

Keywords:

Duplex

EVAR

Aneurysm

CT

ABSTRACT

Introduction: CT scanning remains the postoperative surveillance imaging modality of choice following EVAR. Concerns regarding cost, exposure to ionising radiation and intravenous contrast have led to a search for a less expensive, equally efficacious and safer method of monitoring EVAR patients after endograft deployment. This study evaluated the cost saving obtained if CDUS was employed as a first line surveillance tool following EVAR, as well as comparing the two entities in terms of efficacy.

Patients & methods: Postoperative surveillance CTs and CDUS scans in the 145 patients who have undergone EVAR from 1st June 2003 to 1st July 2010 were compared for the detection of endoleak and determination of residual sac size.

Results: Adopting a protocol where CDUS was employed as the first line surveillance tool following EVAR would result in a reduction in the number of postoperative CTs required in 2010 from 235 to 36. Based on 2010 costings, this would equate to an estimated reduction in expenditure from €117,500 to €34,915 a saving of €82,585. CDUS had a sensitivity of 100% and a specificity of 85% in the detection of endoleaks compared to CT. The positive predictive value was 28% and negative predictive value 100%. The Pearson Coefficient correlation of 0.96 indicates a large degree of correlation between CDUS and CT when measuring residual aneurysm size following EVAR.

Conclusion: CDUS can replace CT as the first line surveillance tool following EVAR. This is associated with a significant reduction in the cost of surveillance without any loss of imaging accuracy.

© 2012 European Society for Vascular Surgery. Published by Elsevier Ltd. All rights reserved.

Introduction

The short term benefits of endovascular (EVAR) over open abdominal aortic aneurysm (AAA) repair of decreased mortality, reduced blood loss, shorter hospital stay and improved quality of life^{1,2} are balanced by concerns regarding the durability of the procedure, and the occurrence of the EVAR unique complications of

endoleak and graft migration. This mandates lifelong surveillance for patients following EVAR in order to ensure continued exclusion of the aneurysm from the circulation. While contrast enhanced computed tomography (CT) is currently the prevalent imaging modality for EVAR surveillance,³ concerns exist due to the administration of high doses of ionising radiation together with the potential nephrotoxicity of the intravenous contrast.⁴ The increased demand for CT by virtually all hospital disciplines means the availability of scanning time is becoming an issue. Identification of an equally accurate, safer, non-invasive and less harmful method of adequately imaging the aorta with a high sensitivity and specificity following EVAR is desirable.

CME To access continuing medical education questions on this paper, please go to www.vasculareducation.com and click on 'CME'

* Corresponding author. Tel.: +353 1 830 8241; fax: +353 1 838 0851.

E-mail address: mrcomcdonnell@gmail.com (C.O. McDonnell).

Colour Duplex Ultrasound (CDUS) is an inexpensive, harmless, non-invasive and widely available imaging modality which is the investigation of choice for the screening and surveillance of AAA prior to intervention.^{5,6} Aneurysm sac size and blood flow within the residual aneurysm sac can be determined using CDUS which could therefore be capable of replacing CT as the primary surveillance tool following EVAR. Recent guidelines from the European Society for Vascular Surgery state that CDUS is a safe and sensitive method of endoleak detection, but caution that it should not be a stand alone modality for follow up after EVAR.⁷

While others have compared CDUS with CT as a surveillance tool following EVAR,^{8,9} the implications of a potential change to the postoperative follow up algorithm have not been reported. We sought to evaluate the potential cost savings obtained by using CDUS rather than CT as the first line imaging method for post-EVAR surveillance. We also compared the efficacy of the two modalities to ensure that any cost saving would not compromise accuracy of follow up.

Patients & Methods

Patients

Following ethical approval, the CDUS and CT scans of all 145 patients who underwent EVAR at the Mater Hospital from 1st June 2003 to 1st July 2010 were retrospectively reviewed. There were 122 (84.1%) male and 23 (15.8%) female patients with a mean (\pm SD) age of 77.1 (\pm 7.9) years. There was no statistical difference between the mean male and female ages. Complete patient demographics and risk factors were available in 141 (97.3%) patients. Deficiencies in the clinical notes in 4 (2.8%) patients meant risk factors could not be assessed. No fenestrated EVARs were performed in the hospital during the timespan of the study.

Following graft implantation all patients underwent regular post operative surveillance, including CDUS and CT scans of the

aorta within 7 days of surgery (Fig. 1). After discharge, all patients a CDUS scan at 1 month and then a CDUS scan, and a CT scan, at 6 months, 12 months and annually thereafter provided there was no documented endoleak on either CDUS or CT. Patients who missed scheduled appointments were contacted directly by phone and asked to reattend.

A total of 715 scans were performed on the 145 patients, 426 (59.6%) CDUS and 289 (40.4%) CTs. A mean (\pm SD) of 2.9 (\pm 1.9), CDUS scans and 1.9 (\pm 1.5) CT scans were performed per patient. Of the total 715 tests performed there were 484 (67.9%) scans available for comparison in 114 (78.6%) of the 145 patients reviewed. The CDUS and CT scans of the remaining 31 (21.4%) patients were not compared due to inconsistent timing of imaging modalities (scans performed greater than 90 days apart were excluded), failure to attend and CT being contra-indicated due to i.v. contrast allergy.

Of the 426 CDUS scans carried out 26 (6.1%) scans were reported as limited, due to the presence of excess bowel gas and body habitus curtailing the determination of residual sac size and endoleak detection. The maximum residual aneurysm size was documented on the remaining 400 (93.9%) CDUS scans. Of the 289 CT's performed 107 (37%) did not have the maximum residual aneurysm sac size documented in the report. The maximum residual aneurysm size was documented on the remaining 182 (63%) of CT scan reports.

Colour duplex ultrasound scanning

All patients were fasted for at least 6 h and scanned in the supine position in a darkened temperature controlled room according to a standard clinical measurement protocol. All scans were performed early in the day to minimise the effect of bowel gas by the same Accredited Vascular Technologist (CG) using a Siemens Sequoia 512 Ultrasound system and later in the study a Siemens S200 Ultrasound system (Siemens AG, Erlangen, Germany). The same 6 MHz curvilinear broadband transducer (range 4 MHz–6 MHz) was used to capture all greyscale and Colour Doppler images. In all cases the technologist was blind to the CT results. Any examination that did not achieve complete visualisation of the entire aneurysm sac was considered limited. Contrast was not used in any patient.

All CDUS began with visualisation of the aorta immediately inferior to the diaphragm. The residual aneurysm was imaged in B-mode in both transverse and longitudinal planes from diaphragm to iliac bifurcation. Multiple measurements were obtained of the residual aneurysm sac in the transverse plane (Fig. 2a). The maximum measurements of the residual aneurysm sac were recorded and compared to the last scan report to ensure that there was no significant increase in sac size. Careful note was made in B-mode of the stent walls to ensure that there was no evidence of obvious defects or kinking of the metal exoskeleton. The iliac arteries were imaged in B-mode throughout their entire length. Multiple transverse and antero-posterior (AP) measurements were obtained (Fig. 2b) and the maximum of the two measurements was recorded for follow up purposes.

The stent and residual aneurysm sac were then assessed using colour flow and spectral Doppler to rule out the presence of an endoleak. This required the use of very sensitive colour flow scale settings to determine the presence of low velocity leaks which may have been present within the residual aneurysm sac (Fig. 2c). The stent was then reassessed in both transverse and longitudinal planes from diaphragm and to iliac bifurcation. Proximal and distal sealing zones were assessed to ensure that there was no evidence of high jet flow indicating a Type 1 endoleak or low velocity flow within the old aneurysm sac demonstrating forward and reversed flow indicating the presence of a Type 2 endoleak. Blood flow

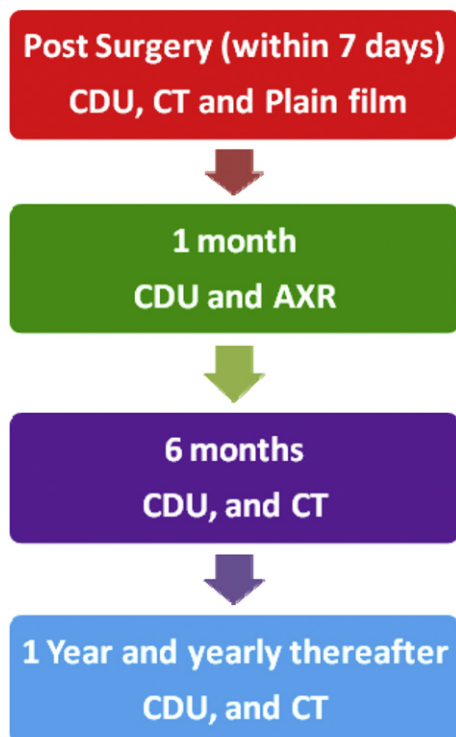


Figure 1. Postoperative surveillance protocol.

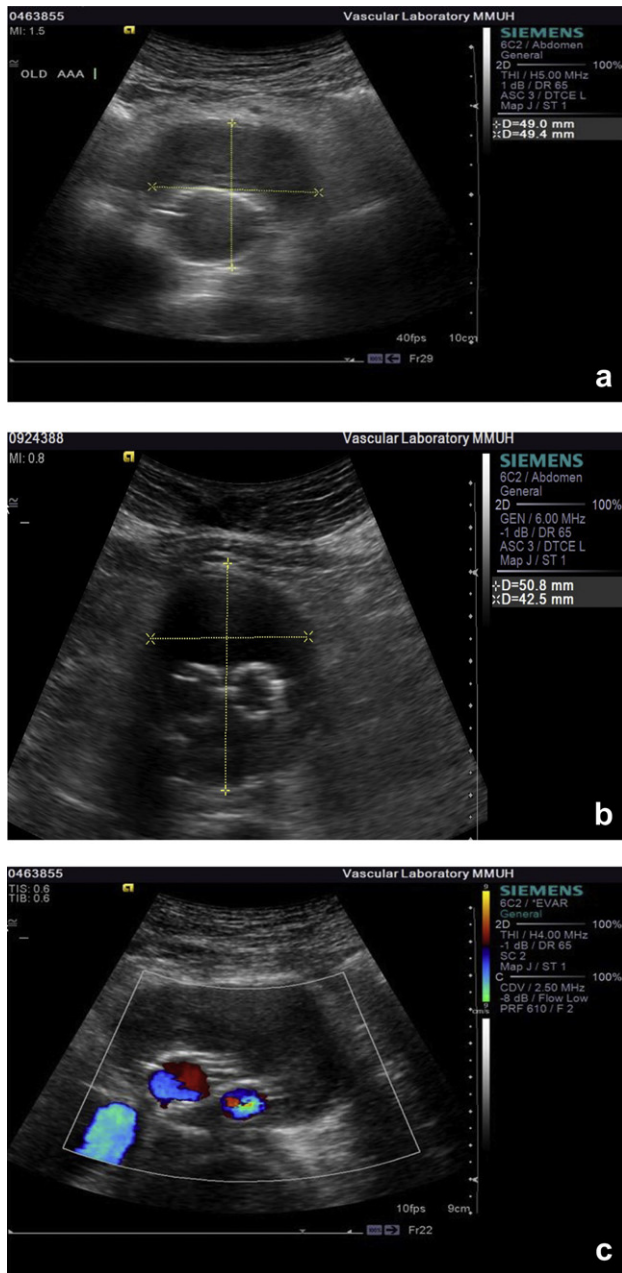


Figure 2. CDUS graft surveillance. (a) Measuring residual AAA sac in transverse plane. (b) Imaging of iliac limbs. (c) Colour flow imaging of flow within endograft.

velocity was recorded proximal to the graft, within the body of the graft, at the distal attachment sites and outflow vessels to ensure that there are no flow abnormalities from associated intraluminal defects.

Computed tomography

All CT scans were carried out on a Siemens Somatom Definition AS 128 slice scanner (Siemens AG, Erlangen, Germany) following a standard protocol with 0.75 mm slices and reconstructions performed on all CTs. The maximum residual aneurysm measurement and the presence or absence of an endoleak as reported on the final report was used for comparison. Under our current follow up protocol following EVAR patients undergo 3 CTs in the initial year post graft implantation (post surgery, at 6 months and 1 year) and

annually thereafter, provided there has been no documented endoleak or residual sac increase on either CDUS or CT.

Cumulative cost of CT surveillance

The cumulative expenditure on CT surveillance per year following the current algorithm was calculated assuming a cost of €500 per CT scan, based on 2010 costings. Calculating the cumulative number of scans necessary per year assumed that all patients underwent only 1 scan per annum after the first year and that no patient died or was lost to follow up. The reduction in CT cost was then calculated assuming that patients undergo just 1 CT post graft implantation and are then followed up solely with CDUS. The additional cost of providing an abdominal X-ray (€85 based on 2010 costings) as part of a CDUS based surveillance protocol was also taken into account.

Statistical analysis

Sensitivity, specificity, positive predictive value and negative predictive value were calculated for CDUS, taking CT as the gold standard. The patient was considered a false negative if CDUS missed an endoleak that CT detected, a false positive if CDUS detected an endoleak that CT did not; a true positive if the endoleak was detected by both CDUS and CT and a true negative if CDUS and CT documented no endoleak.

The Pearson Coefficient Correlation was performed to assess the strength of the relationship between CDUS and CT in the measurement of the residual aneurysm sac size post repair. All calculations for Pearson coefficient correlation were performed using Windows Microsoft Excel 2007. Level of agreement (LOA) was performed with the method described by Bland and Altman¹⁰ and was calculated using MedCalc statistical software from the means and differences of the two measurements. Accepted value for LOA is between -0.5 and 0.5 cm, which are the values between which 95% of the measured differences are expected to fall.¹¹

Results

Endoleak detection and classification

Of the 484 scans available for comparison (242 pairs) an endoleak was documented on 87 CDUS scans and 25 CTs.

Type 1 endoleaks

There were 5 (2.1%) type 1 endoleaks noted on CDUS, 3 (1.2%) of which were detected on CT and subsequently confirmed by arteriography. There were no type 1 endoleaks noted on CT that were missed on CDUS. Of the two patients who had a type 1 endoleak on CDUS and not on CT, one was an anatomical abnormality and misinterpreted on the CDUS scan. The second patient was documented as a type 2 endoleak on CT. Four of the five patients who had a type 1 endoleak detected on CDUS underwent further intervention.

Type 2 endoleaks

Type 2 endoleaks were detected in 82 (33.9%) of CDUS scans and in 22 (9.0%) of CTs. In no case was a type 2 endoleak detected on CT and not detected on CDUS. Three patients with a documented type 2 endoleak on both imaging modalities underwent further intervention.

Type 3 endoleak

There were no type 3 endoleaks detected in this series on either CT or CDUS.

Table 1
CT and CDUS for endoleak detection.

	CT positive	CT negative
Duplex positive	25	62
Duplex negative	0	372

Type 4 endoleak

There were no type 4 endoleaks noted in the series on either CT or CDUS.

Endotension

One patient underwent further intervention for endotension. Both imaging modalities documented a significant increase in residual aneurysm sac size. CDUS documented the presence of a type 2 endoleak originating from a lumbar artery but no patent vessel was noted on CT or selective angiography. The patient underwent conversion to open repair where no patent feeding vessel was identified and the sac was plicated over the endograft.

Sensitivity, specificity, positive predictive value and negative predictive value

CDUS was found to have a sensitivity of 100% and a specificity of 85.7% in the detection of endoleaks. The positive predictive value was 28.7% and negative predictive value 100% (Table 1).

Residual aneurysm sac measurement

Of the 484 scans (242 pairs) available for comparison, the residual AAA sac size was not documented on 15 (6.1%) CDUS scans due to the presence of excess bowel gas and body habitus limiting image quality and on 91 (37%) of the 242 CT scan reports.

This gave a total of 142 (58%) pairs of scans where both the CDUS and the CT could be compared for accuracy in determining the residual AAA diameter post EVAR.

There was no statistically significant difference between the two imaging modalities with mean (\pm SD) residual AAA diameter on CDUS being 5.5 (\pm 1.4) and on CT 5.6 (\pm 1.6) cm ($p = 0.99$). The Pearson Coefficient correlation was found to be 0.96 indicating a large degree of correlation between CDUS and CT when measuring residual aneurysm size following EVAR (Fig. 3).

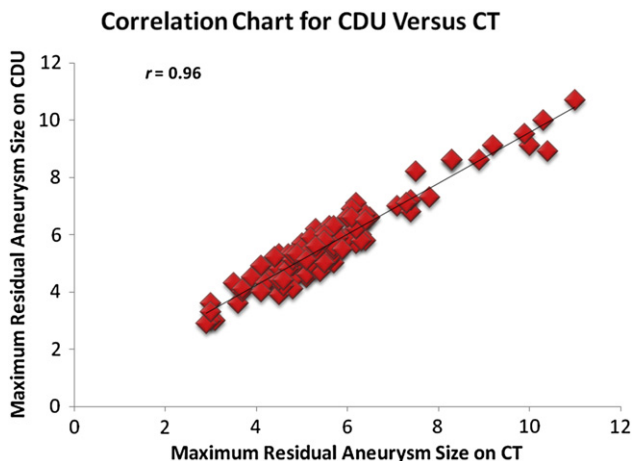


Figure 3. Correlation of CT and CDU in determination of residual AAA sac size following EVAR.

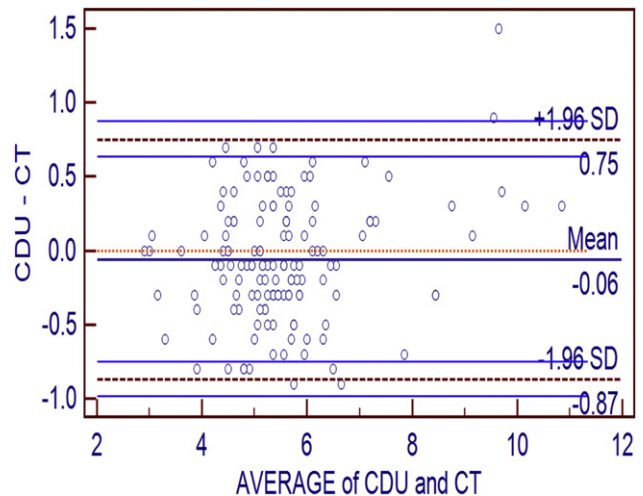


Figure 4. Bland and Altman plot for CDU versus CT in the measurement of the residual aneurysm size following EVAR. Indicating that 95% of the confidence interval ranges from 0.87 to 0.75.

A Bland and Altman plot of the differences against the average of the two measurements of residual aneurysm size post EVAR is presented in Fig. 4. The mean differences between CDUS and CT are plotted against the mean aneurysmal diameter. The limits of agreement ($-0.87-0.75$) represents the range within 95% of the differences would be expected to occur, and were calculated as the mean \pm 1.96 times the standard deviation of the differences. Just 4 patients (2.8%) fell outside the tolerance interval.

Effect of application of CDUS-first protocol on number and cost of post-EVAR surveillance CTs

In 2010, adopting a protocol where CDUS and AXR was employed as the first line surveillance tool following EVAR would result in a reduction in the number of postoperative CTs required from 235 to 36 (Fig. 5). Based on 2010 costings, this would equate to an estimated reduction in expenditure from €117,500 to €34,915 a saving of €82,585 (Fig. 6).

Discussion

CDUS is universally accepted as the method of choice for both AAA screening and small AAA surveillance. The lack of associated radiation exposure and nephrotoxicity as well as the obvious advantage of being readily available, non-invasive and less expensive make it a more desirable imaging modality for long term surveillance. However, it is largely operator dependant and the quality of images can be adversely affected by the patient's body habitus and excess bowel gas.

Our results show an excellent degree of correlation ($r = 0.96$) between CDUS and CT in measuring residual aneurysm sac size following EVAR. These results compare favourably to the degree of correlation reported previously by Raman ($r = 0.65$) and Arko ($r = 0.93$).^{12,13} The level of agreement was also satisfactory with 95% confidence interval ranging from $-0.87-0.75$ (Fig. 4), although this differs somewhat from the figures previously reported by Sprouse.¹¹ The incidence of inconclusive CDUS results of 6% in this series is considerably lower than the 25% reported elsewhere¹⁴ and is possibly a reflection of the prolonged 6 h fasting time required prior to CDUS scanning.

The sensitivity of CDUS for the detection of endoleaks of 100% and specificity of 85% differs somewhat to figures reported

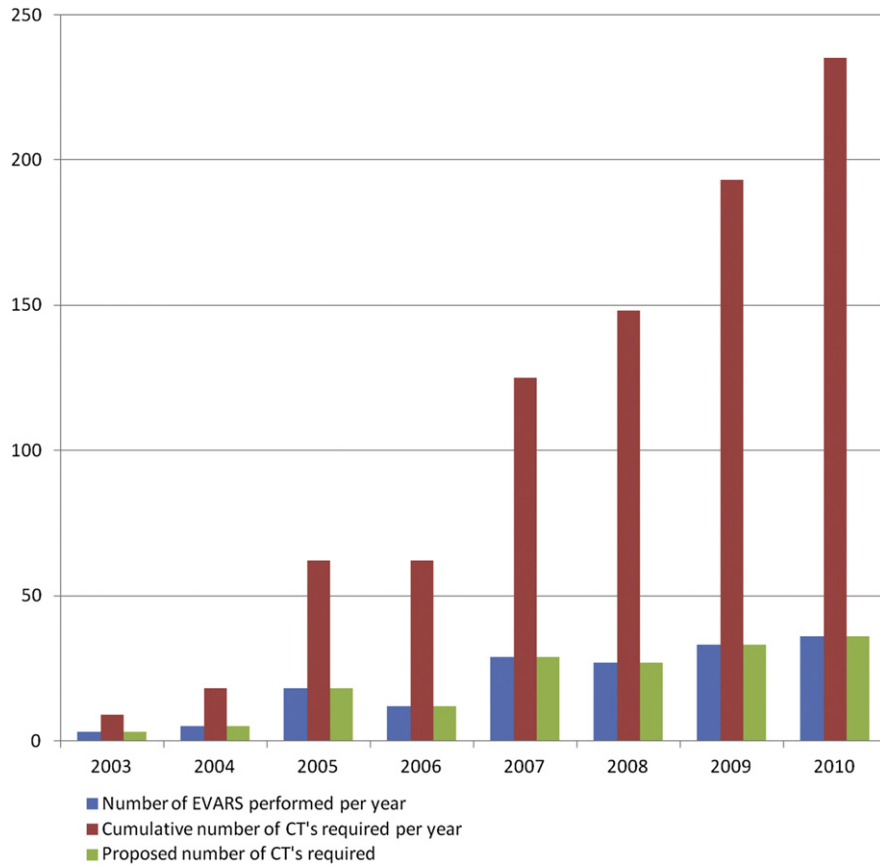


Figure 5. Impact of a CDU-First algorithm on CT scan requirement.

elsewhere in the literature. Sanford reported 67% sensitivity and 91% specificity for CDUS versus CT in the detection of endoleaks with a positive predictive value of between 33 and 100% and negative predictive value of between 91 and 100%.⁴ The positive

and negative predictive values in this study were similar at 28% and 100% respectively. Arko reported a sensitivity of 81%, a specificity of 95%, a positive predictive value of 94% and a negative predictive value of 90% for CDUS when compared to CT but critically, they

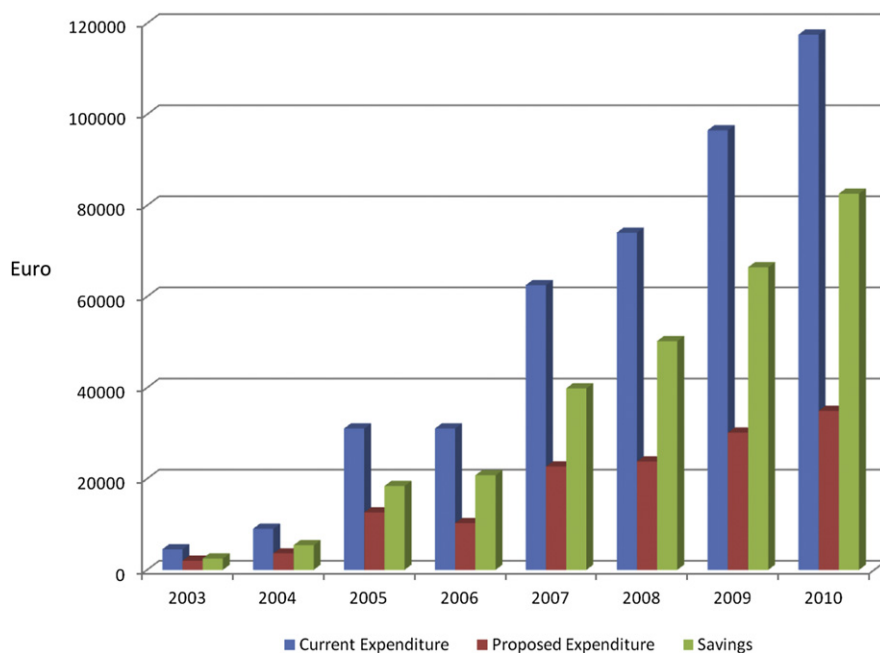


Figure 6. Estimated savings in CT expenditure (MMUH series 2003–2010).

documented a small number of endoleaks present on CT that were missed on CDUS.¹³ In this study, there were no endoleaks which were detected on CT but missed on CDUS. Manning and colleagues, in a series of 132 patients reported values similar to our own, documenting a 45% positive and 94% negative predictive value for CDUS when compared to CT for postoperative surveillance following EVAR. Specificity of CDUS for endoleak detection was 67% when compared with CTA and sensitivity for CDUS was 86%. Their conclusions were broadly similar, suggesting CDUS as a first line screening tool which allowed selection of a smaller cohort of patients in whom CT was necessary.⁸

Henao and colleagues described how CT failed to recognize three type II endoleaks seen by contrast-enhanced ultrasound.¹⁵ A study performed by Civitello and colleagues in 2003 concluded that contrast enhanced CDUS is more accurate than standard CDUS for the detection of endoleaks following AAA repair.¹⁶ As our current scanning protocol has already detected all clinically significant endoleaks it is difficult to see how patient care would be optimised by the use of contrast enhanced ultrasound and thus it has not been adopted as part of our surveillance protocol. Others, however, have reported that the accuracy of contrast-enhanced CDUS was markedly better than CDUS alone and similar to CTA and MRA.¹⁷ Although some have advocated MRI as the surveillance modality of choice following EVAR,^{17,18} this would undoubtedly increase the cost of surveillance and therefore we would regard it as an acceptable second-line imaging tool where CDUS is equivocal or inadequate.

One limitation of CDUS is in the detection of structural abnormalities within the endograft. The replacement of CT with CDUS as a surveillance tool would remove the capability of structural imaging of the endograft using CT reconstruction and thus mandate the inclusion of an abdominal X-ray as part of any new protocol.

While these results suggest that CDUS could be employed as the primary postoperative surveillance tool following EVAR, certain findings should be indications for proceeding to CT, e.g. increase in sac size, detection of high velocity flow within the aneurysm sac suggestive of an endoleak, structural abnormalities in the graft or inability to obtain adequate pictures of the graft with CDUS. On the basis of the very basic calculations contained in this study, adoption of this protocol would lead to a significant reduction in the number of CT scans required as part of the postoperative surveillance programmes with a resultant reduction in exposure to both ionising radiation and intravenous contrast and a significant cost saving. Almost one-third of the cost of postoperative EVAR can be attributed to radiology imaging costs.¹⁹ Beeman reported cost savings of \$1595 per patient per year by replacing CT surveillance with CDUS.¹⁹

Conclusion

CDUS combined with plain abdominal X-ray could safely replace CT as the primary long term surveillance imaging modality for patients post EVAR, resulting in significant cost-saving without loss of scan accuracy. The identification of abnormalities on the CDUS scan should be the indication to proceed to CT in a smaller group of

patients thus reducing the radiation and contrast exposure to the patient and the cost of follow up.

Conflict of Interest/Funding

None.

References

- Greenhalgh RM, Brown LC, Kwong GP, Powell JT, Thompson SG. EVAR trial participants comparison of endovascular aneurysm repair with open repair in patients with abdominal aortic aneurysm (EVAR trial 1). *Lancet* 2004;**364**(9437):843–8.
- Prinssen M, Verhoeven EL, Buth J, Cuypers PW, van Sambeek MR, Balm R, et al. A randomised trial comparing conventional and endovascular repair of abdominal aortic aneurysms. *N Engl J Med* 2004;**351**(16):1607–18.
- Chaer RA, Gushchin A, Rhee R, Marone L, Cho JS, Leers S, et al. Duplex ultrasound as the sole long term surveillance method post endovascular aneurysm repair. A sole alternative for stable aneurysms. *J Vasc Surg* 2009;**49**(4):845–9.
- Sanford RM, Brown MJ, Fishwick G, Murphy F, Naylor M, Sensier Y, et al. Duplex screening is reliable in detection of endoleak following endovascular aneurysm repair. *Eur J Vasc Endovasc Surg* 2006;**32**:537–41.
- The UK Small Aneurysm Trial Participants. Mortality results for randomised controlled trial of early elective surgery or ultrasonographic surveillance for small abdominal aortic aneurysms. *Lancet* 1998;**352**:1649–55.
- The Multicentre Aneurysm Screening Study Group. The Multicentre Aneurysm Screening Study (MASS) into the effect of abdominal aortic screening on mortality in men: a randomised control trial. *Lancet* 2002;**360**:1531.
- Moll FL, Powell JT, Fraedrich G, Verzini F, Haulon S, Waltham M, et al. Management of abdominal aortic aneurysms clinical practice guidelines of the European Society for Vascular Surgery. *Eur J Vasc Endovasc Surg* 2011;**41**:S1–58.
- Manning BJ, O'Neill SM, Haider SN, Colgan MP, Madhavan P, Moore DJ. Duplex ultrasound in aneurysm surveillance following endovascular aneurysm repair: a comparison with computed tomography aortography. *J Vasc Surg* 2009;**49**(1):60–5.
- Beeman Br, Doctor LM, Doerr K, McAfee-Bennett S, Dougherty MJ, Calligaro KD. Duplex ultrasound imaging alone is sufficient for midterm endovascular aneurysm repair surveillance: cost analysis study and prospective comparison with computed tomography scan. *J Vasc Surg* 2009;**50**(5):1019–24.
- Altman DG, Bland JM. Measurement in medicine: the analysis of method comparison studies. *The Statistician* 1983;**32**:307–17.
- Sprouse 2nd LR, Meier 3rd GH, Lesar CJ, Demasi RJ, Sood J, Parent FN, et al. Comparison of abdominal aortic aneurysm diameter measurements obtained with ultrasound and computed tomography: is there a difference? *J Vasc Surg* 2003;**38**(3):466–71.
- Raman K, Missig-Carroll N, Richardson T, Muluk SC, Makaroun MS. Colour flow duplex ultrasound scan versus computed tomographic scan in the surveillance of endovascular aneurysm repair. *J Vasc Surg* 2003;**38**(4):645–51.
- Arko FR, Filis KA, Heikkinen MA, Johnson BL, Zarins CK. Duplex scanning after endovascular aneurysm repair: an alternative to computed tomography. *Semin Vasc Surg* 2004;**17**(2):161–5.
- Elkouri S, Panneton JM, Andrews JC, Lewis BD, McKusick MA, Noel AA, et al. Computed tomography and ultrasound in follow up of patients after endovascular repair of abdominal aortic aneurysm. *Ann Vasc Surg* 2004;**18**:271–9.
- Henao EA, Hodge MD, Felkal DD, McCollum CH, Noon GP, Lin PH, et al. Contrast-enhanced duplex surveillance after endovascular abdominal aortic aneurysm repair: improved efficacy using a continuous infusion technique. *J Vasc Surg* 2006;**43**(2):259–64.
- Civitello AB, Woodruff A, Mahmood H, Dougherty K, Askins C, Krajcer Z, et al. Contrast enhanced duplex ultrasound improves endoleak detection following endovascular abdominal aortic aneurysm repair. *J Am Coll Cardiol* 2003;**41**(6):39.
- Cantisani V, Ricci P, Grazhdani H, Napoli A, Fanelli F, Catalano C, et al. Prospective comparative analysis of colour duplex ultrasound, contrast enhanced ultrasound, computed tomography and magnetic resonance in detecting endoleak after endovascular abdominal aortic aneurysm repair. *Eur J Vasc Endovasc Surg* 2011;**41**(2):186–92.
- Cornelissen SA, van der Laan MJ, Vincken KL, Vonken EJ, Viergever MA, Bakker CJ, et al. Use of multispectral MRI to monitor aneurysm sac contents after endovascular abdominal aortic aneurysm repair. *J Endovasc Ther* 2011;**18**(3):274–9.
- Noll R, Tonnessen BH, Mannava K, Money SR, Sternbergh 3rd WC. Long term placement cost after endovascular aneurysm repair. *J Vasc Surg* 2007;**46**(1):9–15.