



Technological University Dublin
ARROW@TU Dublin

Articles

2011

Soft Contact Lens-Induced Corneal Warpage

Aoife Lloyd McKernan

Technological University Dublin, aoifemarie.lloyd@tudublin.ie

Luisa Simo Mannion

Plymouth University

Linda Moore

Technological University Dublin

Follow this and additional works at: <https://arrow.tudublin.ie/otpomart>

 Part of the [Optometry Commons](#)

Recommended Citation

Lloyd, A, Simo Mannion, L, O'Dwyer, V. Moore, L., Soft Contact Lens-Induced Corneal Warpage. *Radharc, Journal of Association of Optometrists Ireland*,2011, 4 (1):24-31.

This Article is brought to you for free and open access by ARROW@TU Dublin. It has been accepted for inclusion in Articles by an authorized administrator of ARROW@TU Dublin. For more information, please contact yvonne.desmond@tudublin.ie, arrow.admin@tudublin.ie, brian.widdis@tudublin.ie.



This work is licensed under a [Creative Commons Attribution-Noncommercial-Share Alike 3.0 License](#)



Soft Contact Lens-Induced Corneal Warpage

Aoife Lloyd BSc Optom FAOI; Luisa Simo Mannion, DOO (EU) PhD; Linda Moore BOptom MPhil PhD PGCert (Clin Opt)

Introduction

Soft contact lens wear has become increasingly popular, with improvements in lens design leading to better vision and increased patient comfort (Morgan 2006). This improved comfort can lead to increased wearing times of soft contact lenses, which may result in corneal metabolic problems (Jones 2001; Schornack 2003; Alba-Bueno 2009). This article outlines how this metabolic stress can manifest through changes to corneal structure, and to a decrease in lens tolerance and visual clarity for the patient. An optometrist needs to consider these in order to ensure patient safety, comfort and continued satisfaction with soft contact lens wear.

The effects of soft contact lens wear on the cornea

Soft contact lenses can alter corneal metabolism and structure at all corneal levels. These alterations can manifest as deviations from normal curvature patterns and thickness values. Epithelial thickness can be reduced in long-term wear of low DK soft hydrogel contact lenses (Holden 1985; Gonzalez-Perez 2003). Over-wear of low DK hydrogel lenses has also been shown to lead to corneal oedema, resulting in an increase in overall corneal thickness, haziness and blurring of vision and a myopic shift in the prescription.

Long term exposure to corneal hypoxic conditions can result in changes to endothelial metabolism and variation in endothelial cell size (polymegathism) and shape (pleomorphism) (Carlson 1988; Kaufman 2002). Endothelial changes indicate unstable cell function and a reduction in corneal endothelial health (Lee 2001; Kaufman 2002), which can lead to oedema and contact lens intolerance (Sweeney 1992; Nieuwendaal 1994). Corneal curvature appears to steepen with low-DK hydrogel contact lens wear (Schorner 2010), these changes might be explained by hypoxia-associated corneal thinning.

Changes to corneal topography with silicone hydrogel (SiHy) lenses vary according to the generation of material involved, see table 1 for properties of generation I, II and III lenses. First generation SiHy lenses had low water content, high modulus materials in order to achieve high DK/t values, as the water content was increased in second generation lenses materials became softer and DK/t was reduced, these lenses were for daily wear rather than extended wear. New technology allows third generation SiHy lenses to have high DK/t and low modulus due to increased water content (Szczołka-Flynn 2008).

Topography changes are more prevalent with generation I lenses compared with generation II and III silicone hydrogel lenses (Alba-Bueno 2009), accurate fitting is crucial with these lenses (French 2008). Corneal curvature appears to flatten in high-DK high modulus silicone hydrogel CL wearers (Schorner 2010), this may be associated with a pressure-related flattening of corneal tissue with stiffer silicone hydrogel materials.

Generation	Lens properties	Examples of lenses	Available Base curve (mm)	Available Diameter (mm)
I	- High DK -High modulus -Low water content	PureVision® (Bausch & Lomb, Rochester, USA)	8.3, 8.6	14.0
		Night & Day®(CIBA Vision, Duluth, USA)	8.4, 8.6	13.8
II	-Mid to high range DK -Modulus comparable with hydrogel CL -Higher water content	Acuvue® OASYS™ (Johnson & Johnson, Jacksonville, USA)	8.4, 8.6	14.0
		Acuvue® Advance™ (Johnson & Johnson, Jacksonville, USA)	8.3, 8.7	14.0
		Air Optix® (CIBA Vision, Duluth, USA)	8.6	14.2
III	-High DK -Low modulus -Higher water content	Clariti™ (Sauflon, London, UK)	8.4	14.0
		Biofinity® (Coopervision, Rochester, USA)	8.6	14.0
		Avaira® (Coopervision, Rochester, USA)	8.4, 8.5	14.2

Table 1: Summary of generation I, II and III silicone hydrogel lenses.

The effects of soft contact lens wear on the quality of vision

Corneal transparency is dependent on the regular arrangement and uniform diameter of collagen fibrils in the stroma, and is highly sensitive to even small changes in corneal structure. If there is damage to the endothelial or epithelial barrier systems the stroma imbibes fluid. The resulting oedema leads to a loss of transparency as light rays traveling into the eye are scattered in different directions, causing symptoms of glare, known as ‘Sattler’s veil’(Kaufman 2002). Small increases in myopic refractive error (known as ‘myopic creep’) are associated with low DK hydrogel materials (Hoyos 2002; Sweeney 2003), this can lead to blurred distance vision which is evident with over-wear of hydrogel lenses, and can remain following lens removal, known as ‘spectacle blur’.

Prolonged wear of soft contact lenses, can result in alterations to corneal curvature which can manifest as contact lens induced- corneal warpage. Corneal warpage was first described in the literature by Hartstein in 1968, and has been defined as “a reversible or permanent change in corneal topography that is not associated with corneal oedema” (Wang 2002). This corneal change may be produced through long periods of contact lens wear and is particularly evident with Rigid Gas Permeable (RGP) contact lens wear, but has also been seen in low DK soft hydrogel contact lens wear (Michaud ; Klyce 1991; Ryan 1996; Schornack 2003; Tseng 2007).

Contact lens warpage can result in refractive error changes, which manifest as an increase in myopia and can also result in a decrease to previous innate corneal astigmatism (Hoyos 2002). Overall, this can lead to a reduction of surface regularity (Liu 2000), which can reduce the best corrected spectacle visual acuity (Baker-Schena 2001).

The resulting corneal topography patterns are often similar to those seen in the early stages of keratoconus, these can include irregular central astigmatic topography with a loss of radial symmetry and prolate shape (central steepening and peripheral flattening), inferior

steepening with or without an oblique cylinder axis. Inferior topography values which are >1.50D steeper than superior values are considered suspicious of both corneal warpage and forme fruste keratoconus (Cigales and Hoyos 2002). Steep topography (values greater than 47D (7.18mm) and corneal thinning (pachymetry of less than 500 µm) is not commonly seen with corneal warpage and is indicative of forme fruste keratoconus (Rao 2002; Wang 2006; Belin 2007).

As hydrogel-induced corneal warpage can mimic keratoconus, if suspicious topography is detected it is recommended that stable serial topography and keratometry measurements, as well as manifest refraction (without the use of cycloplegic drugs) be taken on a weekly basis to ensure correct diagnosis (Tseng 2007). The assessment of corneal stability can be performed or monitored using traditional methods such as manifest refraction and keratometry, however, the analysis of corneal curvature using topographers and pachymetry appear to be more accurate methods for monitoring corneal changes (Ng 2007).

The clinical criteria that can be followed when monitoring corneal stability are described in Table 2. Refraction and keratometry are likely to stabilize after a period of 2 weeks while the assessment of pachymetry and corneal curvature (using a topographer) could take a further 2-4 weeks to show that corneal changes are stable (Ng 2007). This is of special relevance when refractive surgery is being considered as the risk of developing corneal ectasia after surgery is greatly increased. Therefore, corneal topography is an important tool to aid the practitioner in the diagnosis and monitoring of corneal changes related to contact lens wear and to rule out the presence of early keratoconus.

Method of assessment	Criteria for stabilization (comparison established against previous clinical measurements) to last visit's measurement)
Manifest refraction	Spherical equivalent with < -0.50 D change Cylindrical refraction with < -0.50 D change
Keratometry	Change of < -0.50 D in both the horizontal or vertical Axis
Corneal topography	Change of < -0.50 D within the central 3mm cornea in both the steep and flat meridians
Pachymetry	< 8 µm change at the thinnest Point

Table 2: Criteria for assessing successful corneal stability following cessation of CL wear. (Adapted from Ng et al 2007)

Time to resolution of soft contact lens warpage

Time to resolution of soft contact lens warpage can vary between 1 week and 2 months (Schornack 2003). The longest time periods required for resolution of corneal warpage have been found with low DK hydrogel lenses worn over extended time periods (Wang 2002; Ng 2007). Wang et al. (2002) found these recovery times with low DK hydrogel lenses (average time being 11.6 weeks) to be longer than those with RGP wear (average 8.8 weeks).

Management

Presenting symptoms may vary with corneal warpage, some patients may report poor and fluctuating vision, ocular discomfort with contact lenses, while some patients may be asymptomatic (Weissman 2007). It is recommended to cease contact lens wear and to

repeat refraction, keratometry and topography measurements on a weekly basis until the corneal distortion has resolved. Refitting with a higher DK lens usually allows patients to return to contact lens wear and corneal topography should be monitored at regular contact lens after care appointments. Long-term wear of silicone hydrogel materials is proven to maintain good ocular health (Guillon 2005), and corneal topography has been shown to remain stable with baseline measurements in daily wear of silicone hydrogel lenses (Alba-Bueno 2009).

Measurement of corneal shape

Keratometry

The keratometer is most commonly used in optometric practice to measure corneal curvature. This instrument measures the distance between the images of two perpendicular pairs of points reflected from a 3mm annulus of para-central cornea and provides the average steep and flat curvature values for this area of the cornea, thus these are average values based on four points only in the central 3mm and therefore can lead to inaccuracies when considering the shape of the entire cornea which is covered by soft contact lenses (Klyce 1991). Keratometry mires become distorted in keratoconus, however in the early stages of keratoconus there may be no clinical signs evident with the use of keratometry (Corbett 2000).

Corneal topography

Topography is used for the assessment of corneal height and radius of curvature data from the entire cornea. Corneal topography provides the practitioner with information from thousands of points on the corneal surface, therefore providing a more comprehensive understanding of the overall corneal shape. For this reason, corneal topography is of special importance in screening and monitoring corneal disease such as keratoconus, contact lens fitting, assessing patient suitability for refractive laser surgery and post-operative outcomes. Topography data can be expressed in two ways: sagittal (axial) or tangential (instantaneous) curvature. These two methods of calculation are quite similar at the centre of curvature, but the tangential curvature becomes greater than the axial towards peripheral corneal points. Therefore, sagittal topography is used for screening for pathology, whereas tangential topography provides more detail in the periphery and is used to obtain information on local irregularities in corneal shape such as those induced by refractive surgery, contact lens wear or ectasia (Klein 1995).

Conclusion

In conclusion, patients with soft contact lens induced corneal warpage can present with visual complaints and topographical changes. Management of corneal warpage includes the cessation of contact lens wear until stability of corneal measurement can be achieved followed by a refit with high DK/t lens materials.

The following case report has been included to demonstrate how soft hydrogel contact lens wear can lead to visual instability, discomfort and changes in the corneal structure. A description of the management has also been included.

Case report

A 25 year old female foreign student who was studying for a research masters presented with complaints of unstable vision with glasses and contact lenses. Towards the end of the day vision was becoming blurred and this was especially evident when using the VDU. In the last six months her contact lenses had begun to irritate the eyes, becoming dry and uncomfortable with prolonged wear. She had attended her optometrist abroad three months previously, at which time Forme Fruste Keratoconus was suspected. The patient was given a referral letter and advised to return for repeat topography in order to confirm the diagnosis. As the student was returning to Ireland to start the new college term she did not follow up on this advice and continued soft contact lens wear throughout. She presented to her appointment wearing monthly-disposable hydrogel toric contact lenses. She had been a soft lens wearer for nine years and had tried several different types of toric lenses due to problems with comfort while wearing her lenses. Her reported contact lens wearing time was five days a week between 8 and 15 hours per day.

Slit lamp biomicroscopy of the conjunctiva, limbus and cornea revealed no clinically relevant findings. Examination of the lid margins revealed grade three meibomian gland dysfunction in both eyes. The lenses appeared to be well centered and had full corneal coverage, with axis marking stable on blink and aligned at 6 o'clock. Lens movement was 0.2mm on blinking with a push-up test of 55% (slightly tighter than ideal fit) in both eyes. A slight amount of myopic shift was found between manifest refraction and previous spectacle prescription which was one year old. She had her lenses in for 30 minutes prior to her appointment.

The relevant findings of the examination are summarised in table 3.

Prescription type	Date	Prescription	Visual acuity
Manifest refraction	Visit 1	RE: -9.50/-1.00*106 LE: -10.00/-1.50*70	6/5- 6/6
Previous Spectacles	1 year	RE: -9.25/-1.00*106 LE: -9.50/-1.50*70	6/5- 6/6-
Contact lens	3 months	RE: 8.7/14.5/-8.00/-1.75*90 LE 8.7/14.5/-8.50/-2.25*70	6/6 6/7.5+1
Lens type: Biomedics® Toric (Coopervision, Rochester, USA), lens material Ocufilecon DIV 1, 55% water content, DK 19/14, Central thickness 0.11mm			

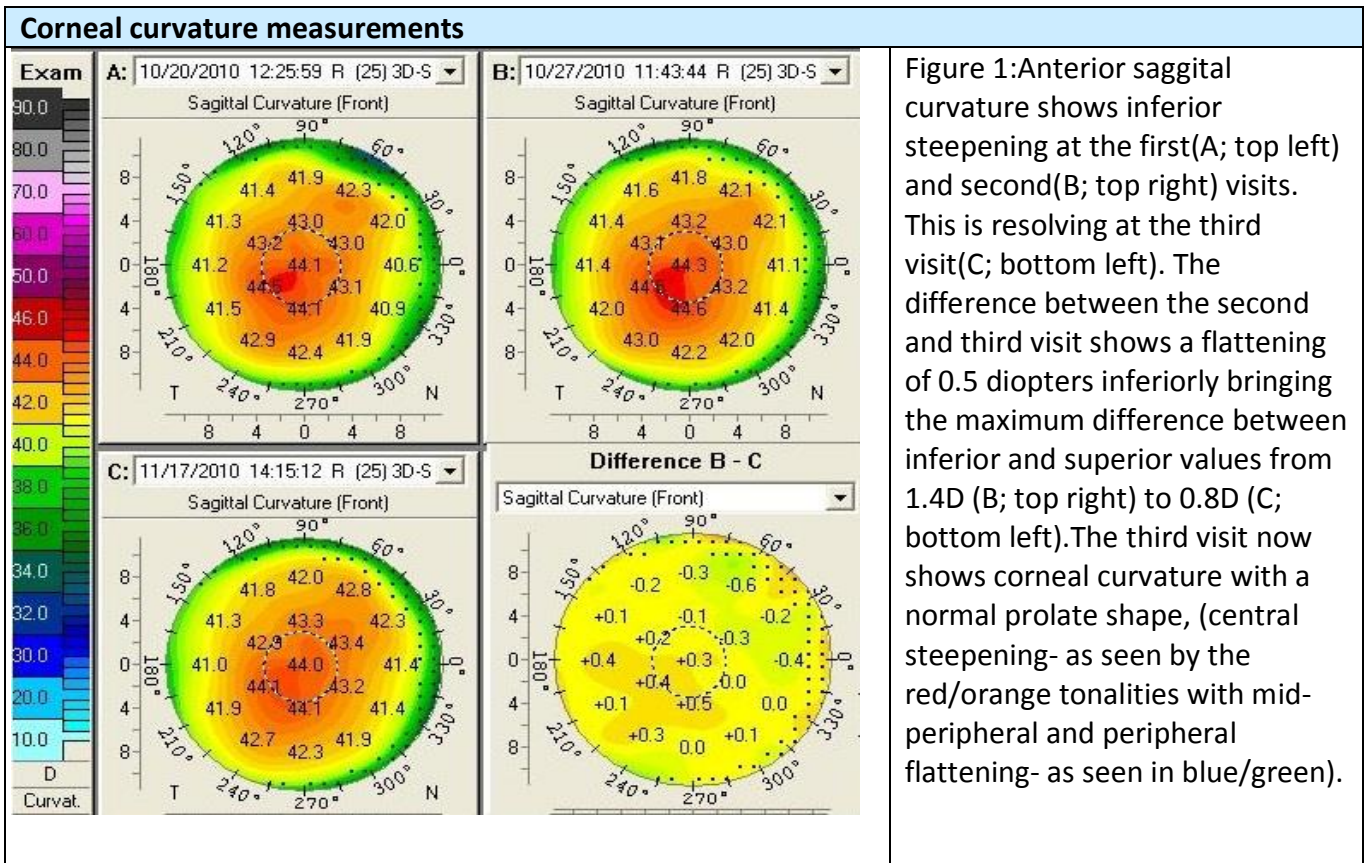
Table 3: Clinical findings at first visit.

Corneal curvature analysis and pachymetry were assessed using a Pentacam instrument (Oculus, Germany). Corneal thickness was found to be above normal levels in both eyes (see figure 3), the worldwide average central corneal thickness value was found to be 534 µm, (Doughty 2000). Corneal oedema related to over-wear of low DK hydrogel lenses was suspected.

Sagittal topography measurements can be seen in Figures 1 and 2. Measurements in the right eye revealed a deviation from the regular normal prolate shape (central steepening and peripheral flattening), with 1.5 D (1.27mm) of inferior-temporal steepening evident (seen in red/orange) accompanied by a superior region of corneal flattening (blue/green), and 1D of inferior steepening in the left eye. It is possible that over wear of the soft hydrogel lenses may have increased the sphericity of the superior cornea.

Simulated keratometry readings	
Visit 1	RE 43.37D (7.78mm) along 126.9° and 44.0D (7.66mm) along 36.9° LE 43.50D (7.77mm) along 40.1° and 44.25D (7.63mm) along 130.1°
Visit 2	RE 43.50D(7.77mm) along 133.6° and 44.25D (7.63)mm along 43.6° LE 43.75D (7.72mm) along 34.2° and 44.75D (7.55mm) along 124.2°
Visit 3	RE 43.25D (7.79mm) along 139.6° and 44.0D (7.66mm) along 49.6° LE 43.80D (7.73mm) along 27.9° and 44.75D (7.55mm) along 117.9°

Table 4: Simulated keratometry readings



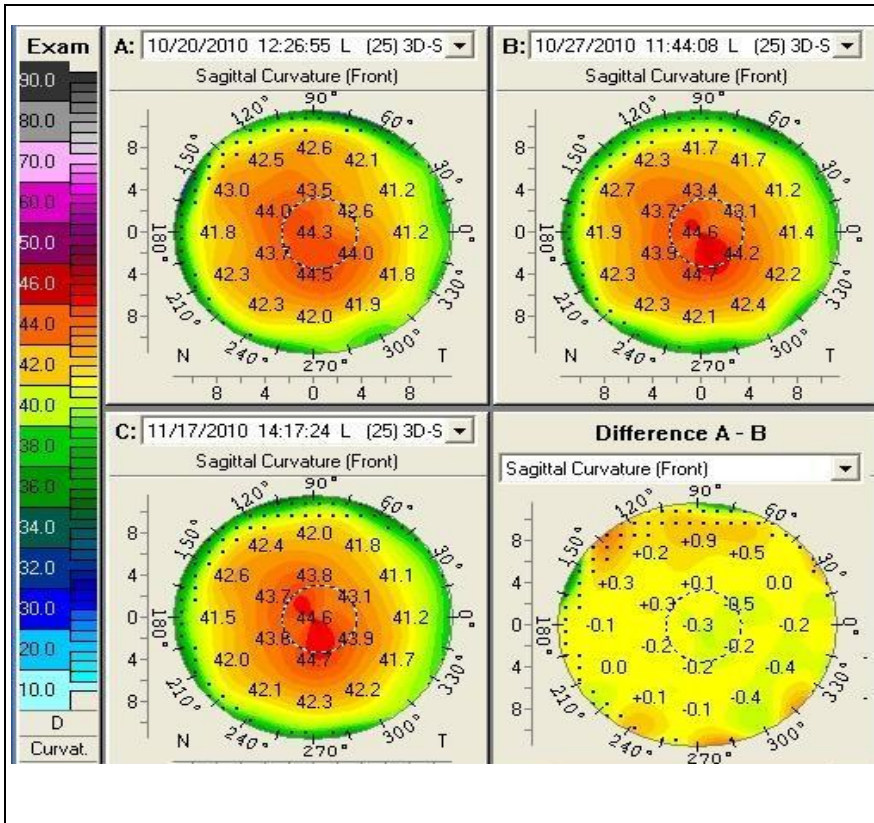


Figure 2: Anterior sagittal curvature shows inferior steepening at the first visit (A; top left) of 1.0D. At the second visit (B; top right) this has increased to 1.3D and the central topography value has become 0.3D steeper, indicating that corneal moulding may have been present due to contact lens wear which was resolving. At the third visit (C; bottom left) central values remain stable and inferior superior values of 0.9D shows corneal curvature was still resolving, the central bow-tie astigmatic pattern appears more balanced at this visit.

The simulated keratometry readings are shown in Table 4. Keratometry values show an amount of corneal astigmatism that was similar to the cylinder in the spectacle refraction, the inferior corneal steepening would not have been evident through use of keratometry alone since this area was outside the keratometer’s limit of resolution.

Due to the patient’s reduced visual stability, the presence of irregular inferior topographical steepening and thick corneal pachymetry the presence of oedema and corneal warpage was suspected. The patient was advised to cease lens wear and begin warm compresses and lid massage treatment for meibomian gland dysfunction. She was asked to return in one week for repeat refraction and corneal curvature analysis. In the mean time she was asked to wear her current spectacles.

At the second visit the patient reported stable and improved quality vision and an improvement in ocular comfort following warm compress and lid massage. Repeated refraction showed a stable result with no change from the previous week. Slit lamp biomicroscopy revealed that there was a reduction in the number of blocked meibomian glands. Repeated corneal curvature (Figures 1 and 2) and thickness analysis was carried out. Sagittal topography in the right eye showed minimal change superiorly and an increase in inferior steepness of 0.5D, the left eye also became 0.7 D steeper, indicating that the contact lenses had caused some degree of corneal moulding which was resolving. There was a large change in pachymetry values with the right eye becoming 36 μm and the left eye 23 μm thinner. Simulated keratometry values remained relatively stable (Table 4).

Corneal thickness measurements

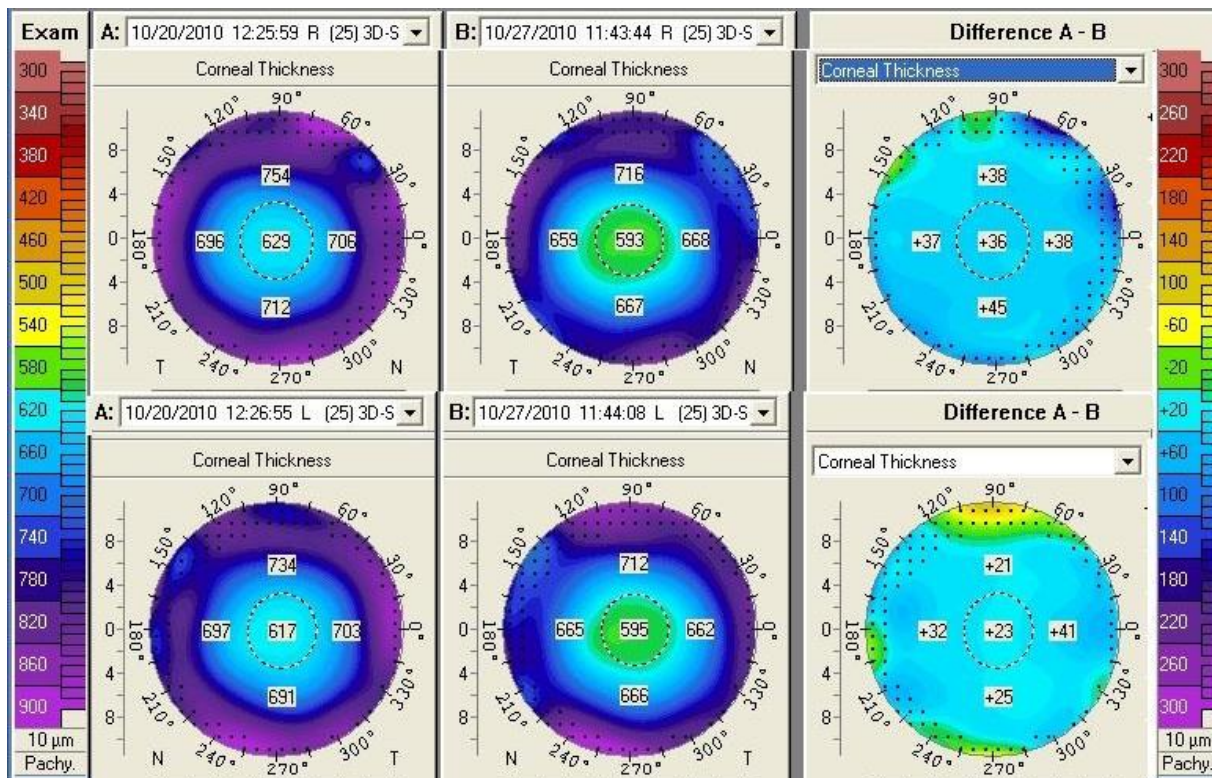


Figure 3: Corneal thickness measurements for the right (top) and left (bottom) eyes at the first (A) visit was above normal limits indicating oedema was present. The reduction in corneal thickness at the second visit (B) confirms the presence of oedema. The change in central and peripheral pachymetry values can be seen on the right.

The patient was keen to return to lens wear, as the oedema and corneal warpage was resolving, she was refitted with a high DK silicone hydrogel lens to be worn on a daily basis. The trial lenses that were dispensed were Air Optix® for astigmatism (Ciba Vision). Rx: RE: 8.7/14.5/-8.50/-1.25*110, LE: 8.7/14.5/-9.00/-1.25*70. Air optix is a second generation silicone hydrogel lens which maintains a modulus(1.00) equivalent to traditional hydrogel lenses but which has high DK/t (110/83) (Purslow 2010), Lotrafilcon B/4 material, 33% water content,.

The patient was instructed to return following two weeks lens wear for aftercare and in order to assess the effect on corneal curvature and pachymetry measurements. At the third visit the patient reported further improvements in ocular comfort and clear stable vision with the new contact lenses. Refraction, simulated keratometry values and corneal thickness measurements remained stable to the second visit. As there was little improvement in visual acuity values with the manifest prescription and as the patient wished to return to contact lens wear she was advised there was no need to update her current spectacles. Topography continued to change returning to normal prolate shape (Figures 1 and 2). The new contact lens prescription was dispensed to the patient and an annual follow-up was scheduled for one year, the patient was advised to continue using lenses on a daily basis and advised not to sleep in them. She was advised to keep to a maximum daily wearing time of 14 hours per day and if she experienced any symptoms of blurred vision or ocular discomfort to cease lens wear and return for a checkup.

Conclusion

It can sometimes be difficult to ascertain the cause of reduced vision and comfort with soft contact lenses, especially in the case of long term wear. Corneal warpage should be suspected even if keratometry values appear normal. Corneal topography and pachymetry can be useful tools to aid in the detection of corneal metabolic stress such as oedema and corneal warpage, and to monitor its resolution.

References

- Alba-Bueno, F., Beltran-Masgoret A, Sanjuan C, Biarnés M, Marín J. (2009). "Corneal shape changes induced by first and second generation silicone hydrogel contact lenses in daily wear." Contact Lens & Anterior Eye **32**(8): 88-92.
- Baker-Schena, L. (2001). "Cornea. Contact woes: managing the big three." American Academy of Ophthalmology. Eye Net Retrieved 04/06/2009, 2009, from www.development.aaopt.org.
- Belin, M., Khachikian SS (2007). "Keratoconus: it is hard to define, but..." American Journal of Ophthalmology **143**(3): 500-503.
- Carlson, K. H., Bourne William M, Brubaker Richard F (1988). "Effect of long-term contact lens wear on corneal endothelial cell morphology and function." Investigative Ophthalmology & Visual Science **29**(2): 185 to 193.
- Corbett, M. (2000). "Corneal topography. Basic principles and applications to refractive surgery." Optometry Today: 33-41.
- Doughty, M., Zaman ML (2000). "Human corneal thickness and its impact on intraocular pressure measures: a review and meta-analysis approach " Survey of Ophthalmology **44**: 367-408.
- French, K., Jones L (2008). "A decade with silicone hydrogels: Part 2." Optometry Today **48**(18): 38-43.
- Gonzalez-Perez, J., Gonzalez-Meijome J, Jalbert I, Sweeney D, Erickson P (2003). "Corneal epithelial thinning profile induced by long-term wear of hydrogel lenses." Cornea **22**: 304-307.
- Guillon, M., Maissa C (2005). "Dry eye symptomatology of soft contact lens wearers and nonwearers." Optometry and Vision Science **82**(9): 829--834.
- Hartstein, J. (1968). "Keratoconus that developed in patients wearing corneal contact lenses." Archive of Ophthalmology **80**: 345-347.
- Holden, B., Sweeney Df, Vannas A, Nilsson KT, Efron N (1985). "Effects of long-term extended contact lens wear on the human cornea." Investigative Ophthalmology and Visual Science **26**(11): 1489-1501.
- Hoyos, J., Cigales M (2002) "Topographical and pachymetric changes induced by contact-lenses." Keratomileusis Study Group Journal, 1-8.
- Jones, L., Jones D (2001). "Non-inflammatory corneal complications of contact lens wear." Contact Lens & Anterior Eye **24**: 73-79.
- Kaufman, P., Alm A (2002). The cornea and sclera. Adler's Physiology of the Eye. Mosby. St Louis: 47-103.
- klein, S., Mandell RB (1995). "Axial and instantaneous power conversions in corneal topography." Investigative Ophthalmology and Visual Science **36**(10): 2155-2159.
- Klyce, S. D. (1991). Corneal topography and contact lenses. Commission on Behavioral and Social Sciences and Education (CBASSE).
- Lee, J., Park W, Lee S, Oum B, Cho B (2001). "A comparative study of corneal endothelial changes induced by different durations of soft contact lens wear." Graefe's Archive Clinical Experimental Ophthalmology **239**: 1-4.
- Liu, Z., Pflugfelder SC (2000). "The effects of long-term contact lens wear on corneal thickness, curvature, and surface regularity." Ophthalmology **107**(1): 105-111.

- Michaud, L. "Late development of ectasia or corneal warpage secondary to continuous wear of a SiH lens
" [In the practice. Ciba Vision Silicone Hydrogels](#) Retrieved 04/06/2009, 2009.
- Morgan, P., Efron N (2006). "A decade of contact lens prescribing trends in the United Kingdom (1996-2005)." [Contact Lens & Anterior Eye](#) **29**: 59-68.
- Ng, L., Lee, Myung E, Nguyen A (2007). "Preoperative assessment of corneal and refractive stability in soft contact lens wearing photorefractive candidates." [Optometry and Vision Science](#) **84**(5): 401-409.
- Nieuwendaal, C., Odenthal M, Kok J, Venema H, Oosting J, Riemsdag F, Kijlstra A (1994). "Morphology and function of the corneal endothelium after long-term contact lens wear." [Investigative Ophthalmology and Visual Science](#) **35**: 3071-3077.
- Purslow, C. (2010). "Current materials and care regimes- implications for clinical practice." [Optometry Today](#) 30-39.
- Rao, S., Raviv T, Majmudar PA, Epstein RJ (2002). "Role of Orbscan II in screening keratoconus suspects before refractive corneal surgery." [Ophthalmology](#) **109**(9): 1642-1646.
- Ryan, R., Jacob P (1996). "Corneal warpage: not just for rigid lens wearers." [Contact Lens Spectrum](#)(September 1996): 1-2.
- Schorneck, M. (2003). "Hydrogel contact lens-induced corneal warpage " [Contact lens & Anterior Eye](#)(26): 153-159.
- Schorner, S. (2010) "Some facts about SiHy lenses." [Review of Optometry](#).
- Sweeney, D. (1992). "Corneal exhaustion syndrome with long-term wear of contact lenses." [Optometry and Vision Science](#) **69**: 601-608.
- Sweeney, D. (2003). "Clinical signs of hypoxia with high-Dk soft lens extended wear: Is the cornea convinced?" [Eye & Contact Lens](#) **29**(1): S22-S25.
- Szczotka-Flynn, L. (2008). Looking at silicone hydrogels across generations. [Optometric Management Symposium on Contemporary Eye Care](#).
- Tseng, S., Hsiao JCJ, Chang DCK (2007). "Mistaken diagnosis of keratoconus because of corneal warpage induced by hydrogel lens wear." [Cornea](#) **26**: 1153-1155.
- Wang, M. (2006). Pre-refractive surgery evaluation. [Corneal Topography in the Wavefront Era: A Guide for Clinical Application](#). Tennessee, Wang Vision Institute: 97.
- Wang, X., McCulley JP ,Bowman JW, Cavanagh HD (2002). "Time to resolution of contact lens-induced corneal warpage prior to refractive surgery." [The Contact Lens Association of Ophthalmologists Journal](#) **28**(4): 169-171.
- Weissman, B. (2007). "Corneal warpage." [Review of Optometry](#).