

Gulf of Mexico Science

Volume 30
Number 1 Number 1/2 (Combined Issue)

Article 8

2012

Intestinal Eversion in the Atlantic Sharpnose Shark, *Rhizoprionodon terraenovae*, a Behavior Ubiquitous Among Elasmobranch Fishes?

Barrett L. Christie

The Dallas Zoo and Aquarium at Fair Park

DOI: 10.18785/goms.3001.08

Follow this and additional works at: <https://aquila.usm.edu/goms>

Recommended Citation

Christie, B. L. 2012. Intestinal Eversion in the Atlantic Sharpnose Shark, *Rhizoprionodon terraenovae*, a Behavior Ubiquitous Among Elasmobranch Fishes?. *Gulf of Mexico Science* 30 (1).

Retrieved from <https://aquila.usm.edu/goms/vol30/iss1/8>

This Article is brought to you for free and open access by The Aquila Digital Community. It has been accepted for inclusion in *Gulf of Mexico Science* by an authorized editor of The Aquila Digital Community. For more information, please contact Joshua.Cromwell@usm.edu.

SHORT PAPERS AND NOTES

Gulf of Mexico Science, 2012(1–2), pp. 50–53
 © 2012 by the Marine Environmental Sciences
 Consortium of Alabama

INTESTINAL EVERSION IN THE ATLANTIC SHARPNOSE SHARK, *RHIZOPRIONODON TERRAENOVAE*, A BEHAVIOR UBIQUITOUS AMONG ELASMOBRANCH FISHES?—Rinsing of the spiral colon in sharks via eversion and protrusion through the cloaca has been documented in shark species possessing a scroll or conicospiral type valvular intestine. To date there have been at least 27 observed instances of intestinal eversion in captive sharks (e.g., Crow et al., 1990; Henningsen et al., 2005), though the phenomenon remains poorly known from wild specimens. The literature also documents at least 12 cases of mortality due to valvular intestine trauma from attacks by conspecifics during eversion events (Crow et al., 1991; Henningsen et al., 2005; Schaller and Dunker, 2005). Overall the phenomenon has been documented to occur in eight species of carcharhiniform sharks, including five species of the genus *Carcharhinus*, two species of the genus *Negaprion*, and in *Triaenodon obesus* (Crow et al., 1990). Eversion has also been documented in *Pristis pectinata*, made notable due to the conicospiral morphology of the spiral valve in the sawfishes (Henningsen et al., 2005). Recently eversion was documented in *Manta birostris*, being of great significance as the first published report of eversion in a ray and the first observed incidence in any wild elasmobranch (Clark et al., 2008).

Between 2002 and 2007, as many as 90 young-of-the-year and juvenile Atlantic sharpnose sharks, *Rhizoprionodon terraenovae*, were collected and maintained together in closed, recirculating 152,000 liter seawater aquaria at a public aquarium in Galveston, TX, for 2–6 months before being transferred to various zoological institutions throughout North America. The sharks were fed a varied diet of seafood at a rate of 15% of their collective body weight per week, supplemented with Mazuri® Vita-Zu 5MD8 elasmobranch vitamins. Specimens of *R. terraenovae* were housed with conspecifics, as well as *Carcharhinus limbatus*, *C. brevipinna*, *C. isodon*, and *Sphyrna tiburo*. In accordance with standard aquarium quarantine treatment protocols, while in captivity the specimens were orally administered a prophylactic antihelminthic treatment consisting of 50 mg/kg praziquantel (Sigma-Aldrich), a drug used to expel parasitic worms

from the body. Behavior of the sharks was typically observed for 1–6 hr/wk during and after feedings, during routine tank maintenance, at the beginning and end of each work day, and at sporadic intervals at the discretion of the aquarium staff.

On 18 Aug. 2006 a 294 mm total length young-of-the-year *R. terraenovae* that had been acclimated to captivity and kept for between 30 and 90 days was found dead. Gross necropsy of the specimen revealed that 10 mm of the spiral valve had protruded through the cloaca (Fig. 1A, B), with the spiral valve having been completely amputated 16 mm posterior to the duodenum. The necropsy findings were consistent with the cases described in Crow et al. (1991) and Schaller and Dunker (2005), indicating that the injury was most likely due to attack by another shark. It cannot be determined, however, whether the attack had been made by a conspecific or by one of the other shark species kept in the same tank. On one occasion, 20 April 2007, an individual specimen of *R. terraenovae* was directly observed by the author everting the spiral valve. In the observed incidence, a specimen was noted with the valvular intestine partially everted to a length of approximately 4–6 cm, a condition which persisted for approximately 5 sec prior to retraction. During this time, the shark was noted vigorously shaking its caudal end just prior to retraction of the intestine, sloughing considerable mucous and undigested particles into the water column. A portion of the particles shed during the single observed eversion event were sampled from the tank with a 0.5 mm mesh net affixed to a 2 m handle and were subjected to gross macroscopic examination immediately after the occurrence. Upon gross macroscopic examination this particulate matter consisted mainly of the beaks of *Loligo opalescens*, one of the primary feed items offered to the animals. No cestode proglottids, trematodes, or other gut fauna were noted. A small number of fractured teleost vertebrae and other osteological artifacts were also noted alongside the squid beaks. Microscopic examination was not performed, since the mesh diameter (0.5 mm) did not allow sampling of smaller particles. The mucous that was expelled quickly dissipated in the moderate currents created by the tank's life support systems and similarly could not be examined.

Intestinal biting during eversion events has been documented in carcharhinid sharks and sawfishes from at least five public aquaria (Crow

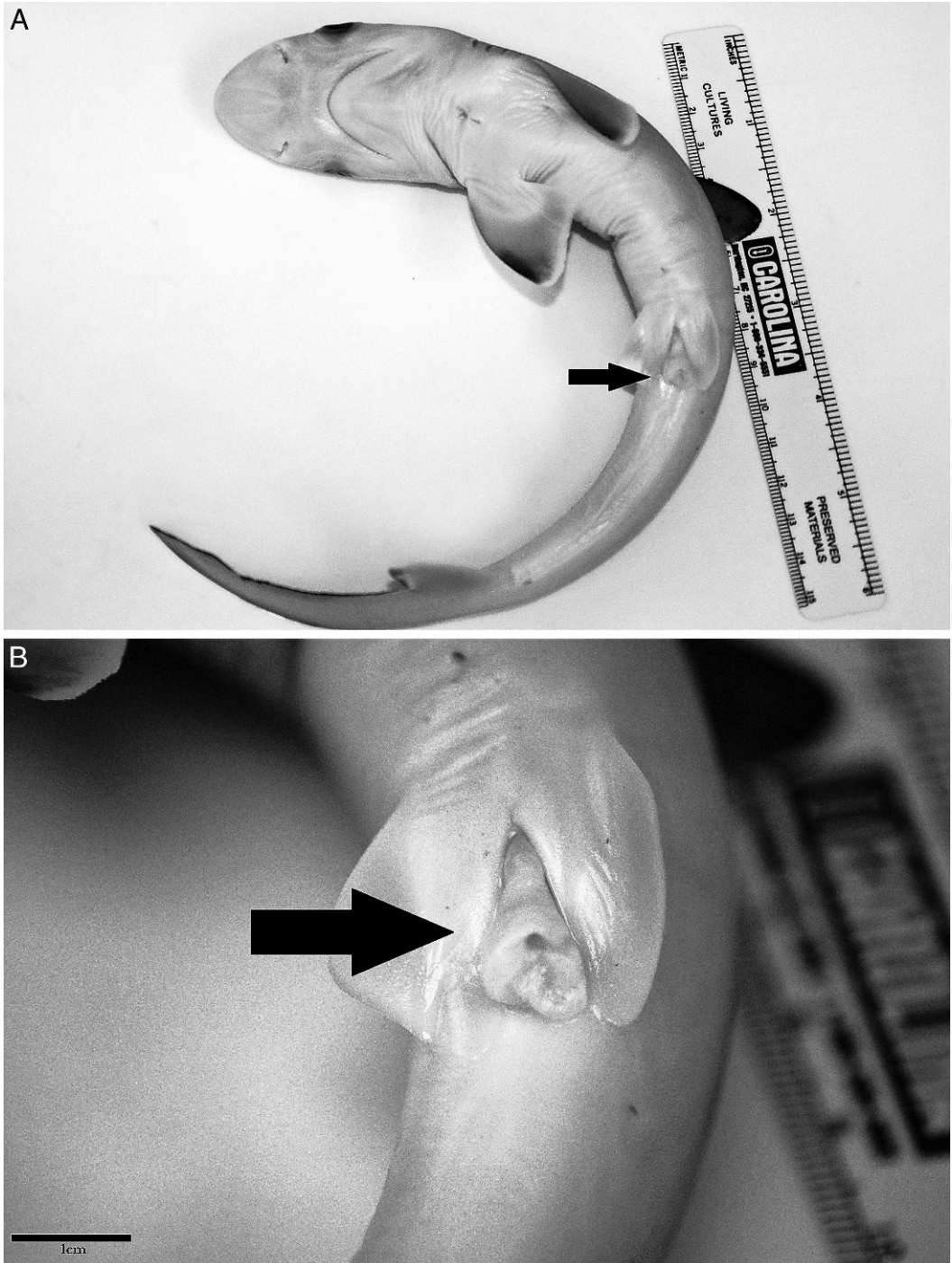


Fig. 1. Young of year *Rhizoprionodon terraenovae*, (A) whole specimen, prior to necropsy. (B) Detail of cloaca showing signs of spiral valve amputation following intestinal eversion. Scale bar is 1cm.

et al., 1991). While the phenomenon of intestinal eversion is scarcely reported in wild elasmobranchs under normal conditions (i.e., when animals are not hooked, netted, or under other

extreme stress), advances in captive husbandry continue to give new insight into shark behavior. Anecdotal accounts of this behavior in healthy captive animals have also recently been commu-

TABLE 1. Documented instances of intestinal (spiral valve) eversion in elasmobranch fishes to date, arranged in phylogenetic order.

Species	Captive/wild	Location ^a	Observations	Reference
Carcharhiniformes: Carcharhinidae				
<i>Carcharhinus galapagensis</i>	Captive	UZG	1	Crow et al. (1990)
<i>Carcharhinus leucas</i>	Captive	SWC, OEA	5	Crow et al. (1990)
<i>Carcharhinus melanopterus</i>	Captive	WAQ, SWC	5	Crow et al. (1990)
<i>Carcharhinus obscurus</i>	Captive	OEA	2	Crow et al. (1990)
<i>Carcharhinus plumbeus</i>	Captive	OEA, NAB	6	Crow et al. (1990)
<i>Negaprion acutidens</i>	Captive	WAQ	1	Crow et al. (1990)
<i>Negaprion brevirostris</i>	Captive	SWC	3	Crow et al. (1990)
<i>Rhizoprionodon terranova</i> ^b	Captive	MGA	2	Present Study
<i>Triaenodon obesus</i>	Captive	WAQ	1	Crow et al. (1990)
Carcharhiniformes: Sphyrnidae				
<i>Sphyrna tiburo</i> ^b	Captive	DAQ	1	Julius (pers. comm.)
Carcharhiniformes: Triakidae				
<i>Mustelis canis</i> ^b	Captive	MSA	1	Hayden-Roderiques (pers. comm.)
Squaliformes: Squalidae				
<i>Squalus acanthias</i> ^b	Captive	MSA	4	Hayden-Roderiques (pers. comm.)
Pristiformes: Pristidae				
<i>Pristis pectinata</i>	Captive	NAB	3	Henningesen et al. (2005)
Rajiformes: Rhinobatidae				
<i>Rhinobatos rhinobatos</i> ^b	Captive	ZMA	1	Gaspar (pers. comm.)
Myliobatiformes: Dasyatidae				
<i>Dasyatis americana</i> ^b	Captive	DTA	3+	Frey (pers. comm.)
Myliobatiformes: Potamotrygonidae				
<i>Potamotrygon motoro</i> ^b	Captive	DAQ	1	Author (pers. obs.)
Myliobatiformes: Myliobatidae				
<i>Manta birostris</i>	Wild	Maui, HI	1	Clark et al. (2008)
<i>Rhinoptera bonasus</i> ^b	Captive	DAQ	3	Author (pers. obs.)

^a UZG = Ueno Zoological Gardens, Tokyo, Japan; SWC = Sea World, San Diego, CA; OEA = Okinawa Expo Aquarium, Okinawa, Japan; WAQ = Waikiki Aquarium, Honolulu, HI; NAB = National Aquarium in Baltimore, Baltimore, MD; MGA = The Rainforest and Aquarium at Moody Gardens, Galveston, TX; DAQ = Dallas Zoo and Aquarium at Fair Park, Dallas, TX; MSA = Maine State Aquarium, West Boothbay Harbor, ME; ZMA = Zoomarine Mundo Aquático, Albufeira, Portugal; DTA = Landry's Downtown Aquarium, Houston, TX.

^b New record.

nicated to the author from a number of elasmobranch species that are not elsewhere recorded. Between 2007 and 2008 observations of eversion in *Squalus acanthias* (n = 4) and *Mustelis canis* (n = 1) at the Maine State Aquarium were noted (A. Hayden-Roderiques, pers. comm. 2009). Eversion has also been observed at Zoomarine Mundo Aquático in Portugal in specimens of *Rhinobatos rhinobatos* (I. Gaspar, pers. comm. 2009) and in numerous specimens of *Dasyatis americana* at the Downtown Aquarium in Houston from 2007 to 2009 (J. Frey, pers. comm. 2009). This behavior has also been observed by staff at the Dallas Aquarium in *S. tiburo*, *Potamotrygon motoro*, and *Rhinoptera bonasus*, the latter having been captured by low-resolution mobile phone camera (pers. obs. and E. Julius, pers. comm. 2011). A comprehensive

account of the species documented to evert the spiral colon is presented in Table 1. The behaviors described above were all exhibited by healthy elasmobranch fishes in captivity; the animals were not under acute stress as occurs during capture, transport, and acclimatization to captivity.

While the exact purpose of intestinal eversion is not known with certainty, it has been hypothesized that the act of everting the spiral colon would serve to flush the organ in the ambient seawater, removing mucous, detritus, and potentially parasite fauna (Crow et al., 1990, 1991). Intestinal eversion has also been implicated in the reproductive strategy of at least one cestode parasite of sharks (Williams et al., 2004). Owing to the paucity of literature on this phenomenon, it is worth noting similarities in the better known

elasmobranch behavior of gastric eversion through the mouth in order to rinse the stomach of mucous and indigestible particles. Gastric eversion has been observed (or artificially induced) in seven species of wild and captive elasmobranchs ranging from skates to requiem sharks (Andrews et al., 1998; Sims et al., 2000; Brunnschweiler et al., 2005) and has recently been documented as being induced by the stress of capture in *Isurus oxyrinchus* (Brunnschweiler et al., 2011).

The findings presented here further support the hypotheses that at least one function of eversion is to free mucous and indigestible particles from the spiral colon, though the current cases cannot as such provide any insight into the role of gastrointestinal parasite fauna in the behavior. It is worth noting, however, that the specimen that was subjected to gross necropsy did not possess any gastrointestinal helminths, as would be expected following deworming treatments. These observations, while noteworthy, do not themselves present compelling evidence that parasite infection intensity may be independent of the occurrence or frequency of intestinal eversion in *R. terraenovae*.

This report serves as the first record of intestinal eversion in *R. terraenovae*, and further contributes to the overall knowledge of this scarcely documented behavior. Given the large number of sharks maintained in this study, this report further supports the theory proposed by Crow et al. (1991) that aquarium stocking density is a factor in intestinal biting incidents. In the current report only a single observed incidence of intestinal eversion is described, though this record in conjunction with the pathological findings of a second case would seem to indicate that this behavior may occur with some frequency in *R. terraenovae*. The anecdotal accounts from public aquaria coupled with the current report would seem to suggest that this behavior may be much more widespread across elasmobranch taxa than has been previously thought, if not ubiquitous.

Acknowledgments.—Thanks to Joshua Frey of the Downtown Aquarium Houston, Aimee Hayden-Roderiques of the Maine State Aquarium, Eric Julius of the Dallas Zoo and Aquarium, and

Zoomarine Mundo Aquatico in Portugal for their accounts of eversion in other elasmobranchs. The author is also indebted to Stephen Walker of the Dallas Zoo, Greg Whittaker of Moody Gardens, and Lori Elliott for critical review of the manuscript.

LITERATURE CITED

- ANDREWS, P. L. R., D. W. SIMS, AND J. Z. YOUNG. 1998. Induction of emesis by the sodium channel activator veratridine in the lesser spotted dogfish, *Scyliorhinus canicula* (Chondrichthyes: Elasmobranchii). *J. Mar. Biol. Assoc. U.K.* 78:1269–1279.
- BRUNNSCHWEILER, J. M., P. L. R. ANDREWS, E. J. SOUTHALL, M. PICKERING, AND D. W. SIMS. 2005. Rapid voluntary stomach eversion in a free-living shark. *J. Mar. Biol. Assoc. U.K.* 85:1141–1144.
- , F. NIELSEN, AND P. MOTTA. 2011. In situ observation of stomach eversion in a line-caught Shortfin Mako (*Isurus oxyrinchus*). *Fish. Res.* 109:212–216.
- CLARK, T. B., Y. P. PAPANASTASIIOU, AND G. C. MEYER. 2008. Intestinal eversion in a free-ranging manta ray (*Manta birostris*). *Coral Reefs* 27(1):61.
- CROW, G. L., J. A. BROCK, J. C. HOWE, AND B. E. LINNON. 1991. Shark bite wounds of the valvular intestine: the cause of an acute mortality syndrome of captive blacktip reef sharks, *Carcharhinus melanopterus*. *Zoo Biol.* 10:457–463.
- , J. C. HOWE, S. UCHIDA, S. KAMOLNICK, M. G. WISNER, AND J. N. CAIRA. 1990. Protrusion of the valvular intestine through the cloaca in sharks of the family Carcharhinidae. *Copeia* 1990(1):226–229.
- HENNINGSEN, A. D., B. R. WHITAKER, AND I. D. WALKER. 2005. Protrusion of the valvular intestine in captive smalltooth sawfish and comments on pristid gastrointestinal anatomy and intestinal valve types. *J. Aquat. Anim. Health* 17:289–295.
- SCHALLER, P., AND F. DUNKER. 2005. Use of contrast radiograph to determine trauma to the valvular intestine in the blacktip reef shark (*Carcharhinus melanopterus*). *Drum and Croaker* 36:23–28.
- SIMS, D. W., P. L. R. ANDREWS, AND J. Z. YOUNG. 2000. Stomach rinsing in rays. *Nature* 404:566.
- WILLIAMS, H. H., M. D. B. BURT, AND J. N. CAIRA. 2004. *Anthobothrium lesteri* n. sp. (Cestoda: Tetrathyphylidea) in *Carcharhinus melanopterus* from Heron Island, Australia, with comments on its site, mode of attachment, reproductive strategy and membership of the genus. *Syst. Parasitol.* 59(3):211–221.
- BARRETT L. CHRISTIE, *The Dallas Zoo and Aquarium at Fair Park, 650 South R.L. Thornton Freeway, Dallas, Texas 75203. EMAIL: BARRETT.CHRISTIE@DALLAS ZOO.COM*