

## Northeast Gulf Science

---

Volume 10  
Number 2 *Number 2*

Article 8

---

8-1989

# An Abnormal Embryo of the Reef Shark, *Carcharhinus perezii* (Poey), from Yucatan, Mexico

Ramon S. Bonfil  
*Instituto Nacional de Pesca, Mexico*

DOI: 10.18785/negs.1002.08

Follow this and additional works at: <https://aquila.usm.edu/goms>

---

### Recommended Citation

Bonfil, R. S. 1989. An Abnormal Embryo of the Reef Shark, *Carcharhinus perezii* (Poey), from Yucatan, Mexico. *Northeast Gulf Science* 10 (2).

Retrieved from <https://aquila.usm.edu/goms/vol10/iss2/8>

This Article is brought to you for free and open access by The Aquila Digital Community. It has been accepted for inclusion in *Gulf of Mexico Science* by an authorized editor of The Aquila Digital Community. For more information, please contact [Joshua.Cromwell@usm.edu](mailto:Joshua.Cromwell@usm.edu).

## AN ABNORMAL EMBRYO OF THE REEF SHARK, *Carcharhinus perezi* (POEY), FROM YUCATAN, MEXICO.


There have been few reports of deformities in elasmobranchs. In the batoids a common deformity is the lack of fusion between pectoral fins and the head, as has been noted for *Raja brachyura* and *R. radiata* by Letaconnoux (1949) and Templeman (1965), and for *Rhynchobatus djiddensis* by Luther (1961). In sharks, two types of deformities have been noted; 1) pre-natal developmental abnormalities usually involving the cephalic region, like those found by Bensam (1965) for *Carcharhinus limbatus* and by Springer (1960) for *C. plumbeus*, and 2) post-natal problems centering on spinal deformities such as scoliosis, centra fusion, and arthritic changes, as have been found in *C. leucas*, *C. plumbeus*, *Sphyrna tiburo*, *Negaprion brevirostris* and *Odontaspis taurus* (Clark, 1964; Schwartz, 1973; Hoenig and Walsh, 1983).

Here we report the occurrence of an abnormal near term embryo of the reef shark *Carcharhinus perezi* that exhibits head deformities involving reduction of snout and number of gill slits, and a ventral positioning of the eyes.

### DESCRIPTION OF THE ABNORMAL EMBRYO.

A near term 590 mm TL embryo of the reef shark *Carcharhinus perezi* weighing 1.226 kg was given to us at a Progreso shark processing factory by Mr. Daniel Cach, 17 April 1985. No information was available on the mother or the rest of the embryos landed the previous day by commercial fishermen at Dzilam de Bravo, Yuc.

The embryo's deformities were



**Figure 1.** Left lateral view of the abnormal *Carcharhinus perezi* embryo from Yucatan, (note snout reduction and lack of first gill opening; depression on side at first dorsal fin level due to straightening procedures after long storage in curved position.)

restricted to the cephalic region (Fig. 1). The snout was one third expected length, lacked nostrils, and exhibited a strong downward coiling slightly bent to the right, resembling a bonnet (Fig. 2). X-radiography revealed a down-turned and deformed chondrocranium reduced to about half expected size (Fig.3). Some splachnochraniun damage was noted by a light shrinkage and deformity of the palatoquadrate and Meckel's cartilage. Additionally, the embryo lacked both first gill slits (Fig.1), but absence of first gill arches could not be determined in the X-radiograph.

Conspicuous were the misplaced eyes. Rather than occurring laterally on



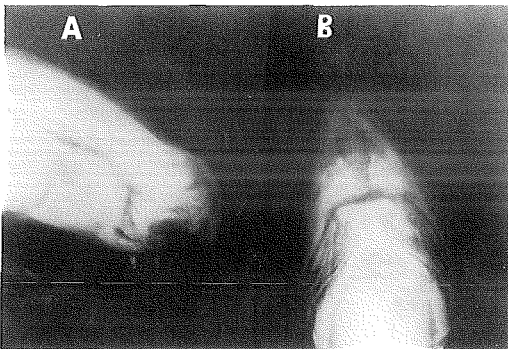
**Figure 2.** Detail of the right side of the head of the abnormal *Carcharhinus perezi* embryo showing snout reduction and coiling, and drift of eyes to ventral position.

the head they were ventrally located just in front of the buccal aperture, and were very close to one another (Fig. 4). The two orbits shared a common large opening, and the nictitating membranes were fused into a single sinuous non functional eyelid, which could not be pulled up to cover the orbits.

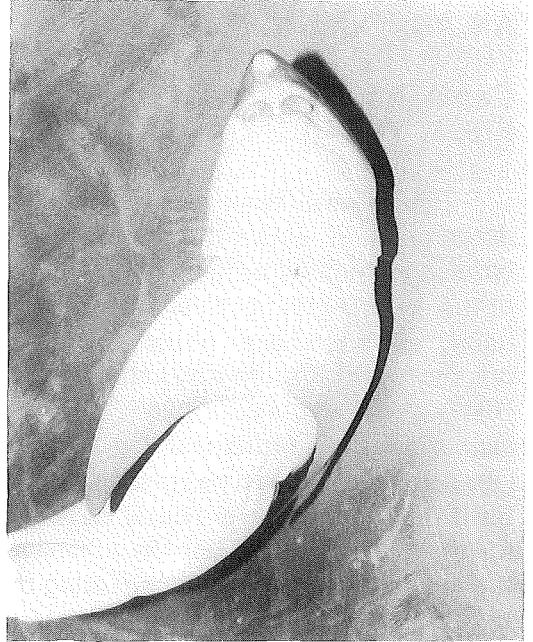
### DISCUSSION.

Case documentation of the infrequent abnormalities found in elasmobranchs provides better appreciation of these phenomena.

The present report seems to be the first record where previously reported abnormalities occurred simultaneously. The embryo of *C. limbatus* described by Bensam (1965) shared the lack of a gill slit with our *C. perezii* otherwise its snout and eyes were normal, although it additionally possessed some trunk and fin deformities not found on our shark. Springer's (1960) *C. plumbeus* embryos, had ventrally placed eyes "... almost in contact with each other ..." just as our specimen, but they differed in having normal snouts and no mouth openings. The *C. plumbeus* sharks reported by Hoenig and Walsh (1983) had only snout deformities but did not lack nostrils. Our specimen was the only abnormal embryo in the



**Figure 3.** X-radiograph of cephalic region of the abnormal *Carcharhinus perezii* embryo showing internal deformities. a) Lateral view. b) Dorsal view.



**Figure 4.** Ventral view of the head of the abnormal *Carcharhinus perezii* embryo from Yucatan, showing position of eyes in front of buccal aperture, fusion of eyelids and lack of nostrils.

litter, a feature in common with Bensam's (1965) account, but differing with Springer's (1960) as he mentioned all embryos in a litter exhibited the same abnormal conditions.

Bensam (1965) surmised that the deformities in the *C. limbatus* embryo were caused by intrauterine pressure exerted by other embryos. This hypothesis was discarded as all fetuses in a uterus are exposed to same space and growth conditions in a same litter, and such conditions would not explain the ventrally positioned eyes and lack of gill opening in our *C. perezii*. It is more likely that some mutation or other developmental irregularity was responsible for the deformities. External factors should have acted equally upon all embryos in the litter. Furthermore, such structured deformities should have arisen early in embryonic development when the head was being formed. Finally it is hypothesised that this embryo wouldn't have survived

long as a free living shark, as it would have had difficulty in feeding, seeing, and detecting olfactory cues.

### ACKNOWLEDGEMENTS

We are greatly indebted with Mr. Daniel Cach Balam, who kindly saved and donated the embryo to us. Mr. Rodolfo Sanchez Flores provided additional information on the origin of the embryo. Steve Branstetter for his valuable comments on the manuscript. Dr. Avelino Paredes and Dr. Santos Buendia from the O'horan Hospital in Merida made it possible for us to take x-ray radiographs.

Springer, S. 1960. Natural history of the sandbar shark, *Eulamia milberti*. U.S. Fish. Wildl. Serv., Fish. Bull. 61:38 pp.

Ramon S. Bonfil, Instituto Nacionalde Pesca, C.R.I.P. Yucapeten A.P. -73, Progreso, Yuc. Mexico 97320.

### LITERATURE CITED

- Bensam, P. 1965. On a freak embryo of the grey shark *Carcharhinus limbatus* Muller and Henle. J. Mar. Biol. Ass. India 7(1):206-207.
- Clark E., 1964. Spinal deformity noted in bull shark. Underwater Nat. 2(3):25-28.
- Hoening, J. M. and A. H. Walsh. 1983. Skeletal lesions and deformities in large sharks. J. Wildl. Diseases 19 (1):27-33.
- Letaconnoux, R. 1949. Quelques Cas Teratologiques chez les Poissons. J. Cons., 16(1):50-58.
- Luther, G. 1961. On an apparently specific type of abnormality in the white spotted shovelnose ray, *Rhynchobatus djiddensis* (Forsk.) J. Mar. Biol. Ass. India 3:198-203.
- Templeman, W. 1965. Some abnormalities in skates (*Raja*) of the Newfoundland area. J. Fish. Res. Bd. Canada 22(1):237-238.
- Schwartz, F. J. 1973. Spinal and cranial deformities in the elasmobranchs *Carcharhinus leucas*, *Squalus acanthias*, and *Carcharhinus milberti*. J. Elisha Mitchel Sci. Co. 89 (1,2):74-77.