

Trabajos de Investigación

MORPHOLOGY OF THE OROPHARYNGEAL CAVITY AND OESOPHAGUS OF THE FARMED ADULT AFRICAN CATFISH (*Clarias gariepinus* BURCHELL, 1822)

**IKPEGBU E¹, EZEASOR DN², NLEBEDUM UC², NWOGU C¹,
NNADOZIE O¹, AGBAKWURU IO¹**

¹Department of Veterinary Anatomy, Michael Okpara University of Agriculture, Umudike, Abia state, Nigeria. ²Department of Veterinary Anatomy, University of Nigeria, Nsukka.

ABSTRACT: *The morphology of the adult farmed African catfish -Clarias gariepinus a prominent omnivorous cultivable species in Nigeria was investigated. It revealed cornified horny plates lining the buccal surfaces of the lips. The tongue was not free moving, and the oesophagus was a narrow tube connecting the oropharyngeal cavity to the stomach with no valve or constriction separating it from the later. Histologically, the cavity wall was lined by stratified squamous epithelium containing eosinophilic club cells, mucous cells and taste buds. The lamina propria contained dense collagen fibres. No taste bud was seen on the tongue suggesting it non involvement in food selection through gustation unlike the cavity wall which contained taste buds. The oesophagus was lined by stratified mucous epithelium containing club cells. Histochemistry revealed the presence of neutral, acid and combination of the two. The large extent of oesophageal mucification indicates need for mucin lubrication of food since teleost is known to lack salivary glands and also an adaptation to ingestion of varied feed.*

KEY WORDS: Oropharyngeal Cavity, Oesophagus, Histology, Histochemistry, Mucin, African Catfish.

MORFOLOGÍA DE LA CAVIDAD OROFARÍNGEA Y ESÓFAGO DEL BAGRE AFRICANO ADULTO (*Clarias gariepinus* BURCHELL, 1822)

RESUMEN: *La morfología bagre africano del adulto cultivado -Clarias gariepinus- una especie omnívoras cultivables prominente en Nigeria fue investigada. Reveló placas córneas que cubren las superficies vestibulares de los labios. La lengua no tiene movimiento libre y el esófago es un tubo estrecho que conecta la cavidad orofaríngea al estómago sin válvula o constricción que lo separe. Histológicamente, la pared de la cavidad estaba revestida por epitelio escamoso estratificado que contiene células eosinófilas, células mucosas y papilas gustativas. La lamina propia contenía fibras de colágeno denso. No fue vista ninguna papila gustativa en la lengua lo que sugiere la no participación la selección de los alimentos a través gustación a diferencia de la pared de la cavidad que contiene papilas gustativas. El esófago estaba revestido por epitelio estratificado que contiene células mucosas. La histoquímica reveló la presencia de ácido a neutro, y la combinación de los dos. La gran extensión de mucificación esofágica indica la necesidad de lubricación de mucina de los alimentos se sabe que los teleosteos carecen de glándulas salivales y también una adaptación a la ingestión de alimentos variados.*

PALABRAS CLAVE: Cavidad bucofaringea, esófago, Histología, histoquímica, mucina, bagre africano

Fecha de recepción: 06/12/12

Fecha de aprobación: 15/01/13

Dirección para correspondencia: IKPEGBU E, Department of Veterinary Anatomy. University of Nigeria, Nsukka E-mail: fikpegbu@yahoo.com

INTRODUCTION

The form and positions of the mouth, dentition on the jaws and oropharynx; and the gill rakers show close relation with the mode of feeding and kinds of food (1, 2, 3). In the *Chondrostoma nasus* L., an herbivorous fish, the ventral mouth position predisposes the fish to help up food overgrowing submerged stones (4).

The lips, the primary food procuring organ assumes different forms and may be adhesive in some teleosts (5). Girigis (6,7) observed a stratum corneum and even horny protuberances on the lips of the herbivorous bottom feeder *Labeo horie*. Two sharp horny cutting edges in the upper and lower borders of the mouth immediately inside the lips enable the fish to take up food. Horny plates on the inner face of the lips in *Noemacheilus barbatulus* L. are used in trituration (8). The granular processes on the very board queer lips of bottom feeding *Pseudogobio esocinus* are important in food finders (9). Bransons and Hake(10) observed the rich vascularization on the lips (and oropharyngeal) tissues of *Piaractus nigripinnis*, indicating a respiratory function in this fish which inhabits water deficient in oxygen. The oropharynx bears a variety of specialized organs for specific functions. The organs include- lamellar organ, buccal valves, tongue, pharyngeal pads and epibranchial organ (11,12,13).

The oesophagus is usually a short and narrow tube connecting the oropharynx to the stomach (14,15,16,17). It is lined by stratified cuboidal to simple columnar epithelium with mucous cells and communicates with the swim bladder through the pneumatic duct in the rainbow trout *Salmo gairdneri* (18), but a psuedostratified epithelium with PAS and AB positive mucous cells has been reported in the *Leporinus taeniofasciatus* (19). The oesophagus of walking catfish *Clarias batrachus* according to Raji and Norouzi (20), presents numerous deep longitudinal folds, lined by few layers of stratified squamous epithelium with numerous superficial mucous cells that changed to columnar epithelium at the end of oesophagus.

African catfish - *Clarias gariepinus*, an omnivorous freshwater fish feeding on zooplanktons, plant debri, other smaller fishes and freshwater animals. It can cannibalize on other catfish in the same pond. It is a popular delicacy in Nigeria. It is a prominent culture species because of its fast growth rate and resistance to diseases and stress factors like over-stocking and poor water quality. It is distributed mainly in fresh waters of Africa, hence the name African catfish, although it is also seen in Asia. It can also thrive in muddy water. It is named 'catfish' because they posses prominent barbels which resemble cat's whiskers. It has a slender body, flat bony head that is dorsoventrally compressed and broad terminal mouth with four

barbels. The pectoral fins have spines.

Despite the increasing interest in the commercial production of the African catfish, there is dearth of information on the morphology of its basic digestive tract, unlike most teleosts in available literature. In this paper we present our findings on the anatomy of the oropharyngeal cavity and oesophagus of the farmed African catfish. The knowledge will enhance our understanding of its adaptive digestive physiology.

MATERIALS AND METHODS

Twenty adult African catfish sourced from a commercial aquaculture in Eastern Nigeria were used for the study. They weighed an average of 900g and measured a standard body length of 45cm in length. The fish were euthanized with chloroform. The oropharyngeal cavity was cut open bilaterally at the junction between the mandible and maxilla. The body cavity was cut open through the mid ventral surface and the alimentary tract dissected out. The specimen under study - the oropharyngeal wall and oesophagus were excised and immediately fixed in 10% neutral buffered formalin.

The tissue was passed through graded ethanol, cleared in xylene, impregnated and embedded in paraffin wax. Sections 5 - 6µm thick were obtained with Leitz microtome model 1512. They were stained with haematoxylin and eosin for light microscopy examination (21). Mucins were demonstrated using Alcian blue (AB) at pH 2.5 (22, 23) and Periodic acid Schiff (PAS) with and without prior digestion with diastase (24, 25). In addition, the PAS technique was employed in combination with AB for neutral and acid mucin (21). Photomicrographs were taken with - Motican 2001 camera (Motican UK) attached to Olympus microscope.

RESULTS

Grossly, the oropharyngeal cavity was bounded dorsally by the palate and ventrally by the mandibular bone, cranially by upper and lower lips. The palate that formed the roof had three horny plates, one cranial plate and two caudal plates. The cranial plate was semilunar while the two caudal plates were separated by a thickened mucous membrane (Fig. 1). The horny plates on the mandible which formed the floor of the mouth were separated by thickened mucous membrane (Fig.2). The floor presented a tongue that was fixed (Fig.2). At caudal end of the dorsal wall of the oro-pharyngeal cavity were located two elevated round structures referred to as the pharyngeal pads. They were located about 2cm to the aditus oesophagus . The oesophagus was a short narrow tube connecting the oro-pharyngeal cavity to the stomach. On entering the coelomic cavity it coursed caudo-dorsally to the liver and entered

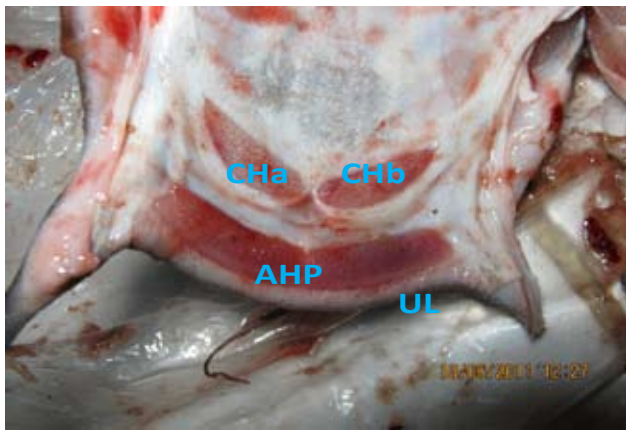


Fig.1. Gross appearance of the roof of the oropharyngeal cavity showing the cranial dorsal horny plate (AHP) conforming to the outline of the upper lip (UL), Immediately caudal to this are bilateral oval shaped horny plates (CHa, CHb).

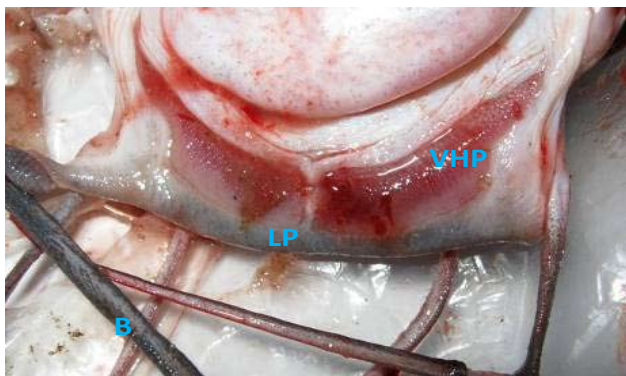


Fig.2. Gross appearance of the lower jaw showing the lip (LP), bilateral ventral horny plates (VHP) and the tongue (T). B-Barbel.

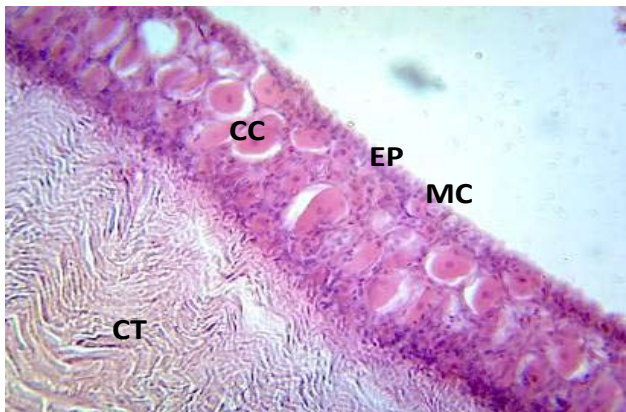


Fig.3. Section of the adult tongue showing stratified squamous epithelium (EP) containing large eosinophilic club cells (CC) and mucuous cells (MC). Note collagen fibres (CF) in the lamina propria. H.&E. X 400.

the stomach. There was no marked constriction separating the oesophagus from the stomach except the enlarged nature of the later.

HISTOLOGY

The tongue: the tunica mucosa presented stratified squamous epithelium containing eosinophilic club cells (Fig.3). No taste bud was observed in the epithelium. Dense collagen fibres were observed in the lamina propria-submucosa. The skeletal muscles of the tunica muscularis

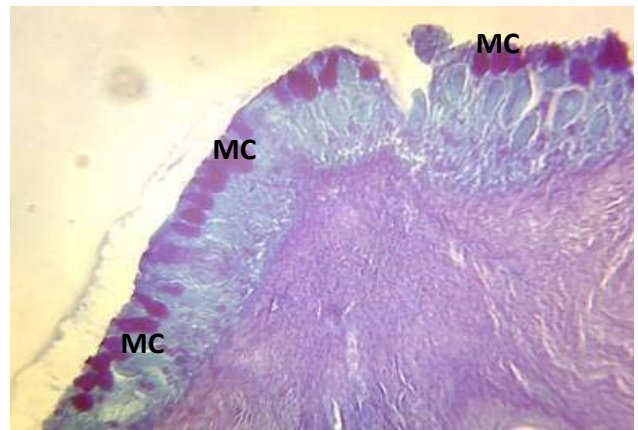


Fig. 4. Section of oro-pharyngeal wall showing PAS positive mucous cells (MC). PAS X400

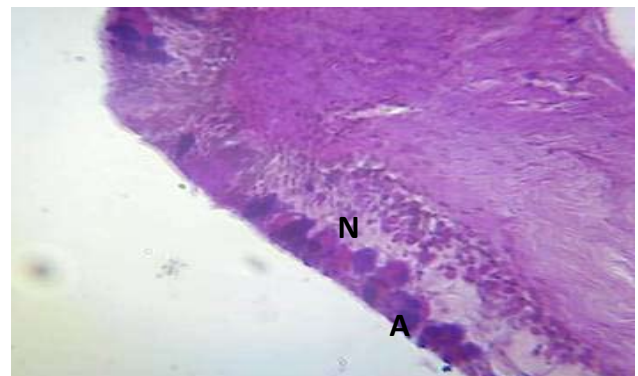


Fig.5. Section of adult oro-pharyngeal mucosa showing epithelial mucous cells that contain neutral (N) or acid (A) mucin). AB/PAS x400

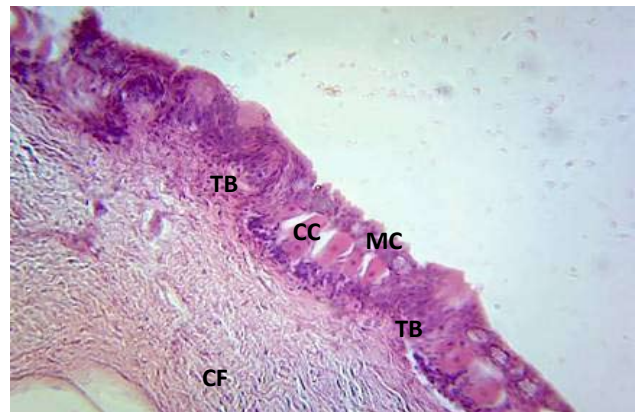


Fig.6. Section of adult oropharyngeal mucosa showing stratified mucous epithelium containing eosinophilic club cells, and occasional taste buds (TB). Note collagen fibres (CF) in the lamina propria. MC- mucous cells. H. & E. X 400.

were oriented mostly longitudinal direction. Hyaline cartilage was present at the base of the tongue.

Oropharyngeal wall: The mucosa was lined by stratified mucous epithelium containing large eosinophilic club cells, and occasional taste buds. The mucous cells were PAS positive (fig.4), AB positive, and presented cells that contained dominant neutral or acid mucin (fig.5). The lamina propria contained dense collagen fibres in irregular orientation (Fig.6).

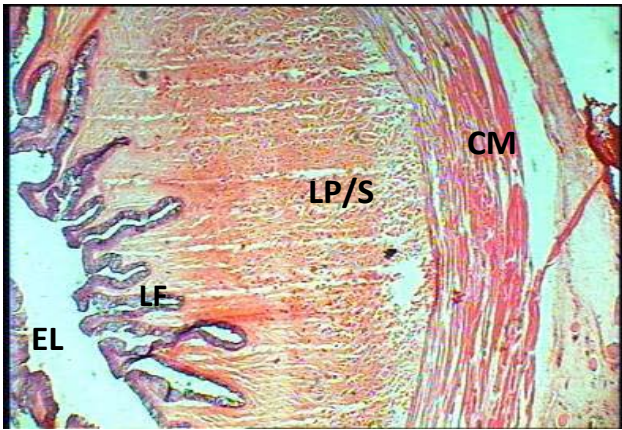


Fig. 7. Transverse section adult esophagus showing longitudinal fold (LF), which gave the lumen (EL) a narrow stellate appearance. Note the absence of muscularis mucosae. CM- circular skeletal muscle of tunica muscularis. H. & E. X40

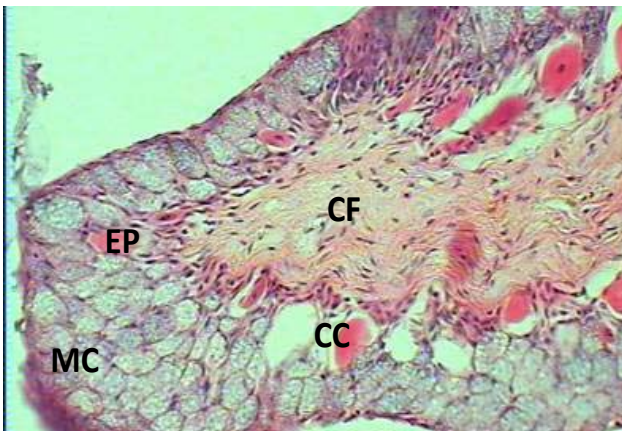


Fig.8. Section of adult oesophagus showing stratified mucous epithelium (EP) containing eosinophilic club cells (CC). Lamina propria contains collagen fibre (CF). Note MC- mucous cell. H. & E. X 400

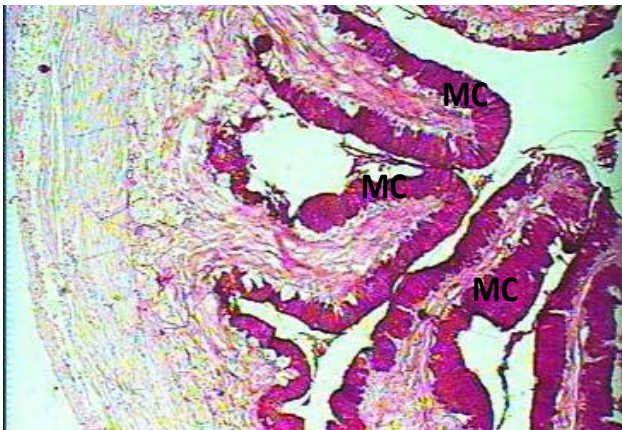


Fig.9. section of oesophagus showing PAS positive mucous cells (MC). PAS X100

Oesophagus: the longitudinal fold mucosa was lined by stratified mucous epithelium containing eosinophilic club cells (Fig.7, 8). The mucous cells were PAS positive (fig.9), AB positive (fig. 10), cell with varying quantities of neutral and acid mucins (fig. 11, 12). The core of longitudinal folds was of densely packed collagen fibres. The lamina propria-submucosa contained collagen fibres, and bundles of striated

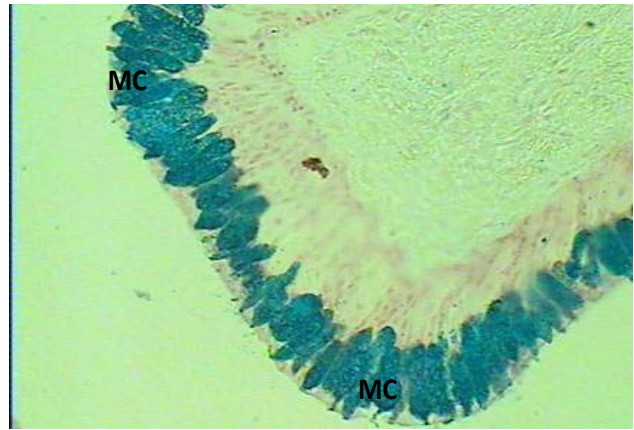


Fig.10. Section of oesohagus showing AB positive mucuous cells (MC). PAS X400

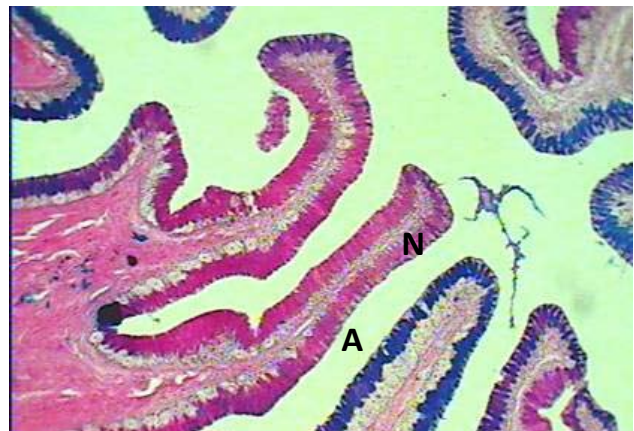


Fig.11. section of adult oesophagus showing longitudinal fold epithelial that contain neutral (N) or acid (A) mucin. AB/PAS X100

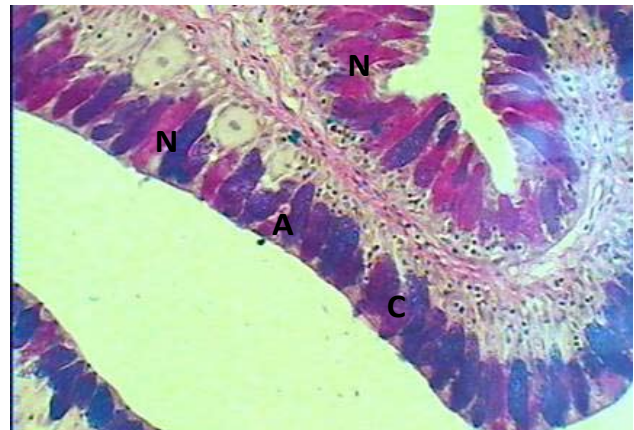


Fig.12. section of adult oesophagus showing longitudinal fold epithelia that contain neutral(N) or acid (A) mucin or combination of both (C). AB/PAS x400

muscle in mostly longitudinal orientation (Fig.13). The tunica muscularis was of striated muscles mostly in circular orientation interspersed with longitudinal muscle bundles. Tunica adventitia was entirely of loose connective tissue containing blood vessels.

DISCUSSION

The oropharyngeal cavity in conjunction

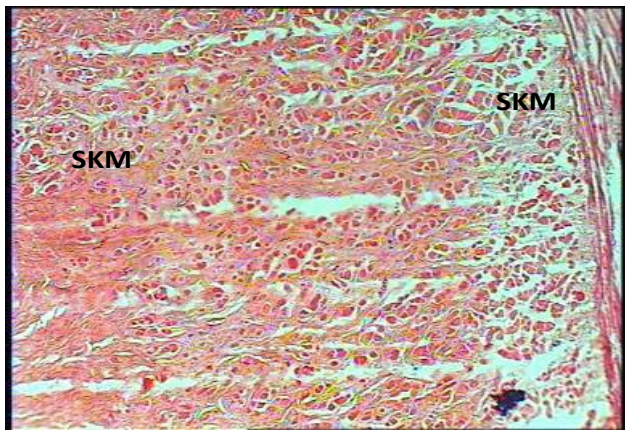


Fig. 13. transverse section of adult esophagus showing skeletal muscle bundles in the lamina propria-submucosa (SKM). H.& E. X100

with the branchial arches filter and keep the food for proper trituration by the pharyngeal pad in the adult. This has been documented also in *Odontesthes bonariensis* (26). The wall of the oropharyngeal cavity of the adult African catfish presented epithelium of stratified mucous type. This epithelium has a protective function (16, 19). The dense collagen bundle seen in the lamina propria-submucosa region maybe analogous to stratum compactum reported in some teleost, that support, strengthen and preserve the entirety of gut wall against sudden and violent extension (27,28). The skeletal muscles may be involved in voluntary trituration. The presence of taste buds in the oropharyngeal wall as observed in this study has also been reported in the *Odontesthes bonariensis* (26), and their presence suggest that the oropharyngeal wall may be involved in food selection or rejection by gustation (29,30). The mucous cells produce mucin which is involved in lubrication and defense against pathogens (19,31). The adult oropharyngeal wall showed the presence of acid and neutral mucin, but the acid predominated showing more bluish colour in combined AB-PAS procedure. This may be explained by the need for acid mucin to act as protective coat to invading agents in the cavity, the tongue presented similar reaction (26). The club cells present in teleost have been described as having a role in flight of fish from danger by secreting alarm substances (32). The hyaline cartilage is for support and provides point of attachment for the skeletal muscle seen (33).

The microanatomy of the tongue presented stratified mucous epithelia with club cells, collagen fibres and skeletal muscle. The tongue lacked taste buds. These features suggest an organ involved in mechanical function of voluntary feed trituration (34,35). The presence of rich vascularization suggest an active organ that needs nutrient and oxygen supply (36). The lack of taste buds as was observed in this study differs from the report on the presence of taste

buds on tongue of *Salmo gairdneri* by Ezeasor (29). This variation may be due to difference in species under study.

The oesophagus as documented by other researchers is a short narrow tube connecting the oropharyngeal cavity to the stomach (15,17,18,37). Grossly the esophagus in this study is located directly caudal to the pharynx, and extends from the most caudal gill arch to the cranial opening of the stomach. This observation has been reported by Hamlin (38) in the work on haddock, *Melanogrammus aeglefinus*. The longitudinal folds of the mucosa present in the oesophagus has been reported and provide the necessary distensibility during food intake (39, 40, 41). The lining epithelium of stratified mucous has been seen in *Micropogonias furnieri* but a stratified cuboidal to low columnar epithelia has been reported in *Salmo gairdneri*, Simple cuboidal epithelia has been reported in *Perca fluviatilis* L, Stratified columnar has been reported in yellow catfish *Pelteobagrus fulradraco* (15, 16, 17, 18). This variation may be phylogenetic or environmental. The presence of abundant mucous cells observed have also been reported and signifies the large requirement of mucin for lubrication during swallowing and increase in viscosity related to protection against abrasion and pathogens, as teleosts lack salivary gland (40, 42, 43). The oesophageal mucins seen were both acidic and neutral, but the acidic mucin was slightly higher indicating need for more protection against pathogenic agents, prevention of damage to gut epithelium, and acting as lubricant to fibre-rich materials being an omnivorous fish (19, 43, 46). The neutral mucins in the esophagus have been associated with pre-gastric digestion (47). The purple colouration seen in some longitudinal folds signifies the presence of both acid and neutral mucin in equal quantities (18, 26, 41). The esophagus of *Sparus aurata* presented only neutral mucins (48). In the *Sola sola* only acid mucopolysaccharides were seen in oesophageal mucous cells. In the *Salmo gairdneri* the anterior segment of the esophagus after AB/PAS procedure presented equal neutral and acid mucin, middle mostly purple while distal stained purple mostly (18). Raji and Norouzi (20) reported the presence of both neutral and acid mucin in the esophagus of both *Clarias batrachus* and *Serrasalmus natterieri*. Esophageal mucin has been suggested to play a role in regulating the pH of the stomach (15). The club cells are involved in non-specific defense mechanism (32). The presence of mostly circularly oriented striated muscle has been reported (20, 33), and is associated with ability to voluntarily reject unwanted material (44). The lymphocytes seen are involved in specific defense mechanism (16, 18). Absence of taste bud in the oesophageal epithelia as observed in this

study has been reported (15, 16, 19, 20, 26, 40), but taste buds presence have been reported in some teleosts oesophagus (18, 29). The varying shapes of mucous cells in the esophagus seen here have been reported in other teleosts (15, 18). The presence of only circular striated muscle as seen in adult has been reported (45). This circular muscle may help produce uniform muscle contraction, thereby producing a synctium-like effect. Adventitia with loose connective tissue and adipose tissue seen in this region has been reported in literature also (16).

In conclusion, the oropharynx is adapted for grasping large food materials for grinding by the cornified plates on the lips. The broad dorsoventrally compressed head with a wide mouth will engulf preys in the habitat since the tongue lacks taste buds. The acid mucin present will help in fight against bacteria while the club cells will protect against non specific agents by fight or flight. The large quantity of mucin in the oesophagus will help lubricate the tract since salivary gland is absent. It may also be an adaptation for varied feed in restricted concrete pond. The neutral mucin may be involved in pre-gastric digestion. From this study, the African catfish is adapting to intensive aquaculture through these cells and their functions. This study will fill the knowledge gap and help pathologist in fish disease diagnosis as the will serve as baseline data for this region.

REFERENCES

1. Podoskina TA. Morphology of supporting elements in jaw-pharyngeal apparatus of some pleuronectiform fishes in relation to feeding specializations. *Journal of Ichthyology*. 1993. 33: 122 - 127.
2. Platelli ME, Potter IC, Clarket KR. Do the habitats , mouth morphology and diets of the mullids *Upeneichthys stotti* and *U.lineatus* in coastal waters of south western Australia differ? *Journal of Fish Biology* 1998. 52: 398-418.
3. Salvador-Jr LF, Salvador GN, Santos GB. Morphology of the digestive tract and feeding habits of *Loricaria lentiginosa* Isbrucker, 1979, in a Brazilian Reservior : A review .*Acta zoologia*. 2009. 90: 101-109
4. Sysa P, Ostaszeroska T, Olejniczak M. Development of digestive system and swim bladder of larval nase (*Chondrostoma nasus L*). *Aquaculture Nutrition* 2006. 12: 33 - 339.
5. Delariva RL, Agostinho AA. Relationship between morphology and diets of six Neotropical loricariids. *Journal of Fish Biology*. *Fish Biol*. 2001, 58, 832 - 847.
6. Girgis S. The bucco-pharyeal feeding mechanism in an herbivorous bottom-feeding cyprinoid fish, *Laboe horie* (Cuvier). *Journal of Morphology*. 1952, 90: 281 - 316.
7. Girgis S. On the anatomy and histology of the alimentary tract of an herbivorous bottom - feeding cyprioid fish, *Laboe horie* (Curier). *Journal of Morphology* 1952. 90: 317 - 362.
8. Mester L. Studial cavitatic buco-faringiene la *Noemacheilus barbatulus*. (Pisces, Cobitidae). *Studii si cercetazy de biologie, seria zoologia*. Buca 1971, 23: 439 - 444.
9. Suzuki Y. A histological study of the granular processes on the lips of scythe fish *Pseudogobio esocinus*. *Japan Journal of Ichthyology* 1956, 5: 12 - 14.
10. Branson BA, Hake P. Observations on an accessory breathing mechanism in *Piaractus nigripinnis* (Cope). *Zoology. Anz. Leipzig*. 1972, 189: 292 - 297.
11. Al-Hussaini AH. The feeding habits and the morphology of the alimentary tract of some teleosts living in the neighbourhood of the Marine Biological Station, Ghardaqa, red Sea. *Publications of the Marine Biological Station Ghardaqa (Red Sea)* 1947, 5:1 - 61.
12. Saxena DB. Oral Breathing values in some freshwater fishes of India. *Science culture* 1958, 25: 318 - 319.
13. Kapoor BG. Oral valves of teleosts. *Japan Journal of Ichthyology* 1957, 5: 127 - 131.
14. Sinha GM. Functional histology of the different regions of the esophagus of a freshwater major carp *Labeo calbasu* (Hamilton) during the different life history stages. *Zoologia Beit* 1977, 23:353 - 360.
15. Hirji KN. Observations on the histology and histochemistry of the oesophagus of the perch, *Perca fluviatilis L*. *Journal of Fish Biology* 1983, 22: 145 - 152.
16. Diaz AO, Garcia AM, Figueroa DE, Goldemberg AL. The Mucosa of the Digestive Tract in *Micropogonias furnieri*: A light and Electron microscope Approach. *Anatomia Histologia Embryologia* 2008, 37, 251 - 256.
17. Cao JX, Wang WM. Histology and Mucin Histochemistry of the Digestive tract of Yellow Catfish *Pelteobagrus Fulvidraco*. *Anatomia Histologia Embryologia* 2009, 38: 254 - 261
18. Ezeasor DN. Light and Electron Microscopic studies on the Oesophageal Epithelium of the Rainbow Trout, *Salmo gairdneri*. *Anatomia*. 1984, Anz Jena, 155: 71 - 83.
19. Albrecht MP, Ferreisa MFN, Caramasch EP. Anatomical features and histology of the digestive tract of two related neotropical omnivorous fishes (Characiformes; Anostomidae). *Journal of Fish Biology* 2001, 58: 419 - 430.
20. Raji AR, Norouzi E. Histological and histochemical study on the alimentary canal in walking catfish (*Clarias batrachus*) and piranha (*Serrasalmus natterci*). *Iran Journal Veterinary Research Shiraz University* 2010, 11:255 - 261.
21. Bancroft JD, Stevens A. Theory and practice of histological techniques. Churchill Livingstone, New York, USA.Pp 148-155. 1977.
22. Steedman HF. Alcian blue 8G: a new stain for mucin. *Journal of Microscopic Science* 1950, 91: 477 - 479.

23. Lev R, Spicer SS. Specific staining of sulphated groups with alcian blue at low pH. *J. Histochemistry Cytochemistry* 1964, 12: 309 - 310.
24. Lillie RD, Greco J. Mact diastase ptyalin in place of saliva in the identification of glycogen. *Staining Technique* 1947, 22: 67 - 70.
25. Ikpegbu E, Nlebedum UC, Nnadozie O, Agbakwuru I. Fast Green FCF or Ehrlich's hematoxylin as counterstain to periodic acid Schiff reaction: A comparative study. *Histologic* 2011, 54: 29-30.
26. Diaz AO, Escalante AH, Garcia AM, Goldemberg AL. Histology and Histochemistry of the pharyngeal cavity and Oesophagus of the silverside *Odontesthes bonariensis* (Cuvier and Valenciennes). *Anatomia Histologia Embryologia* 2006, 35: 42 - 46.
27. Burnstock G. The morphology of the gut of the brown trout (*Salmo trutta*). *Quarterly Journal of Microscopic Science* 1959, 100: 183 - 198.
28. Ezeasor DN. The structure and functional significance of stratum compactum in the Gut of Rainbow Trout *Salmo gairdneri* (Rich). *Ziet Mikro. Anatomia. Forsch. Leipzig* 1986, 100:536 - 544.
29. Ezeasor DN. Distribution and ultrastructure of taste buds in the oropharyngeal cavity of the rainbow trout, *Salmo gairdneri* Richardson. *Journal of Fish Biology* 1982, 20: 53 - 68.
30. Linser PJ, Carr WES, Cate HS, Derby CD, Nether-ton III JC. Functional significance of the Co-localization of Taste Buds and Tech in the pharyngeal Janes of the largemouth Boss, *Microptenes Salmoides*. *Biology Bulletin* 1998, 195: 273 - 281.
31. Micale Mughia U. Comparative ontogeny of the digestive tract in Sharpsnout sea Bream *Diplodus puntazzo* C. and common Pandora Pagellus enthrinus L. *Open Marine Biology* 2011, Journal 5: 31 - 34.
32. Singh CP, Kapoor BG. Histological observations on the barbels of a Bagrid Catfish, *Rita rita* (HAM). *Japan Journal Ichthyology* 1967, 14: 197-203.
33. Falk-Petersen IB, Hansen TK. Organ differentiation in newly hatched common coalfish. *Journal Fish Biology* 2001, 59: 1465 - 1482.
34. Bishop C, Odense PH. Morphology of the digestive tract of the cod, *Gadus morhua*. *Journal of fisheries research Board of Canada* 1966, 23: 1607 - 1615.
35. Maggese MCI. Consideraciones anátomo-histológicas sobre el tracto digestivo del "papamoscas" *Cheilodactylus bengi* (Teleostomi, cheilodactylidae). *Physiology. Buenos Aires*, 1967, 27: 111 - 124.
36. Singh J. *Textbook of Human Histology*. Jaypee Brothers, India. Pp 174-183. 2006.
37. Sinha GM. Functional histology of the different regions of the esophagus of a freshwater major carp *Labeo calbasu* (Hamilton) during the different life history stages. *Zool. Beitr.* 1977, 23, 353 - 360.
38. Hamlin HJ, Hunt von Herbing I, Kling LJ. Histological and morphological evolution of the digestive tract and associated organs of haddock throughout post - hatching ontogeny. *Journal of Fish Biology* 2000, 57: 716 - 732.
39. Ezeasor DN, Stokoe WM. The light and electron microscopic studies on the absorptive cells of the intestine, Caeca and rectum of the adult rainbow trout, *Salmo gairdneri* (Rich). *Journal of Fish Biology*, 1981, 18: 527 - 544.
40. Arellano JM, Storch V, Sarasquete C. A histological and histochemical study of the oesophagus and oesogaster of the Senegal sole, *solea senegalensis*. *European Journal of Histochemistry* 2001, 45: 279 - 294.
41. Trevino L, Alvarez-Gonzalez CA, Perales-Garcia N, Avevalo-Galan L, Uscanga-Martinez A, Morquez-Couturier G, Fernandez I, Gisbert E. A histological study of the organogenesis of the digestive system in baysnook (*Peternia splendid* Gunther, 1862) from hatching to the juvenile stage. *Journal of Applied Ichthyology* 2011, 27: 73 - 82.
42. Scocco P, Accili D, Menghi G, Ceccarelli P. Unusual glycoconjugates in the oesophagus of a tilapine polyhybrid. *Journal of Fish Biology*. 1998, 53: 39 - 48.
43. Kozaric Z, Kuzir S, Petrinc Z, Gjurevic E, Bozic M. The Development of the Digestive Tract in Larval European Catfish (*Silures glanis L.*). *Anatomia Histologia. Embryologia* 2008, 37: 141 - 146.
44. Jaroszewska M, Dabrowski K, Wilczynska B, Kakareko T. Structure of the gut of the racerby *Neogobius gymnotrachelus* (Kessler, 1857). *Journal of Fish Biology* 2008, 72: 1773 - 1786.
45. Yang R, Xie C, Fan Q, Gao C, Fang L. Ontogeny of the digestive tract in yellow catfish *Pelteobagrus fulvidraco* larvae. *Aquaculture* 2010, 302: 112 - 123.
46. Pedini V, Scocco P, Radaelhi G, Fagioli O, Ceccarelli P. Carbohydrate histochemistry of the alimentary canal of the Shi. Drun, *Umbrina Cirrosa* . *Anatomia. Histologia. Embryologia* 2001, 30, 345 - 349.
47. Baglolle CJ, Murray HM, Goff GP, Wright GM. Ontogeny of the digestive tract during larval development of yellowtail flounder: a light microscopic and mucous histochemical study. *Journal of Fish Biology* 1997, 51: 120 - 134.
48. Sarasquete MC, Polo A, Yufera M. Histology and histochemistry of the development of the digestive system of larval gilthead seabream, *Sparus aurata L.* *Aquaculture* 1995, 130: 79 - 92.