



LETTER TO THE EDITOR

Metastatic small bowel occlusion as initial presentation of squamous cell carcinoma of the lung

Rita Seara Costa¹ , Ana Luísa Vieira², Juliana M. Costa¹ , Beatriz Fernandes², Aníbal Ferreira¹

¹Department of Gastroenterology, Braga Hospital, Braga, Portugal

²Department of Pneumology, Braga Hospital, Braga, Portugal

Cite this article as: Costa RS, Vieira AL, Costa J, Fernandes B, Ferreira A. Metastatic small bowel occlusion as initial presentation of squamous cell carcinoma of the lung. *Turk J Gastroenterol* 2018; DOI: 10.5152/tjg.2018.18419.

Dear Editor,

We report the case of a 68-year-old man who presented at the emergency department with abdominal pain, vomiting, and constipation that progressively became worse over a 1-month period. His social history was notable for a remote phase of smoking. On physical examination, the patient was found to be hemodynamically stable, and his abdomen was tender with diffuse periumbilical pain on palpation. His laboratory results showed hemoglobin of 12.4 g/dL (normal, >13 g/dL), white blood count of 13000/uL (normal, 4000–11000/uL), and C-reactive protein level of 96.4 mg/L (normal, <2.9 mg/L). Abdominal computerized tomography (CT) scan revealed focal thickening of the ileal segment (Figure 1a). Additional thoracic CT revealed a left upper lobe mass (50×55 mm) (Figure 1b). The patient underwent bronchofibroscope and an exploratory laparoscopy with enterectomy. The cytology of the bronchial aspirate and histology of the ileal enterectomy were consistent with squamous cell carcinoma of the lung with intestinal metastasis, respectively (Figure 2a, 2b, respectively). The neoplasia was completely staged as squamous cell carcinoma of the lung, stage IV cT2b-N2M1b (mediastinal and left hilar lymph nodes and liver metastases) according to the 7th edition of TNM classification (1). The patient was treated with palliative chemotherapy with carboplatin and gemcitabine (6 cycles) and died 6 months after the diagnosis.

Lung cancer is one of the most common cancers worldwide and is the leading cause of cancer-related deaths with a 5-year survival of 10%–25% (2). In non-small-cell lung cancers (NSCLC), approximately 40% of the patients have metastatic disease at the time of presen-

tation (1). NSCLC can metastasize to nearly any organ, but it usually spreads to the brain, liver, adrenal glands, bone, and lung. Clinically significant small bowel metastases are rare (frequency of 0.5%) (2), and its diagnosis is usually based on post-mortem examination [12% of prevalence of gastrointestinal (GI) metastases and 8.1% in small bowel] (3). Small bowel, especially ileum, is the most commonly reported site for GI-tract metastasis of lung cancer. Small bowel metastases may occur in every cell type of primary lung cancer. The pathogenesis of small bowel metastases has been thought to be due to tumor cell spread via the hematogenous and lymphatic routes. Tumor invasion of the bowel wall results in perforation, obstruction, and bleeding. It appears that perforation or hemorrhage can also occur in patients under chemotherapy because chemotherapy may lead to tumor necrosis and acute ulceration (4). The difficulty in early detection of GI metastases leads to a delay in diagnosis until presenting with life-threatening complications that frequently require emergency surgeries (4). The time between the diagnosis of squamous cell carcinoma of the lung and the discovery of GI metastases is extremely variable, occurring more often in the first 12 months (2,4).

In this case report, small bowel obstruction was the initial clinical symptom for this patient that led to the diagnosis of lung cancer stage IV. Only a few cases of metastatic lesion as the initial manifestation of lung cancer are described in literature (2,5), and none are with squamous cell carcinoma of the lung. The outcome of patients with GI metastases is very poor, and most of the patients succumb to their disease within 6 months after the diagnosis, as was the case with our patient (2,4,5).

Corresponding Author: Rita Seara Costa; rita.seara.costa@gmail.com

Received: May 24, 2018 Accepted: July 28, 2018 Available online date: November 20, 2018

© Copyright 2018 by The Turkish Society of Gastroenterology · Available online at www.turkjgastroenterol.org

DOI: 10.5152/tjg.2018.18419

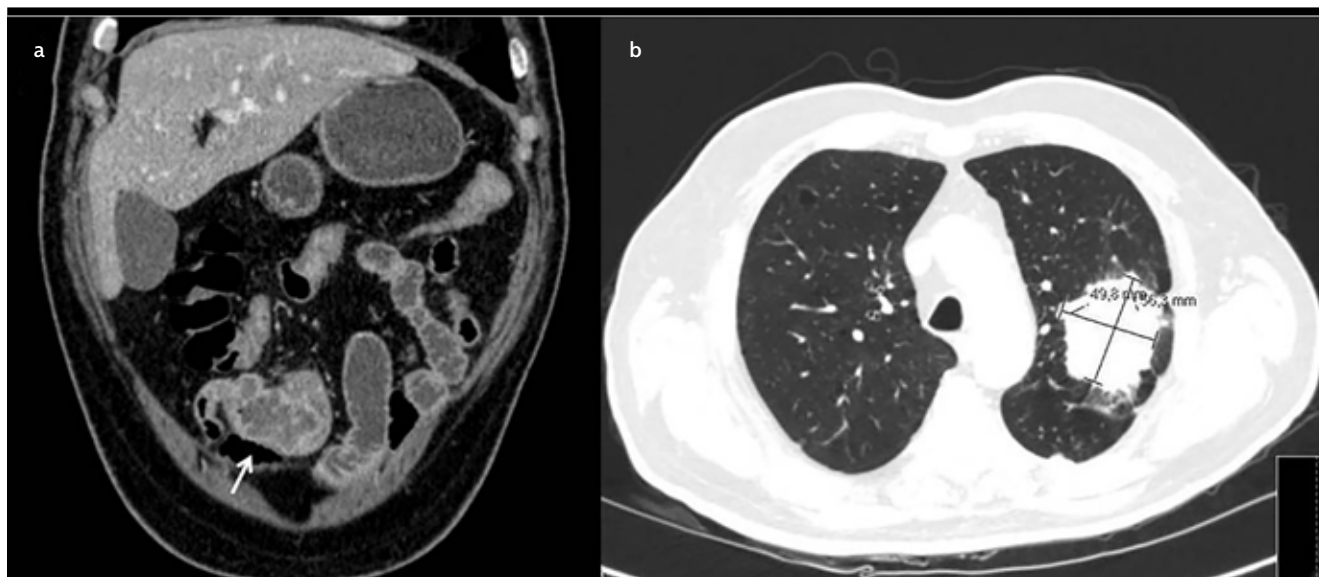


Figure 1. a, b. Abdominal computerized tomography (CT) scan revealed focal thickening of the ileal segment (a); additional thoracic CT revealed a left upper lobe mass (50×55 mm) (b)

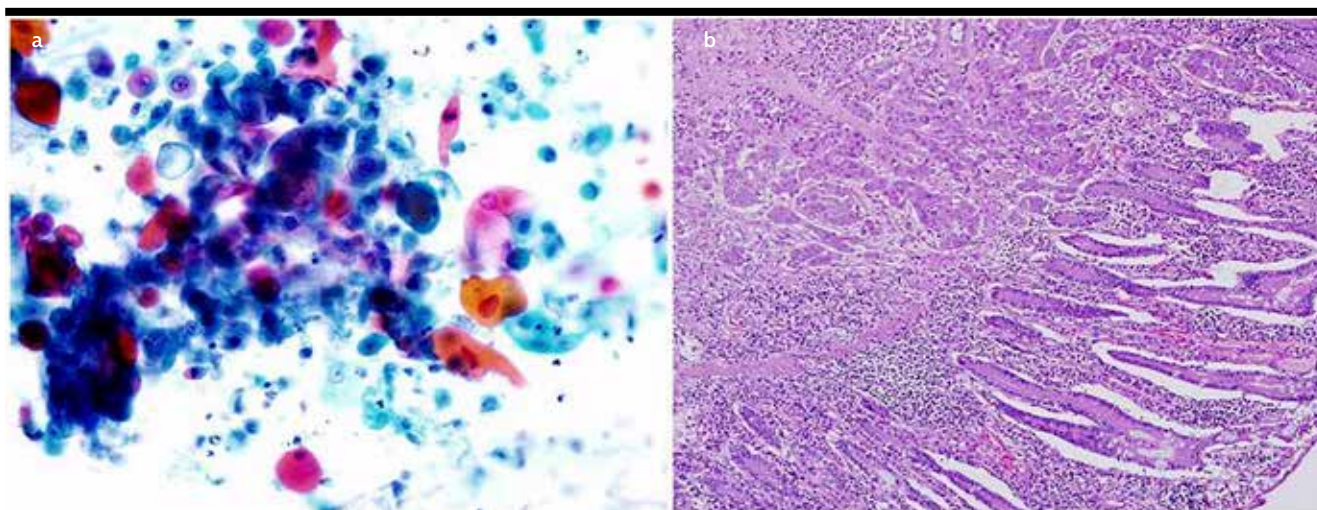


Figure 2. a, b. The cytology of the bronchial aspirate and histology of the ileal enterectomy were consistent with squamous cell carcinoma of the lung with intestinal metastasis, respectively (a, b)

Informed consent is not obtained because patient died before we attempted to publish this case report. Besides that, it is not possible to identify the patient through figures or clinical information.

Informed Consent: N/A.

Peer-review: Externally peer-reviewed.

Author Contributions: Concept - R.S.C., A.L.V., J.M.C.; Design - R.S.C., A.F.; Supervision - A.F., B.F.; Data Collection

and/or Processing - J.M.C., R.S.C.; Analysis and/or Interpretation - A.L.V., B.F.; Literature Search - R.S.C., A.L.V.; Writing Manuscript - R.S.C., J.M.C.; Critical Reviews - A.L.V., B.F., A.F.

Conflict of Interest: The authors have no conflict of interest to declare.

Financial Disclosure: The authors declared that this study has received no financial support.

REFERENCES

1. Goldstraw P, Crowley J, Chansky K, et al. The IASLC Lung Cancer Staging Project: proposals for the revision of the TNM stage groupings in the forthcoming (seventh) edition of the TNM Classification of malignant tumours. *J Thorac Oncol* 2007; 2: 706-14. [\[CrossRef\]](#)
2. Berger A, Cellier C, Daniel C, et al. Small bowel metastases from primary carcinoma of the lung: clinical findings and outcome. *Am J Gastroenterol* 1999; 94: 1884-7. [\[CrossRef\]](#)
3. McNeill PM, Lawrence D, Wagman MD. Small bowel metastases from primary carcinoma of the lung. *Cancer* 1987; 59: 1486-9. [\[CrossRef\]](#)
4. Yang C, Hwang J, Kang W, et al. Gastro-intestinal metastasis of primary lung carcinoma: Clinical presentations and outcome. *Lung Cancer* 2006; 54, 319-23. [\[CrossRef\]](#)
5. Taira N, Kawabata T, Gabe A, et al. Analysis of gastrointestinal metastasis of primary lung cancer: clinical characteristics and prognosis. *Oncol Lett* 2017; 14: 2399-404. [\[CrossRef\]](#)