


Contents lists available at [ScienceDirect](http://ScienceDirect.com)

Journal of the Neurological Sciences

journal homepage: www.elsevier.com/locate/jns

Clinical Short Communication

Role of the “other Babinski sign” in hyperkinetic facial disorders[☆]Sara Varanda^{*}, Sofia Rocha, Margarida Rodrigues, Álvaro Machado, Gisela Carneiro

Neurology Department, Hospital de Braga, Sete Fontes, São Víctor, 4710-243 Braga, Portugal

ARTICLE INFO

Article history:

Received 27 November 2016

Received in revised form 12 April 2017

Accepted 21 April 2017

Available online 22 April 2017

Keywords:

Blepharospasm

Botulinum toxin

Post-paralytic facial syndrome

Hemifacial spasm

ABSTRACT

Background: The “other Babinski sign” consists in the co-contraction of the orbicularis and frontalis muscles, causing an eyebrow elevation during ipsilateral eye closure. It cannot be voluntarily reproduced.

Aims of the study: To determine the utility of this sign in the differential diagnosis of hyperkinetic facial disorders.

Methods: The presence of the sign was assessed in consecutive patients with blepharospasm, primary hemifacial spasm or post-paralytic facial syndrome treated in a botulinum toxin outpatient clinic.

Results: Of the 99 patients identified, 86 were included, 41 with blepharospasm (32 female, mean age 71 ± 11 years), 28 with hemifacial spasm (16 female, mean age 65 ± 12 years) and 17 with post-paralytic facial syndrome (14 female, mean age 50 ± 17 years). The sign was detected in 67.9% of the patients with hemifacial spasm, in 23.5% of the post-paralytic facial syndrome group and in none of the patients with blepharospasm, exhibiting a sensitivity of 51% and a specificity of 100% for the diagnosis of hemifacial spasm/post-paralytic facial syndrome and a specificity of 76% for hemifacial spasm, compared to post-paralytic facial syndrome.

Conclusions: This sign is highly specific for the diagnosis of peripherally induced hyperkinetic facial disorders. Its assessment should integrate the routine examination of patients with abnormal facial movements.

© 2017 Elsevier B.V. All rights reserved.

1. Background

The “other Babinski sign” consists in the co-contraction of the orbicularis oculi and the internal part of frontalis muscles, leading to eyebrow lifting during ipsilateral eye closure. Joseph Babinski noticed this could not be voluntarily reproduced, thence its utility in distinguishing organic facial disorders from functional conditions [1,2]. Blepharospasm, hemifacial spasm and reinnervation synkinesis are occasionally difficult to distinguish. Blepharospasm is a focal facial dystonia, of suspected multifactorial origin, consisting in involuntary, spasmodic and synchronous contractions of orbicularis oculi muscles in a spectrum from increased blinking to orbicular contraction interfering with vision [3,4]. Hemifacial spasm consists in peripherally induced, involuntary, irregular, clonic and/or tonic contractions of muscles innervated by the ipsilateral facial nerve. Approximately 90% of the cases start in the periorbital musculature, spreading later to adjacent muscles [5]. The most common aetiology is a compression of the facial nerve by a vessel at its root exit zone. Post-paralytic facial syndrome results from aberrant regeneration of the facial nerve after a paralysis, in a process including axonal reinnervation errors and enhanced neuronal excitability [6]. It comprises involuntary contraction of hemifacial muscles, unintended contractions triggered by voluntary movements (synkinesis)

and myokymia [6]. More than 70% of the patients show simultaneous involvement of upper and lower facial muscles from the outset [7].

Given the possible semiologic overlap of these disorders, we aimed to prospectively determine the utility of the “other Babinski sign” in their differential diagnosis.

2. Methods

The study was approved by the local ethics committee, written informed consent was obtained from all participants and the principles outlined in the Declaration of Helsinki were followed. The presence of the sign was assessed in consecutive patients attending a botulinum toxin outpatient clinic, diagnosed with blepharospasm, hemifacial spasm or post-paralytic facial syndrome. Patients were evaluated three to four months after the last treatment, in order to minimise confounding effects. Patients with other involuntary movements were excluded. In unclear cases, presence of the sign was evaluated by two additional neurologists. Statistical analysis was performed using SPSS, version 20 (IBM). Distribution normality was assessed through the Kolmogorov-Smirnov test. Fisher's test and chi-square were used to determine group differences, with an alpha set at 0.05 as the statistical threshold for significance.

3. Results

Ninety-nine patients identified: 13 excluded, 10 because of concurrent movement disorders and three due to non-consensual assessment

[☆] This research did not receive any specific grant from funding agencies in the public, commercial, or not-for-profit sectors.

^{*} Corresponding author.

E-mail address: sara.varanda@hospitaldebraga.pt (S. Varanda).

for the presence of the sign; 86 patients included, 41 with blepharospasm (32 female, mean age 71 ± 11 years, range 48–96), 28 with hemifacial spasm (16 female, mean age 65 ± 12 years, range 44–83, 61% left-sided, 39% right-sided) and 17 with post-paralytic facial syndrome (14 female, mean age 50 ± 17 years, range 18–81, 65% left-sided, 35% right-sided). All patients with hemifacial spasm had a MR angiography. Neurovascular contact was detected in 13 (60.7%). The “other Babinski sign” was present in 19 patients with hemifacial spasm (67.9%), in four with post-paralytic facial syndrome (23.5%) and in none of the blepharospasm group (Fig. 1). Analysing both the patients with primary hemifacial spasm and post-paralytic facial syndrome and taking the blepharospasm group as control, the sign exhibited a sensitivity of 51% and a specificity of 100% for the diagnosis of hemifacial spasm/post-paralytic facial syndrome. It was less frequent in patients with past facial paralysis ($p < 0.001$). Accordingly, its specificity for the diagnosis of hemifacial spasm was 76%, compared to post-paralytic facial syndrome (32%). There was no difference concerning detection of a vascular loop between patients with and without the sign ($p = 0.173$).

4. Discussion

The “other Babinski sign” was frequent in primary hemifacial spasm, less common in post-paralytic facial syndrome and absent in blepharospasm, which confirms the results of previous studies [8–10]. The prevalence in hemifacial spasm found in our study was intermediate to others published. Stamey and Jankovic detected the sign in 25.3% of 75 hemifacial spasm patients [8] and Pawlowski and colleagues determined a prevalence of 86% in 35 patients [9]. The first authors relied on video records to assess the presence of the sign, while the latter used direct observation. Although the search for the sign in a brief video session probably renders an underestimation of its true prevalence [8], a recent study, using the same methodology, determined a higher prevalence [10]. Some patients may reveal more subtle signs (as those excluded because of non-consensual clinical evaluation). Maybe a categorization of the patients in present, absent and possible sign, would allow more comparable results. Our statistical measures of the sign's performance did not differ significantly from the ones previously reported [8,9]. To our knowledge, this is the first study pointing to a negative correlation between the “other Babinski sign” and past facial paralysis. Therefore, though present in almost a quarter of the patients with post-paralytic facial syndrome, this sign seems more specific for the diagnosis of primary hemifacial spasm. It has been suggested that the existence of different patterns of suprasegmental innervation for the orbicularis oculi and frontalis muscles could explain the

absence of this sign in blepharospasm [8]. Thus, the emergence of the “other Babinski sign” in primary hemifacial spasm and in post-paralytic facial syndrome, probably reflects the peripheral origin of these disorders.

5. Limitations

The evaluation was non-blinded, but the inherent characteristics of the syndromes largely preclude a blinded design. Patients undergoing botulinum toxin treatment may be not fully representative of the general population with these abnormal movements. We assessed the sign months after the last treatment, to ensure that it would not mask the presence of the sign, although this cannot be fully warranted. The fact that all patients were treated after the evaluation argues in favour of minor impact of the last treatment. The post-paralytic facial syndrome group may have been under-represented. We joined these patients with the hemifacial spasm group to guarantee a reliable statistical analysis. Interrater reliability could be an interesting point to address, but it was already demonstrated in another study [9].

6. Conclusions

The assessment of the “other Babinski sign” is a useful tool that should integrate the clinical approach of patients with hyperkinetic facial disorders.

Conflicts of interest

None.

Acknowledgements

We would like to thank Dr. Ana Sofia Costa, neuropsychologist at the Neurocognition Unit of the Neurology Department of Hospital de Braga and Dr. Joana Barrocas, general practitioner at USF Maresia – ULS Matosinhos and Public Health PhD at Instituto de Saúde Pública of University of Porto, for their help with the statistical analysis.

References

- [1] J.L. Devoize, The other Babinski's sign: paradoxical raising of the eyebrow in hemifacial spasm, *J. Neurol. Neurosurg. Psychiatry* 70 (4) (2001) 516.
- [2] J.L. Devoize, Neurological picture. Hemifacial spasm in antique sculpture: interest in the 'other Babinski sign', *J. Neurol. Neurosurg. Psychiatry* 82 (1) (2011) 26, <http://dx.doi.org/10.1136/jnnp.2010.208363>.
- [3] F. Grandas, J. Elston, N. Quinn, C.D. Marsden, Blepharospasm: a review of 264 patients, *J. Neurol. Neurosurg. Psychiatry* 51 (6) (1988) 767–772.
- [4] J. Valls-Sole, G. Defazio, Blepharospasm: update on epidemiology, clinical aspects, and pathophysiology, *Front. Neurol.* 7 (2016) 45, <http://dx.doi.org/10.3389/fneur.2016.00045>.
- [5] N. Chaudhry, A. Srivastava, L. Joshi, Hemifacial spasm: the past, present and future, *J. Neurol. Sci.* 356 (1–2) (2015) 27–31, <http://dx.doi.org/10.1016/j.jns.2015.06.032>.
- [6] J. Valls-Sole, Facial nerve palsy and hemifacial spasm, *Handb. Clin. Neurol.* 115 (2013) 367–380, <http://dx.doi.org/10.1016/B978-0-444-52902-2.00020-5>.
- [7] C. Colosimo, M. Bologna, S. Lamberti, et al., A comparative study of primary and secondary hemifacial spasm, *Arch. Neurol.* 63 (3) (2006) 441–444, <http://dx.doi.org/10.1001/archneur.63.3.441>.
- [8] W. Stamey, J. Jankovic, The other Babinski sign in hemifacial spasm, *Neurology* 69 (4) (2007) 402–404, <http://dx.doi.org/10.1212/01.wnl.0000266389.52843.3b>.
- [9] M. Pawlowski, B. Gess, S. Evers, The Babinski-2 sign in hemifacial spasm, *Mov. Disord.* 28 (9) (2013) 1298–1300, <http://dx.doi.org/10.1002/mds.25472>.
- [10] J. Baizabal-Carvalho, J. Jankovic, Distinguishing features of psychogenic (functional) versus organic hemifacial spasm, *J. Neurol.* 264 (2) (2017) 359–363, <http://dx.doi.org/10.1007/s00415-016-8356-0>.

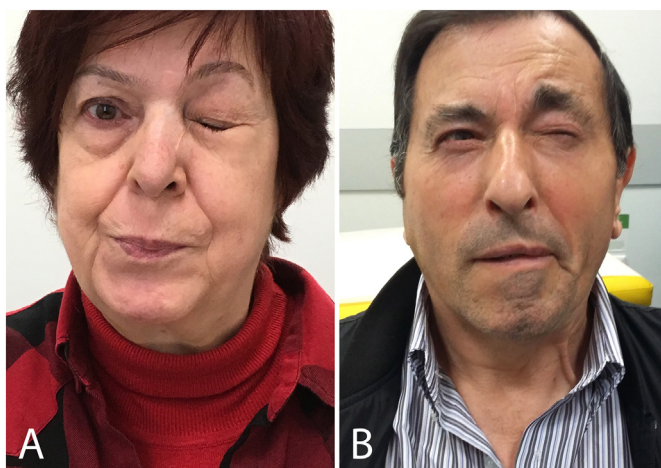

Fig. 1. Typical patients with left-sided hemifacial spasm. The “other Babinski sign” is evident as an elevation of the eyebrow caused by contraction of the frontalis muscle during voluntary eye closure ipsilateral to the facial spasm.