

CASE REPORT

Leg ulcer as a manifestation of eosinophilic vasculitis in a patient with hepatitis C virus infection, medicated with pegylated interferon/ribavirin

Cristina Resende, Teresa Pereira, Filipa Ventura, Celeste Brito

Department of Dermatology and Venereology, Hospital de Braga, Braga, Portugal

Correspondence to
Dr Cristina Resende,
cristinapresende@gmail.com

Accepted 21 May 2015

SUMMARY

Cryoglobulinaemic vasculitis is a complication of hepatitis C virus (HCV) infection, responding to treatment with pegylated interferon (peg-IFN)/ribavirin (RIB), but vasculitis may first appear after treatment with peg-IFN/RIB. A 35-year-old man with HCV infection presented to our department with a 2-month history of a 3.3×3 cm ulcer localised on the right shin, with a regular border, on a violaceous base. Histopathological examination revealed a leucocytoclastic vasculitis, rich in eosinophils. The patient had been treated with peg-IFN/RIB 10 months prior and treatment was discontinued after 2 months because of the appearance of arthralgias and neuropathy. Laboratory investigations revealed positive cryoglobulins, elevation of rheumatoid factor and reduction of C4 after treatment with peg-IFN/RIB. Dressings with a hydrocellular foam were placed and after 2 months the ulcer resolved. We presented this case because of the rarity of development of a cryoglobulinaemic vasculitis in a patient with HCV infection, previously treated with peg-IFN/RIB.

genotype 4 HCV infection of unknown aetiology 20 years prior, and had not been followed up in hepatology consultation until 1 year previously. He had been treated with a combination therapy with peg-IFN 2a (180 µg/week) and RIB (1200 mg/day) 1 year earlier, but the treatment was discontinued after 2 months because of the sudden appearance of intense, peripheral arthralgias and peripheral neuropathy, confirmed by electromyography. The HCV viraemia changed from 700 000 to 540 UI/mL at the end of treatment and the transaminases normalised.

For maintaining the symptomatology, the patient was medicated with pregabalin 75 mg/day, with partial improvement of pain. He was referred to our department for a 3.3×3 cm ulcer localised on his right shin; it had a regular and elevated border on a violaceous base, and granulation tissue was seen in approximately 60% of the ulcer bed ([figure 1](#)).

INVESTIGATIONS

Laboratory investigations revealed positive cryoglobulins and the persistence of HCV viraemia (141 446 UI/mL). The rheumatoid factor was markedly elevated (2600, normal <15) and C4 fraction of complement was reduced (<5, normal 10–40) after treatment with peg-IFN/RIB. The rest of the biochemistry panel and haematological counts were within normal limits, including hepatic transaminases. Histopathological examination of the border of the ulcer revealed a leucocytoclastic vasculitis, rich in eosinophils; it did not reveal granulomas ([figures 2 and 3](#)).

BACKGROUND

Chronic hepatitis C virus (HCV) infection is one of the most important causes of liver disease in the world.¹ Pegylated interferon (peg-IFN) plus ribavirin (RIB), given for 24 or 48 weeks is a possible treatment used in chronic HCV infection,¹ achieving a higher sustained virological response rate.² However, side effects are common and sometimes severe, leading to discontinuation of treatment.¹ Compared with IFN alone, the peg-IFN/RIB combination treatment is associated with a higher incidence of cutaneous side effects.^{3–5}

Cryoglobulinaemic and non-cryoglobulinaemic vasculitis are complications of HCV infection, and mostly respond to antiviral treatment with peg-IFN/RIB.^{1–3} However, vasculitis may also worsen or even first appear under this antiviral treatment, in spite of a good virological response to peg-IFN/RIB.^{1,3}

We report the case of a patient with chronic HCV infection who developed leucocytoclastic vasculitis, with the presence of numerous eosinophils and with peripheral neuropathy, after treatment with peg-IFN/RIB.

CASE PRESENTATION

A 35-year-old man presented to our department with a 2-month history of an ulcer localised on the right shin. He was diagnosed with chronic

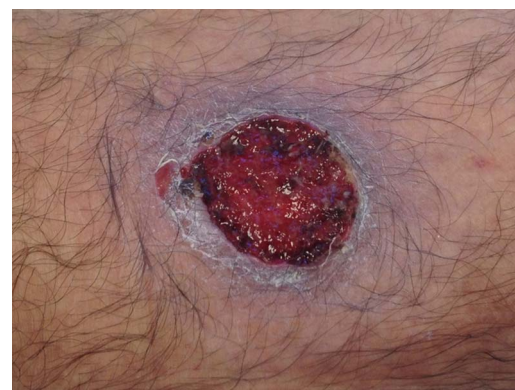

Figure 1 Ulcer, localised on the right shin, 3.3×3 cm in diameter, with a regular and elevated border, on a violaceous base, and granulation tissue.



CrossMark

To cite: Resende C, Pereira T, Ventura F, *et al.* *BMJ Case Rep* Published online: [please include Day Month Year] doi:10.1136/bcr-2015-209377

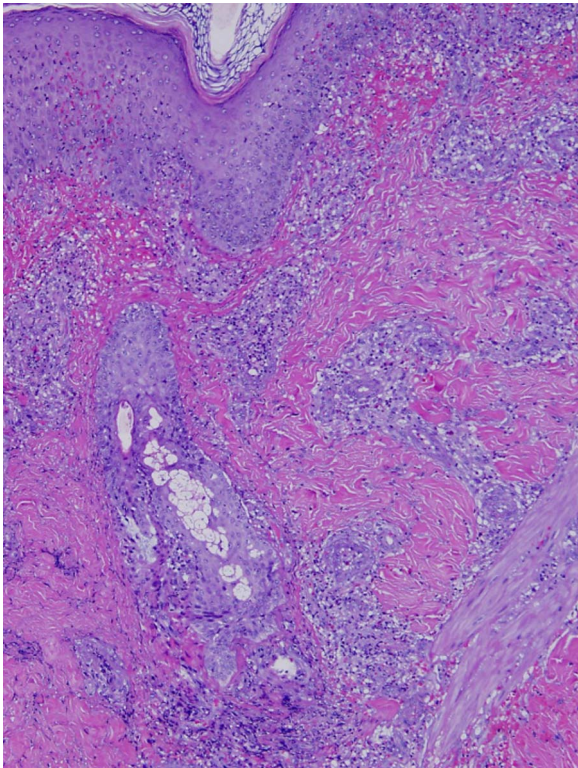


Figure 2 Histopathological examination of the border of the ulcer revealed a leucocytoclastic vasculitis, rich in eosinophils (H&E, $\times 100$).

TREATMENT

We suggested dressing the ulcer with hydrocellular foam, with a fresh dressing placed every 5 days.

OUTCOME AND FOLLOW-UP

At 3 months of follow-up, the ulcer had almost healed ([figure 4](#)). The patient maintains consultations with the gastroenterology department for treatment of his HCV infection.

DISCUSSION

Chronic HCV infection may be complicated by the development of vasculitis, which in most cases is attributed to the presence of mixed cryoglobulinaemia,³ leading to an immune complex-type vasculitis, predominantly involving small vessels.^{3 4} Vasculitis

occurs in $<5\%$ of cryoglobulinaemic patients and has a predilection for patients with type II cryoglobulins.³

Our patient developed cryoglobulinaemic vasculitis and peripheral neuropathy after treatment with peg-IFN/RIB.

The IFNs may cause new onset or exacerbation of vasculitis in patients with HCV infection.¹ Therefore, peg-IFN might have been involved in the development of LCV in our patient. Antiviral treatment with peg-IFN/RIB is the treatment of choice for chronic HCV infection.^{1 3} Mixed cryoglobulins have been identified in 40% of cases of HCV infection.^{3 4}

However, few reported cases of exacerbation of cryoglobulinaemic vasculitis under therapy with IFN or peg-IFN/RIB have been reported previously.^{3 4}

The mechanisms involved in the uncommon harmful effects of IFN on cryoglobulinaemia in patients with HCV infection remain uncertain.⁴ According to the literature regarding peg-IFN/RIB, peg-IFN is much more likely to be responsible for vasculitis than RIB, but we could not prove it without a challenge test.⁵

In our case, the history of chronic HCV infection, depressed levels of C4, positive cryoglobulins, the markedly elevation of the rheumatoid factor and the sensory neuropathy of the legs, after treatment with peg-IFN/RIB, suggest the diagnosis of cryoglobulinaemic vasculitis. The participation of numerous eosinophils in the histology supports a medicamentous etiology for the ulcer.^{4 5}

There is no correlation between IFN or peg-IFN/RIB dose or duration of treatment and the development of vasculitis.^{1 3} Symptoms may appear during treatment with peg-IFN/RIB or after several months after treatment.^{1 3} In our patient, the peg-IFN/RIB was discontinued 2 months after onset of treatment in spite of a good virological response, because of the appearance of peripheral arthralgias and peripheral neuropathy, and a vasculitic ulcer on his right shin 2 months later.

Regarding neuropathy, factors other than vasculitis can lead to neuropathic development, such as neurotoxic and antiangiogenic effects of IFN, during peg-IFN/RIB treatment.³

Treatment of vasculitis related to IFN depends on the severity of symptoms.^{3 5}

In some cases of IFN-induced vasculitis, symptoms improve spontaneously after discontinuation of IFN.³ In the presence of severe or progressive symptoms, suggestive of irreversible damage to vital organs, corticosteroids in combination with cyclophosphamide therapy should be given.^{3 5}

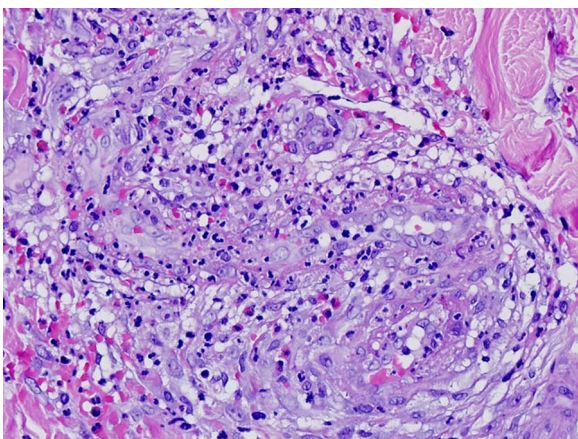


Figure 3 Histopathological examination of the border of the ulcer revealed a leucocytoclastic vasculitis, rich in eosinophils (H&E, $\times 400$).

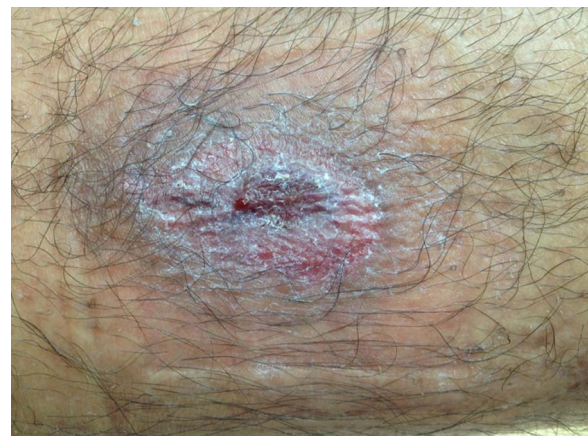

Figure 4 The ulcer, almost cured after 3 months of follow-up.

The safety of immunosuppressive treatment in patients with chronic HCV infection is unknown,³ and systemic corticosteroids could lead to increased viraemia in patients with HCV infection.^{1 3 6} Rituximab should be considered in patients with severe vasculitis, peripheral neuropathy or glomerulonephritis.⁷ Our patient did not undergo any systemic therapy, because the ulcer resolved with a hydrocellular foam dressing changed every 5 days.

In recent years, peg-IFN/RIB combined with direct acting antivirals, such as sofosbuvir, or direct acting antiviral-combined therapy, are the standard of care for HCV infection.^{8 9} Sofosbuvir belongs to the nucleotide inhibitors of viral polymerase NSSB and acts as a chain terminator during HCV replication.⁸ Regimens based on direct-acting antivirals increase treatment efficacy and allow treatment in peg-IFN-contraindicated patient populations.^{8 9}

Learning points

- ▶ Chronic hepatitis C virus (HCV) infection may be complicated by the development of vasculitis, which in most cases is attributed to the presence of mixed cryoglobulinaemia.
- ▶ The interferons (IFNs) may cause new onset or exacerbation of vasculitis in patients with HCV infection.
- ▶ There is no correlation between IFN or pegylated (peg) IFN/ribavirin (RIB) dose or duration of treatment and the development of vasculitis.
- ▶ Symptoms may appear during treatment with peg-IFN/RIB or after several months after treatment.

New treatment regimens to continue antiviral treatment against HCV could avoid causing the skin complications associated with peg-IFN.

Contributors CR contributed to the literature research, data collection, article writing and revision.

Competing interests None declared.

Patient consent Obtained.

Provenance and peer review Not commissioned; externally peer reviewed.

REFERENCES

- 1 Adışen E, Dizbay M, Hizel K, *et al.* Leukocytoclastic vasculitis during pegylated interferon and ribavirin treatment of hepatitis C virus infection. *Indian J Dermatol Venereol Leprol* 2008;74:60–2.
- 2 Marrache F, Consigny Y, Ripault MP, *et al.* Safety and efficacy of peg interferon plus ribavirin in patients with chronic hepatitis C and bridging fibrosis or cirrhosis. *J Viral Hepat* 2005;12:421–8.
- 3 Beuthien W, Mellinghoff H-U, Kempis J. Vasculitic complications of interferon-alpha treatment for chronic hepatitis C virus infection: case report and review of the literature. *Clin Rheumatol* 2005;24:507–15.
- 4 Batisse D, Karmochkine M, Jacquot C, *et al.* Sustained exacerbation of cryoglobulinaemia-related vasculitis following treatment of hepatitis C with peg interferon alfa. *Eur J Gastroenterol Hepatol* 2004;16:701–3.
- 5 Groves C, Devereux C, McMillan C. A case of cutaneous vasculitis with underlying hepatitis C and cryoglobulinaemia. *Ulster Med J* 2008;77:51–3.
- 6 Cacoub P, Terrier B, Saadoun D. Hepatitis C virus-induced vasculitis: therapeutic options. *Ann Rheum Dis* 2014;73:24–30.
- 7 Pietrogrande M, De Vita S, Zignego AL, *et al.* Recommendations for the management of mixed cryoglobulinemia syndrome in hepatitis C virus-infected patients. *Autoimmun Rev* 2011;10:444–54.
- 8 Degasperis E, Aghemo A. Sofosbuvir for the treatment of chronic hepatitis C: between current evidence and future perspectives. *Hepat Med* 2014;6:25–33.
- 9 Ruane PJ, Ain D, Stryker R, *et al.* Sofosbuvir plus ribavirin for the treatment of chronic genotype 4 hepatitis C virus infection in patients of Egyptian ancestry. *J Hepatol* 2015;62:1040–6.

Copyright 2015 BMJ Publishing Group. All rights reserved. For permission to reuse any of this content visit <http://group.bmj.com/group/rights-licensing/permissions>.
BMJ Case Report Fellows may re-use this article for personal use and teaching without any further permission.

Become a Fellow of BMJ Case Reports today and you can:

- ▶ Submit as many cases as you like
- ▶ Enjoy fast sympathetic peer review and rapid publication of accepted articles
- ▶ Access all the published articles
- ▶ Re-use any of the published material for personal use and teaching without further permission

For information on Institutional Fellowships contact consortiasales@bmjgroup.com

Visit casereports.bmj.com for more articles like this and to become a Fellow