

Observational study in takotsubo cardiomyopathy

Carina Arantes, António Gaspar, Alberto Salgado Salgado, Juliana Martins, Glória Abreu, Carlos Braga, Ségria Rocha, Adelino Correia.
Department of Cardiology, Hospital de Braga, Braga, Portugal

INTRODUCTION

Takotsubo cardiomyopathy (TC) is a still rarely diagnosed clinical syndrome, which is characterized by transient cardiac dysfunction with reversible wall motion abnormalities. Concepts about diagnosis, treatment and prognosis are still evolving.

PURPOSE

Determine the demographic characteristics, clinical presentation and prognosis of patients with TC.

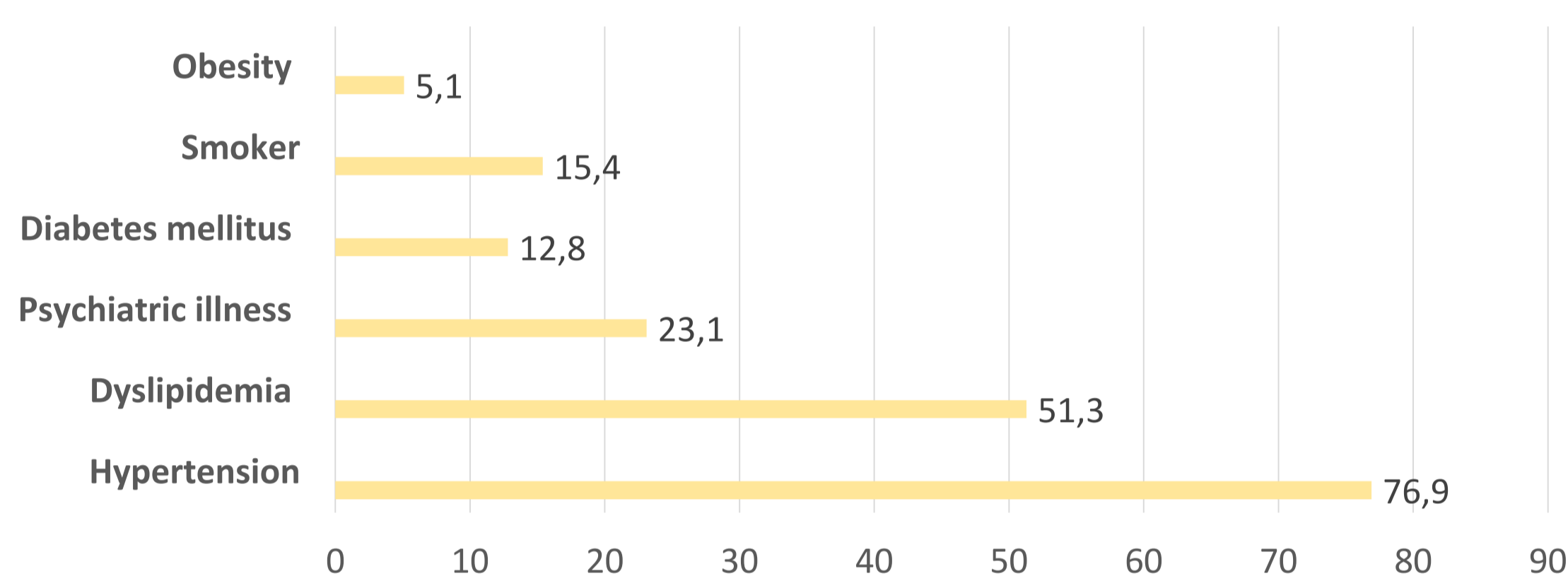
METHODS

Retrospective study of 39 patients admitted for TC in a cardiology center during a period of 3 years.

RESULTS

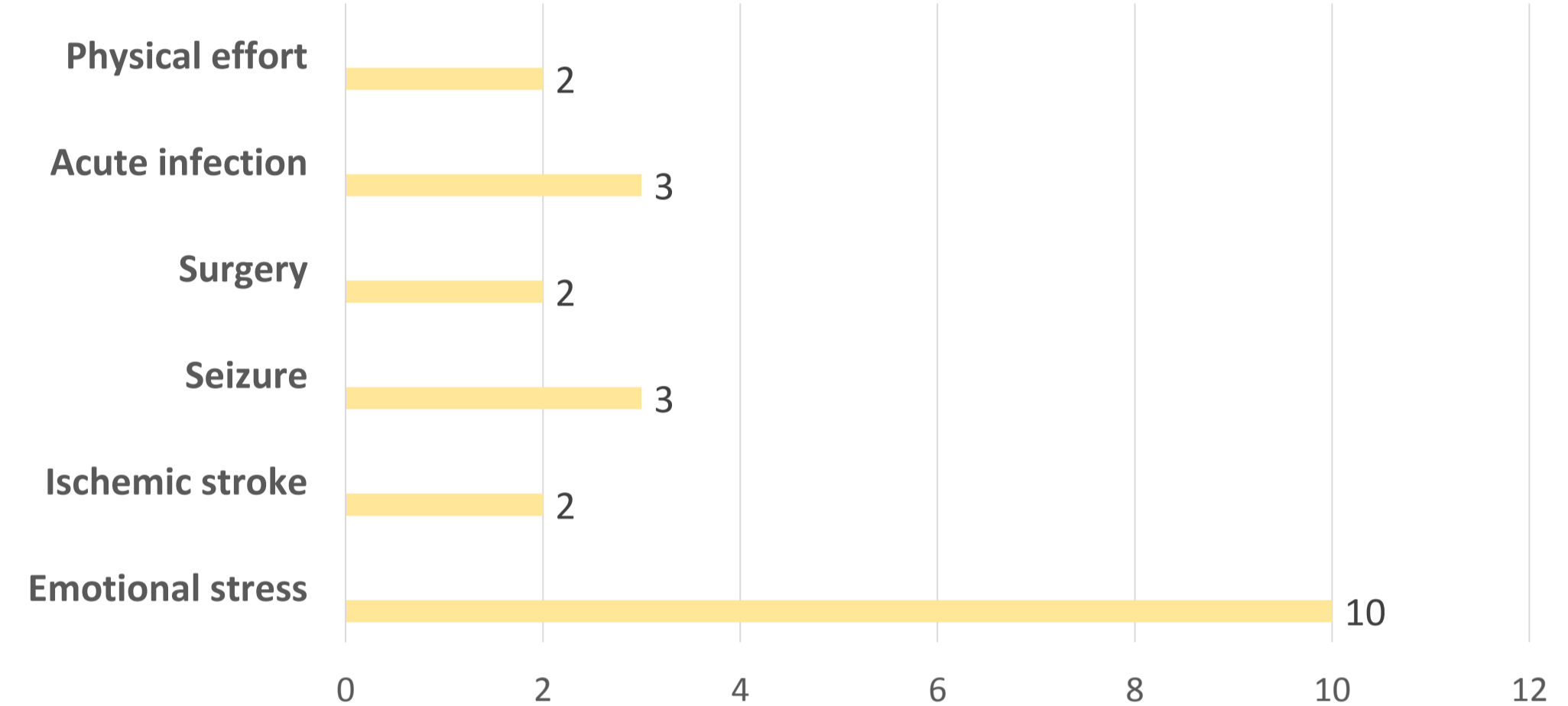
In the population studied, the mean age was 67.15±12.01 years and women were predominant (n = 29, 74.4%)

The most frequent comorbidities (%)



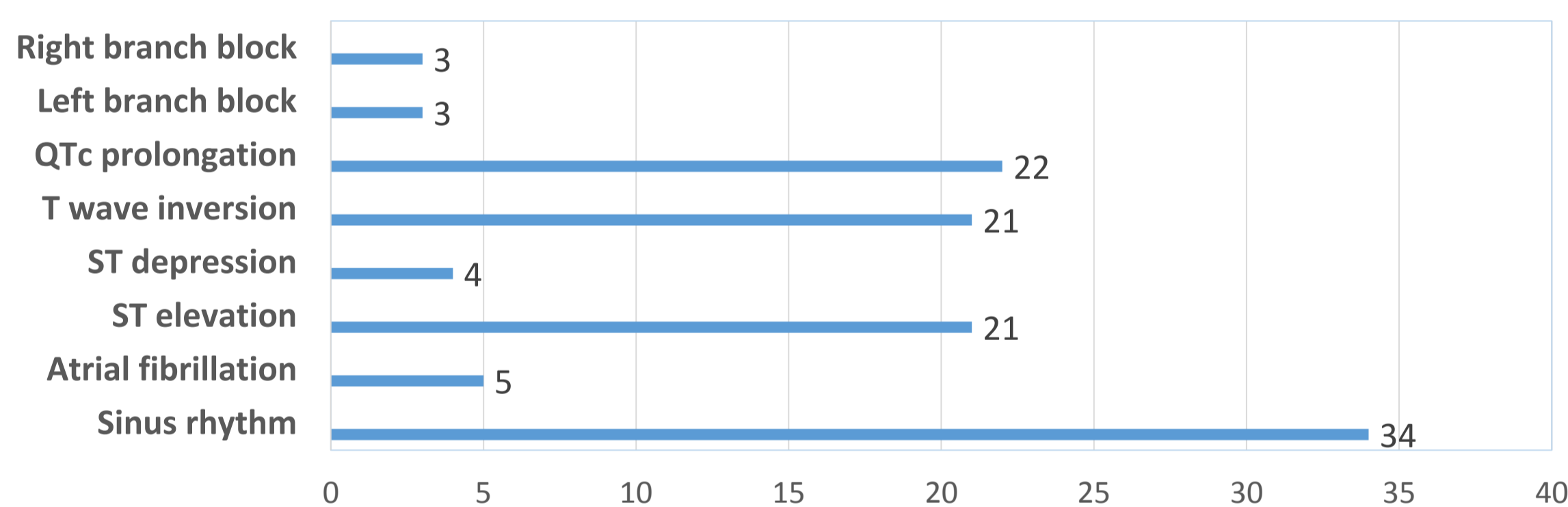
Cardinal symptoms which led to admission, were acute chest pain (n=28), dyspnoea (n=15) and nausea (n=9).

Precipitating factor (n)



In 17 patients we were not able to identify any triggering event

ECG findings (n)

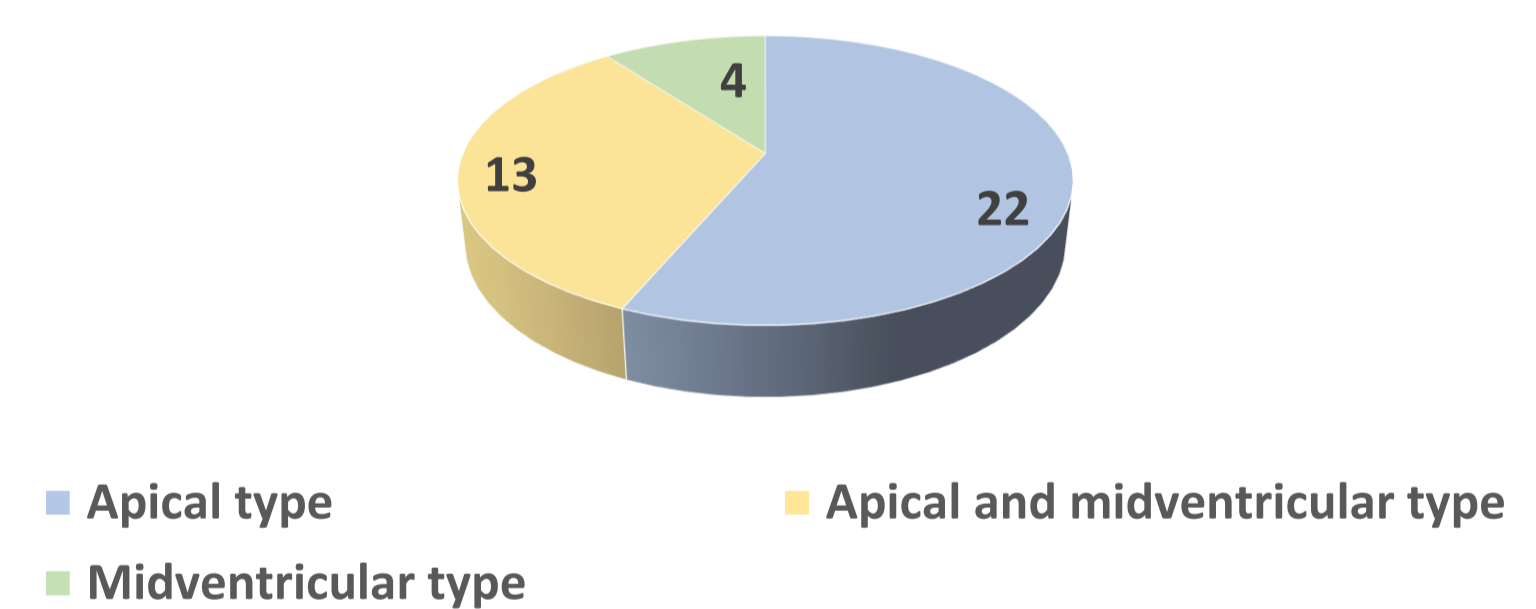


All patients underwent coronary angiography and 10 patients had no significant coronary lesions.

There was a significant increase in pBNP (mean = 10604 ± 13508 pg/ml) associated with modest elevation of troponin I (mean = 4.50 ± 4.12 ng/ml).

Wall motion abnormalities (n)

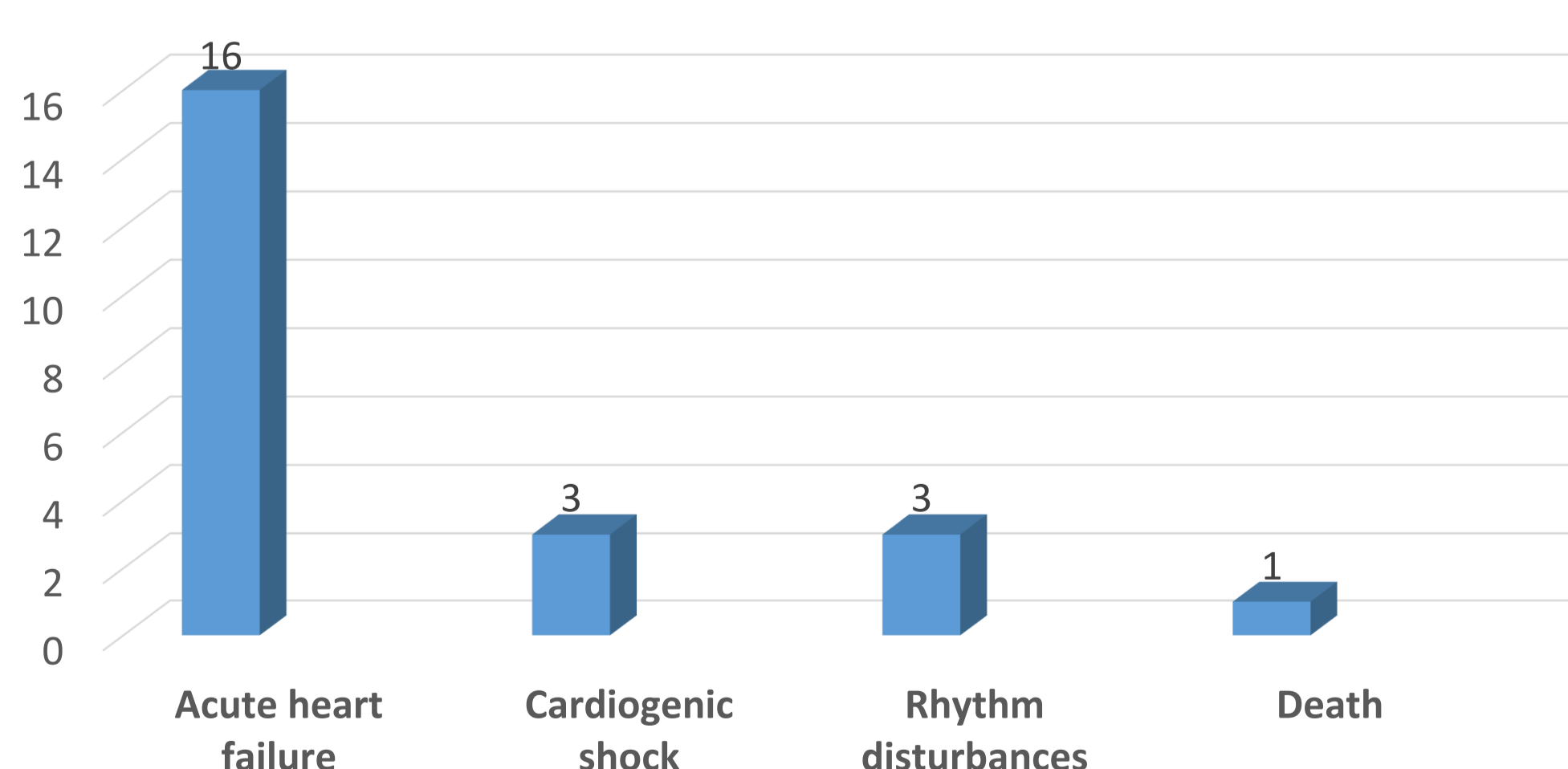
All patients had typical wall motion abnormalities in the echocardiography and/or ventriculography.



The mean ejection fraction was 35.59±5.54% and 46.2% of patients had severe depression of left ventricular systolic function (LVS).

The presence of moderate to severe LVS dysfunction (p=0.048) and higher levels of C reactive protein (p=0.02) and pBNP (p=0.042) were associated with the development of acute heart failure.

In-hospital complications (n)



Follow-up at 6 months

- All patients showed recovery of left ventricular systolic function (mean ejection fraction = 53.4%)
- There was one recurrence
- There was 3 deaths from non-cardiovascular causes

CONCLUSION

According to the literature, our review shows higher prevalence of TC in women and a clinical and electrocardiographic presentation similar to the picture of an acute coronary syndrome. In the acute phase, the TC is not necessarily a benign entity, because we observed a high prevalence of acute heart failure.