

# NONSECRETORY MULTIPLE MYELOMA

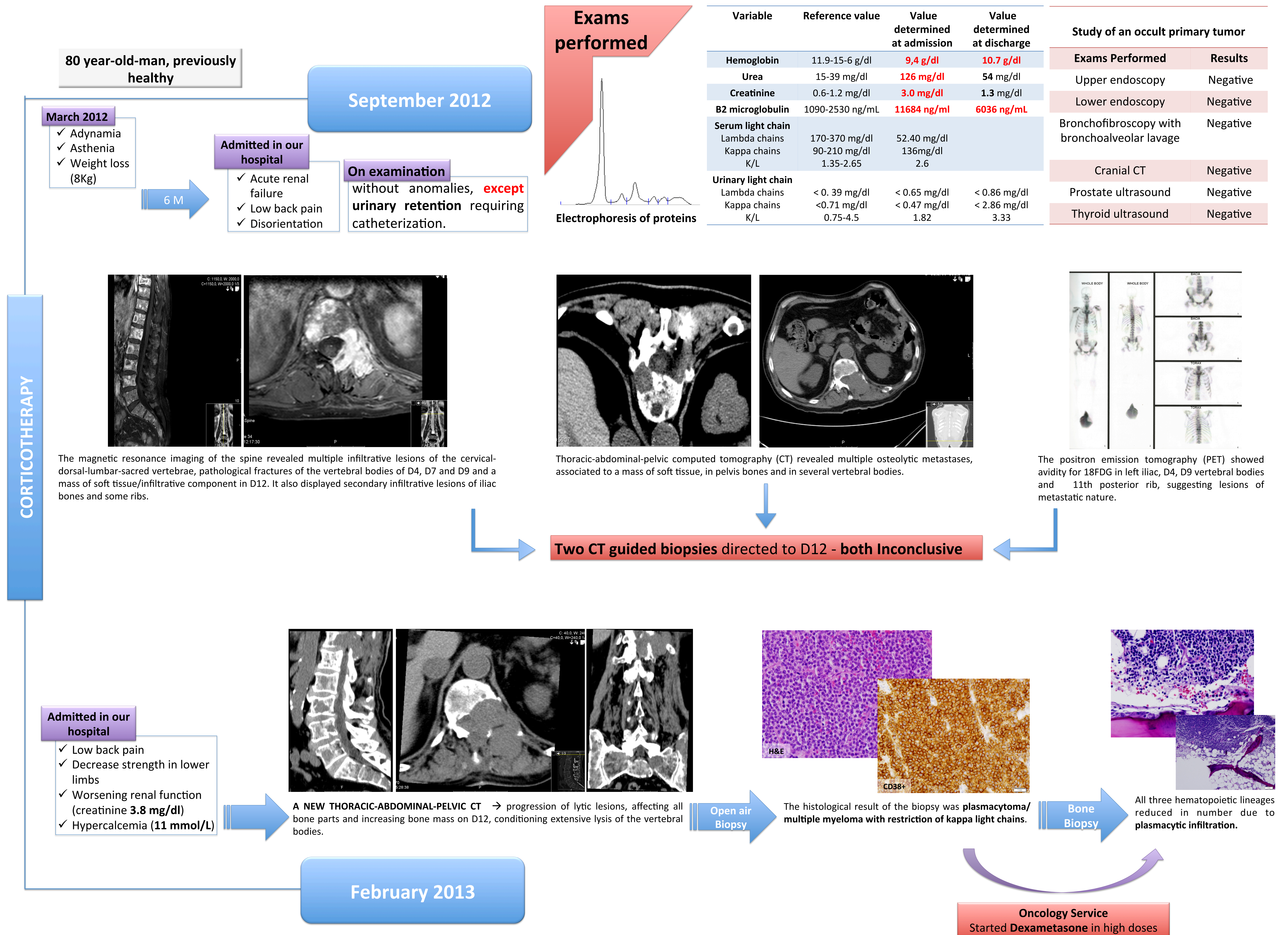
## A DIAGNOSTIC CHALLENGE

Glória Abreu<sup>1</sup>, A. P. Pacheco<sup>2</sup>, N. Fernandes<sup>2</sup>, J. Costa<sup>2</sup>, S. Esperança<sup>2</sup>, F. Gonçalves<sup>2</sup>  
 1 - Cardiology Service, Braga Hospital; 2 - Internal Medicine Service, Braga Hospital, Braga, Portugal

### INTRODUCTION

The Nonsecretory Multiple Myeloma is a rare variant (1-5 %) of the classical form of multiple myeloma (MM). Although clinically similar to MM, nonsecretory multiple myeloma is not associated with a monoclonal gammopathy in serum or urine, making it difficult diagnosis this entity.

### CASE DESCRIPTION



### DISCUSSION

The nonsecretory multiple myeloma is an uncommon entity, with clinical presentation similar to MM, which diagnosis requires histological evidence of plasmacytic infiltration. Limitations inherent to biopsy may delay correct treatment. However, whenever we are faced with an elderly with bone pain, acute renal failure and anemia of unknown etiology, one need to persist in the diagnosis of MM, not forgetting this rare entity that is nonsecretory multiple myeloma.