

Rare delayed complication of laparoscopic sacrocervicopexy with synthetic mesh

Neusa Fernandes Teixeira, Paula Serrano, Arlindo Ferreira, Domingos Jardim

Department of Obstetrics and Gynecology, Hospital de Braga, Portugal

Correspondence to
Dr Neusa Fernandes Teixeira,
neusa000@gmail.com

Accepted 1 August 2014

DESCRIPTION

We report a case of a 56-year-old-woman with obstetric/gynaecological history of two normal deliveries and diagnosis of pelvic organ prolapse (third degree uterine prolapse) at the age of 37. She underwent a laparoscopic sacrocervicopexy 16 years ago, in another medical institution. She

presented to the gynaecological outpatient clinic with pelvic pain and recurrent purulent vaginal discharge during the past 3 months. Examination showed purulent discharge arising from a small opening in the upper third of the right vaginal wall and a fistulography and an abdominopelvic MRI were requested. The fistulography demonstrated a vaginal fistula, not conclusive about the anatomical structures involved (figure 1). MRI revealed a right fistulous tract extending from vaginal towards a retroperitoneal saccular area, up to the promontory level, probably a pelvic abscess (figure 2A, B). A laparotomy was decided and intraoperative findings were consistent with a large abscess in the pre-sacral retroperitoneal space up to the level of promontory, inside which it was found a Y-shaped non-absorbable mesh inserted between lateral side-walls of cervix and promontory (figures 3 and 4). The patient underwent a hysterectomy, infected mesh removal, abscess drainage and retroperitoneal space exploration. The postoperative period was uneventful and she was discharged home well on the third postoperative day. At 3-month follow-up she was totally asymptomatic.

This is a report of an extremely rare delayed complication of a pelvic abscess associated with a vaginal fistula that presented 16 years after a laparoscopic sacrocervicopexy. The strategy involving identification, diagnostic approach and treatment management of mesh-related complications must be individualised.^{1 2}

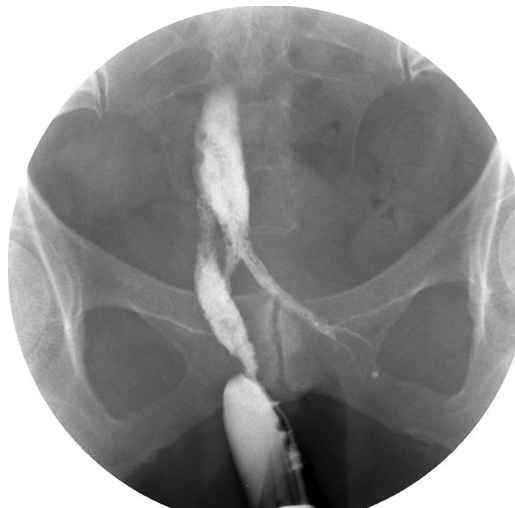


Figure 1 Fistulography: X-ray taken after contrast injection through the opening in the upper third of the right vaginal wall showing the length, shape and direction of the fistulous tract.

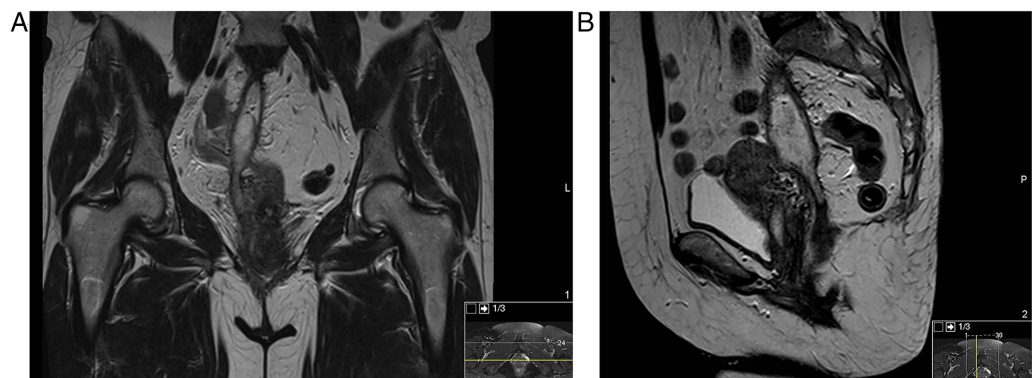


Figure 2 Abdominopelvic MRI with contrast: right fistulous tract from vagina communicating with a retroperitoneal abscess that extends up to the promontory level (A: coronal plane; B: sagittal plane).



To cite: Teixeira NF, Serrano P, Ferreira A, et al. *BMJ Case Rep* Published online: [please include Day Month Year] doi:10.1136/bcr-2014-206513

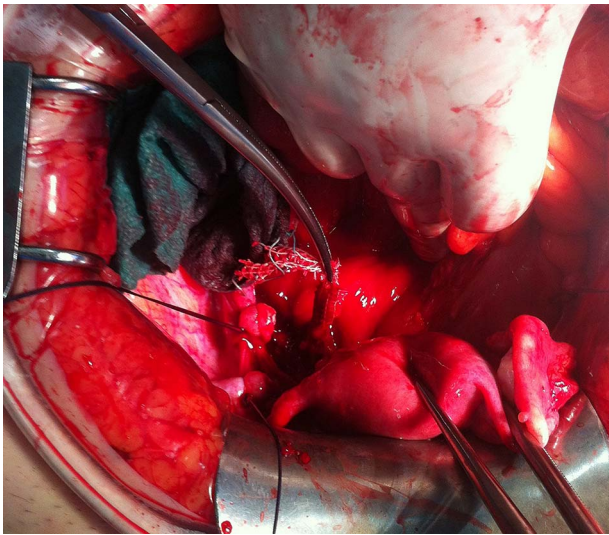


Figure 3 Intraoperative period: removal of the infected mesh.

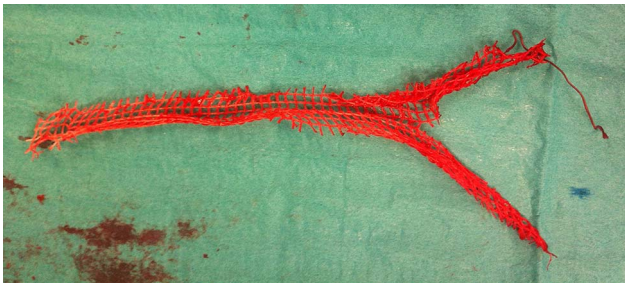

Figure 4 Y-shaped non-absorbable mesh that was surgically removed.

Learning points

- ▶ Although the use of meshes has become an effective method in pelvic organ prolapse surgery this is associated with a wide spectrum of potential complications.
- ▶ Be aware to mesh-related infections that can manifest many years after surgery.
- ▶ Clinicians/surgeons must be prepared to recognise, diagnose and treat late complications that can arise after mesh placement in pelvic organ prolapse surgery.

Acknowledgements The authors would like to thank the collaboration of the Department of Radiology.

Contributors NFT followed the patient in outpatient clinic. NFT, AF and DJ evaluated the patient. DJ, PS and NFT performed the surgery. NFT collected the data and wrote the manuscript. All the authors were involved in the conception of the work and revised it critically for important intellectual content as well. The authors approved the final version to be submitted/published.

Competing interests None.

Patient consent Obtained.

Provenance and peer review Not commissioned; externally peer reviewed.

REFERENCES

- 1 Shah H, Badlan G. Mesh complications in female pelvic floor reconstructive surgery and their management: a systematic review. *Indian J Urol* 2012; 28:129–53.
- 2 Falagas E, Velakoulis S, Iavazzo C, *et al*. Mesh-related infections after pelvic organ prolapse repair surgery. *Eur J Obstet Gynecol Reprod Biol* 2007; 134:147–56.

Copyright 2014 BMJ Publishing Group. All rights reserved. For permission to reuse any of this content visit <http://group.bmj.com/group/rights-licensing/permissions>.

BMJ Case Report Fellows may re-use this article for personal use and teaching without any further permission.

Become a Fellow of BMJ Case Reports today and you can:

- ▶ Submit as many cases as you like
- ▶ Enjoy fast sympathetic peer review and rapid publication of accepted articles
- ▶ Access all the published articles
- ▶ Re-use any of the published material for personal use and teaching without further permission

For information on Institutional Fellowships contact consortiasales@bmjgroup.com

Visit casereports.bmj.com for more articles like this and to become a Fellow