

## Vertebral osteoporotic fractures with height loss secondary to Cushing's disease

Nogueira C<sup>1</sup>, Souto SB<sup>2</sup>, Rios E<sup>3</sup>, Pereira J<sup>4</sup>, Vinha E<sup>1</sup>, Freitas P<sup>1</sup>, Carvalho D<sup>1</sup>

ACTA REUMATOL PORT. ONLINE FIRST

### To the editor,

A 37-year-old man was referred to our department due to osteoporosis complicated with vertebral and rib fractures and loss of six centimeters in height within the previous year. He also had hypertension, dyslipidemia, and secondary infertility and he was treated with alendronate and cholecalciferol. Physical examination revealed a moon face, central obesity, proximal muscle weakness, easy bruising, and kyphosis. Laboratory investigation showed ACTH dependent hypercortisolism [24-hour urinary free cortisol: 687.3µg/day (36–137); cortisol after a 1-mg overnight dexamethasone suppression test: 39.5µg/dL (<1.8); ACTH: 118pg/mL (< 53)]. Total testosterone was low [1.93mg/mL (2.8–8.0)]. Since pituitary magnetic resonance imaging showed no adenoma, he was submitted to bilateral inferior petrosal sinus sampling, which favored Cushing's disease (CD). Dual-energy X-ray absorptiometry (DXA) revealed osteoporosis of the lumbar spine (T-score -3.8, Z-score -3.8) and of the left femur (T-score -3.6, Z-score -2.7). A thoracic computed tomography showed multiple vertebral compression fractures in the thoracic spine and increased thoracic kyphosis (Figure 1). After cryopreservation of gametes, the patient was submitted to transsphenoidal surgery and histological findings confirmed the diagnosis. He refused surgical treatment of vertebral fractures. DXA performed five months after surgery showed osteoporosis of the lumbar spine (T-score -3.4, Z-score -3.6) and osteopenia of the left femur (T-score -2.0, Z-score -1.9). He is still un-

der treatment with alendronate and cholecalciferol.

Glucocorticoids (GCs) cause impaired bone formation due to direct effects both on osteoblasts and osteoclasts<sup>1</sup>. GCs also inhibit vitamin D action, reducing calcium absorption from the gastrointestinal tract and renal tubular calcium reabsorption<sup>2</sup>. The effects of GCs on gonadotropins, growth hormone and insulin-like growth factor-1 may also contribute to osteoporosis development, and catabolic effects of GCs on muscle enhance fracture risk.

Fractures are found in approximately 30-67% of patients with Cushing's syndrome (CS)<sup>1</sup>. Trabecular bone is more severely affected than cortical bone in GCs induced osteoporosis, because of its higher turnover rate and its greater sensitivity to GCs action<sup>3,4</sup>. Therefore, the vertebral bodies and ribs are the typical sites of fractures in CS. The European Registry on Cushing's syndrome showed that, in patients with any form of CS, men had significantly more vertebral and rib fractures compared with women (52 vs. 18% for vertebrae;  $p < 0.001$  and 34 vs. 23% for ribs;  $p < 0.05$ )<sup>5</sup>. Male gender was found to be an important risk factor for lumbar osteoporosis and fractures in CD<sup>6</sup>.

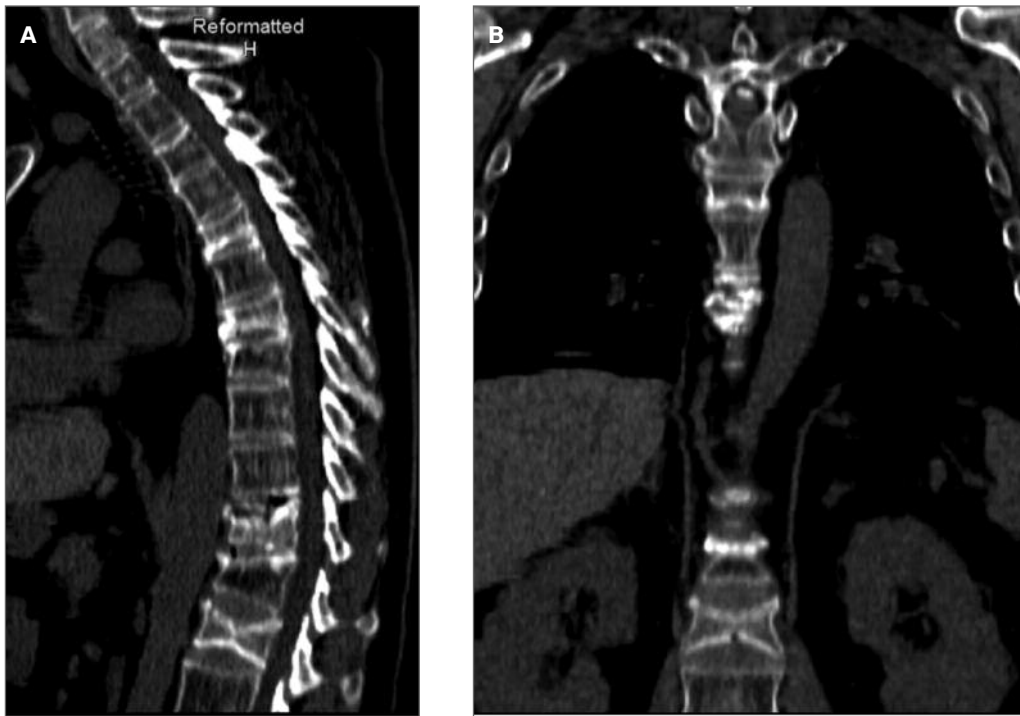
Disease severity and duration seem to play a crucial role in determining permanent damage to the spine. In this case, surgical treatment would be indicated but the patient refused. Some authors reported that GCs induced osteoporosis is reversible<sup>7</sup>, but recovery of bone loss is gradual and may continue for 10 years before BMD normalizes<sup>8</sup>. A recent study showed a significant increase in BMD at 3 months after surgery in the lumbar spine in patients cured of CS due to adrenocortical adenoma<sup>7</sup>. Another study reported that alendronate may induce a more rapid improvement in BMD than cortisol normalization alone, maybe by restoring the balance between bone formation and resorption<sup>9</sup>. It is also useful in patients with persistent postsurgical hypercortisolism. Since there is a substantial reduction of bone formation, treatment with an anabolic agent that

1. Department of Endocrinology, Diabetes and Metabolism, Centro Hospitalar São João, Porto, Portugal; Faculty of Medicine, University of Porto, Portugal

2. Department of Endocrinology, Hospital de Braga, Braga, Portugal

3. Department of Pathology, Centro Hospitalar São João, Porto, Portugal; Faculty of Medicine, University of Porto, Portugal; Institute of Molecular Pathology and Immunology at the University of Porto, Portugal

4. Department of Neurosurgery, Centro Hospitalar São João, Porto, Portugal



**FIGURE 1.** Reconstructed sagittal (1A) and coronal (1B) CT image shows numerous compression fractures involving the thoracic and lumbar spine, osteopenia and increased thoracic kyphosis

promotes bone formation and reduces vertebral and non-vertebral fractures has also been suggested<sup>1</sup>. Teriparatide is indicated to increase bone mass in men with primary or hypogonadal osteoporosis who are at high risk for fracture<sup>10</sup>. Although its use has not been studied in endogenous CS it is beneficial in patients with exogenous GCs induced osteoporosis.

In conclusion, this case illustrates the need to consider secondary causes of osteoporosis, namely Cushing's syndrome and other endocrinopathies, in a young patient with osteoporotic fractures.

#### CORRESPONDENCE TO

Cláudia Nogueira  
Serviço de Endocrinologia, Diabetes e Metabolismo  
Centro Hospitalar São João  
Alameda Professor Hernâni Monteiro  
4200-319 Porto-Portugal

#### REFERENCES

1. Katsas G, Makras P. Skeletal diseases in Cushing's syndrome: osteoporosis versus arthropathy. *Neuroendocrinology* 2010; 92 Suppl 1: 60-64.
2. Mazziotti G, Angeli A, Bilezikian JP, Canalis E, Giustina A. Glucocorticoid-induced osteoporosis: an update. *Trends Endocrinol Metab* 2006; 17: 144-149.
3. Sambrook PN. Corticosteroid osteoporosis: practical implications of recent trials. *J Bone Miner Res* 2000; 15: 1645-1649.
4. Francucci CM, Pantanetti P, Garrapa GG, Massi F, Arnaldi G, Mantero F. Bone metabolism and mass in women with Cushing's syndrome and adrenal incidentaloma. *Clin Endocrinol (Oxf)* 2002; 57: 587-593.
5. Valassi E, Santos A, Yaneva M, et al. The European Registry on Cushing's syndrome: 2-year experience. Baseline demographic and clinical characteristics. *Eur J Endocrinol* 2011; 165: 383-392.
6. Zilio M, Barbot M, Ceccato F, et al. Diagnosis and complications of Cushing's disease: gender-related differences. *Clin Endocrinol (Oxf)* 2014; 80: 403-410.
7. Kawamata A, Iihara M, Okamoto T, Obara T. Bone mineral density before and after surgical cure of Cushing's syndrome due to adrenocortical adenoma: prospective study. *World J Surg* 2008; 32: 890-896.
8. Mancini T, Doga M, Mazziotti G, Giustina A. Cushing's syndrome and bone. *Pituitary* 2004; 7: 249-252.
9. Di Somma C, Colao A, Pivonello R, et al. Effectiveness of chronic treatment with alendronate in the osteoporosis of Cushing's disease. *Clin Endocrinol (Oxf)* 1998; 48: 655-662.
10. Watts NB, Adler RA, Bilezikian JP, et al. Osteoporosis in men: an Endocrine Society clinical practice guideline. *J Clin Endocrinol Metab* 2012; 97: 1802-1822.