



SciVerse ScienceDirect

journal homepage: <http://www.elsevier.com/locate/rpor>

## Case report

## Entire hemithorax irradiation for Masaoka stage IVa thymomas

André Soares<sup>a,\*</sup>, Luís Vasco Louro<sup>a</sup>, Marta Almeida<sup>b</sup>, Olga Sousa<sup>a</sup><sup>a</sup> Radiotherapy Department, Instituto Português de Oncologia do Porto Francisco Gentil, E.P.E, Portugal<sup>b</sup> Oncology Department, Hospital Escala, Braga, Portugal

## ARTICLE INFO

## Article history:

Received 9 January 2012

Received in revised form

19 April 2012

Accepted 27 May 2012

## Keywords:

Thymoma

Stage IVa

Hemithoracic

Radiotherapy

## ABSTRACT

Thymomas are rare neoplasms that have an indolent growth with a preferentially intrathoracic dissemination pattern. Surgery is currently the standard treatment of thymomas; however radiotherapy is often used in an adjuvant setting due to a high sensitivity of these tumors to such treatment. Postoperative entire hemithoracic irradiation has been used in selected Masaoka stage IVa cases after complete surgical excision of metastatic lesions.

In the present article, the authors report three cases of Masaoka stage IVa thymoma that underwent entire hemithorax irradiation after surgical excision of metastatic lesions. The first two patients presented as stage IVa thymomas. The third case consisted of a pleural recurrence of a thymoma.

Hemithoracic irradiation with low doses has been used by different authors; the available data shows that it is a well-tolerated treatment that could potentially lead to better loco-regional control and increased overall survival.

© 2012 Greater Poland Cancer Centre. Published by Elsevier Urban & Partner Sp. z o.o. All rights reserved.

## 1. Background

Thymomas are a rare entity with an incidence of 1.5 new cases per million per year, representing 20–50% of all anterior mediastinal tumors in adults and 15% in children.<sup>1–4</sup> They occur with equal frequency in men and women and there is no preference for a particular race or geographic distribution.<sup>1–4</sup> It has a bimodal distribution regarding age at presentation; the first peak occurs in the 4th decade and is associated with myasthenia gravis, and the second one occurs in the 7th decade.<sup>5–8</sup>

These are malignant tumors that originate from the thymic epithelium and usually have an exuberant lymphoid component.<sup>8–11</sup> The World Health Organization's (WHO)

histological classification is the most widely used one in current clinical practice. It is based on cell morphology and the ratio between lymphocytes and epithelial cells.<sup>9–12</sup> Thymomas are classified according to the shape of the neoplastic cells as: type A (spindle or oval), type B (dendritic or epithelioid) and type C (thymic carcinoma). Type B thymomas are further divided according to the atypia of cells and proportion of thymocytes relative to lymphocytes: B1 thymomas are the richest in lymphocytes and B3 have a marked cellular atypia and rare lymphocytes.<sup>9–12</sup> Thymic carcinomas (type C) are designated according to their differentiation as: squamous cell, neuroendocrine, mucoepidermoid, basaloid, lymphoepithelioma, sarcomatoid, clear cell and papillary.<sup>9,10</sup>

\* Corresponding author. Tel.: +351 919806156.

E-mail address: [andre.coki@hotmail.com](mailto:andre.coki@hotmail.com) (A. Soares).

Thymomas have an indolent growth, 33% of patients are asymptomatic at presentation. Of the remaining (symptomatic) cases, 30–65% are associated with myasthenia gravis.<sup>1,8,10</sup>

The most widely adopted staging system is the one proposed by Masaoka. Lesions are staged according to the degree of spread as follows: stage I, completely encapsulated lesions; stage II, lesions with micro or macroscopic capsular invasion; stage III, lesions that invade adjacent organs (great vessels, lung, pericardium) and stage IV, disseminated disease, which is subdivided into IVa (pleural or pericardial implants) and IVb (embolic metastases).<sup>1,8,10–12</sup>

Surgery is currently the treatment of choice for thymomas. The criteria that need to be taken into account when deciding if and which adjuvant therapies are needed are: stage, histological grade and surgical margins. Adjuvant irradiation of tumor bed seems to be beneficial in stage I patients with incomplete resections, and all stages II and III patients, due to high recurrence rates even after complete resection.<sup>13–20</sup> The method by which radiation is delivered is also important (favoring high energy photons), as it has been demonstrated that it is an independent prognostic factor for overall survival (OS).<sup>21</sup>

In the meta-analysis by Korst and colleagues<sup>14</sup> the addition of adjuvant radiotherapy to surgical treatment reduced the percentage of recurrence in stage II, from 0–62% to 0–25% and in stage III, from 13–80% to 0–64%.

As documented in the literature, the most common sites of disease recurrence are: the pleural membranes, the lung, the pericardium and the diaphragm.<sup>19,20,22–25</sup>

Stage IVa thymomas and regional (intra-thoracic) recurrence are challenging in terms of treatment approach. Although considered a disseminated disease, pleural and pericardial lesions are often resectable and high survival rates are achievable.<sup>20,22–24</sup> Several authors have managed cases with extensive pleural disease treated with pleurectomy followed by total hemithoracic low dose irradiation, with good results and low morbidity.<sup>20,22–26</sup>

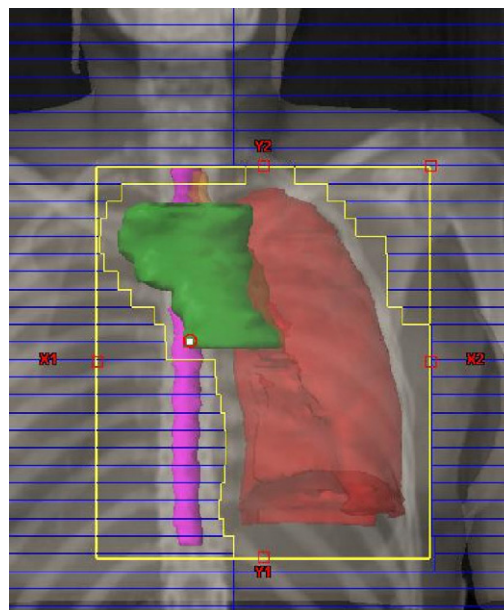
Three clinical cases are presented in the following section: two patients with stage IVa thymoma at diagnosis and one with pleural recurrence. All patients underwent surgical excision of pleural implants and total hemithoracic irradiation.

## 2. Case 1

Forty-one-year-old female, diagnosed with myasthenia gravis after the study of a persistent fatigue and asthenia. The computerized tomography (CT) acquired in April 2009 revealed a 4 cm × 3.5 cm anterior mediastinal lesion suggestive of thymoma as well as areas of thickening of the left pleura.

In June 2009, the patient underwent thoracoscopic resection of the thymoma. The histological results revealed a predominantly lymphocytic thymoma with an epithelial component, type B1. Biopsies were also taken of the suspicious pleural lesions that were diagnosed as metastasis of thymoma type B1. This yielded a Masaoka stage IVa.

An octreotide scan and a <sup>18</sup>FDG-PET/CT were also performed; the first did not show any anomalous uptake of the radionuclide, while the other revealed multiple foci of



**Fig. 1 – Entire left hemithorax and mediastinum volume.**

increased metabolism along the left posterior pleura and two foci in the base of the ipsilateral lung. The multidisciplinary tumor board proposed 5 cycles of chemotherapy with cyclophosphamide, adriamycin and cisplatin (CAP) which ended in October 2009. After chemotherapy a second evaluation with <sup>18</sup>FDG-PET/CT revealed a persistent disease.

It was decided to submit the patient to parietal and visceral pleurectomy and excision of the peripheral pulmonary lesions. The pathological findings were consistent with pulmonary and pleural metastasis of type B1 thymoma, R0 resection.

Subsequently, the patient underwent entire hemithorax and anterior mediastinum radiotherapy.

The entire left hemithorax received 12 Gy in 12 fractions of 1 Gy, 5 times a week with a three field technique (antero-posterior, postero-anterior and cranial-caudal right posterior oblique) with 6 MV photons plus 45 Gy in 25 fractions of 1.8 Gy, 5 days a week to the anterior mediastinum through 2 fields (anterior oblique and posterior oblique) with 6 MV photons (Figs. 1 and 2).

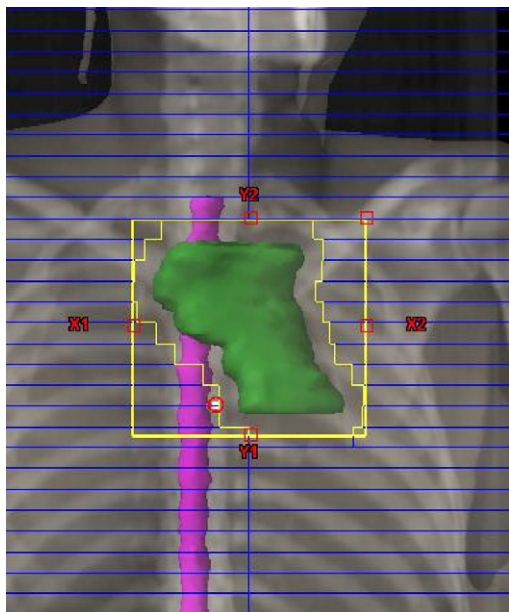
There were no complications during treatment. At the end of the treatment, the patient presented asthenia and dyspnea with ordinary effort. Respiratory sounds were equal bilaterally.

This patient changed residency and was lost to follow-up.

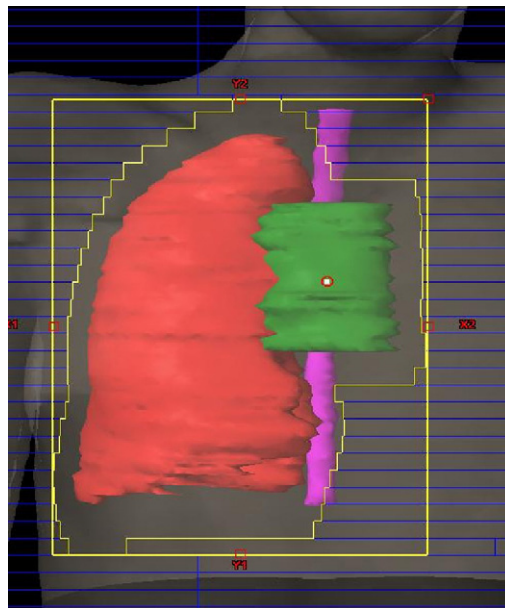
## 3. Case 2

Thirty-four-year-old female, presented with a history of non-productive cough, moderate dyspnea and weight loss.

A thorax CT was performed which showed extensive right pleural effusion, mediastinal shift to the left side, multiple right pleural suspicious lesions, the largest of them sized 13 cm × 8 cm. The fine needle biopsy was compatible with thymoma.



**Fig. 2 – Anterior mediastinum volume.**



**Fig. 3 – Right hemithorax and mediastinum volume.**

Assessment with an octreotide scan revealed an increased uptake of the radionuclide in the right hemithorax with extensive involvement of the anterior and posterior mediastinum.  $^{18}\text{F}$ FDG-PET/CT showed increased metabolism involving the entire right pleura.

The tumor board decided to treat the patient with 6 cycles of chemotherapy: cyclophosphamide, adriamycin, cisplatin (CAP) plus prednisolone.

The post chemotherapy  $^{18}\text{F}$ FDG-PET/CT showed partial response with persistent uptake foci in the thymus and pleura.

In February 2010, the patient was submitted to thymectomy and total parietal pleurectomy including resection of the pericardial and diaphragmatic pleura. Histologic examination revealed a type B2/B3 cortical thymoma with pleural invasion, R0 resection.

Then, she underwent adjuvant radiotherapy to the entire hemithorax and anterior mediastinum.

The entire right hemithorax (Fig. 3) received 12 Gy in 12 fractions of 1 Gy, 5 times a week with a two field technique (antero-posterior and postero-anterior) with 6 MV photons, plus 45 Gy in 25 fractions of 1.8 Gy, 5 days a week to the anterior mediastinum (Fig. 4) through 4 fields (antero-posterior, postero-anterior, right oblique and left anterior oblique) with 6 MV photons (Figs. 3 and 4).

There were no complications during treatment. At the end of the treatment, the patient presented a right chest pain, but no respiratory symptoms. Pulmonary auscultation revealed diminished respiratory sounds on the base of the right lung.

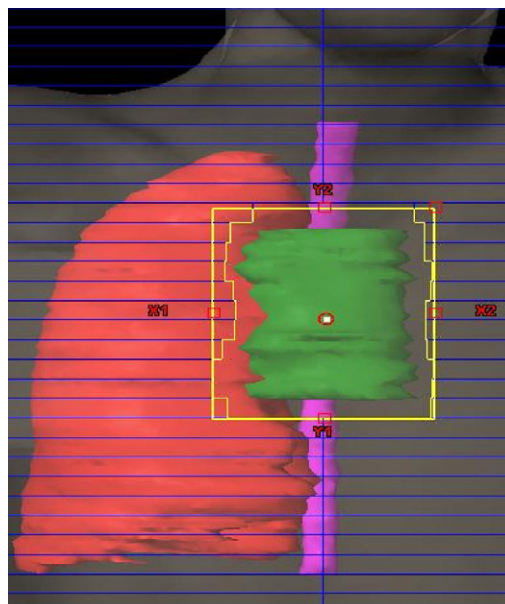
Three months after RT, the patient reported asthenia, dyspnea on doing more than ordinary effort, and right thoracic pain. Pulmonary sounds on the base of the right lung were diminished.

On December 2011, the patient had no symptoms or any evidence of recurrent disease.

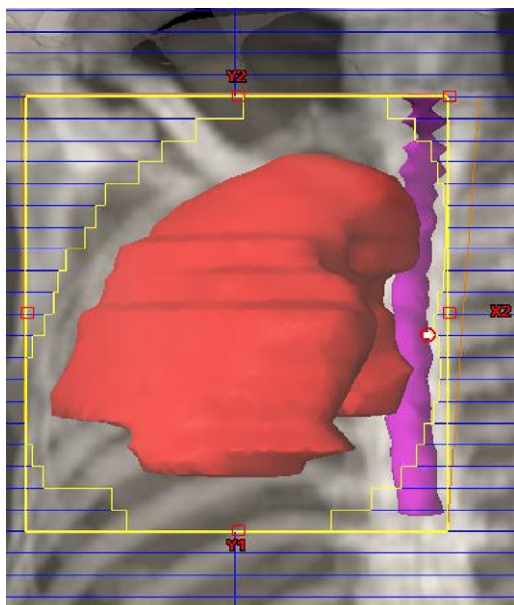
#### 4. Case 3

Fifty-two-year-old male, diagnosed with Masaoka stage III thymoma B3 in 2000 after total thymectomy. Between July and August 2000, he was submitted to adjuvant radiotherapy to the anterior mediastinum (total dose of 45 Gy in 25 fractions with 6 MV photons).

In 2005, the patient underwent surgical excision of right pleural suspicious lesions that were pathologically diagnosed as thymoma metastases, R1 resection.



**Fig. 4 – Anterior mediastinum volume.**



**Fig. 5 – Entire right hemithorax volume.**

The patient completed six cycles of chemotherapy with cisplatin, vincristine, doxorubicin and cyclophosphamide (ADOC regimen) by December 2005.

In 2007, a pleural recurrence was diagnosed and he was submitted to 11 cycles of chemotherapy – FOLFOX – achieving a complete remission (assessed by  $^{18}\text{F}$ FDG-PET/CT).

Due to a new pleural relapse in 2008, the patient was once again subjected to chemotherapy – Carboplatin and Paclitaxel – achieving stabilization of the disease until March 2010. Because of disease progression, the patient underwent an incomplete surgical excision of pleural lesions that were also compatible with pleural metastases of thymoma.

The tumor board then proposed entire hemithorax irradiation, which the patient accepted.

The patient performed 3D conformal radiotherapy with the following plan: 12Gy to the entire right hemithorax (Fig. 5) in 12 fractions of 1Gy each, 5 days a week, using 6MV photons through 4 fields (antero-posterior, postero-anterior, right lateral and left lateral).

There were no complications during treatment. At the end of the treatment the patient reported no respiratory or any other significant symptoms. Pulmonary sounds were diminished on the inferior half of the right lung.

On December 2011, the patient had no symptoms or any evidence of recurrent disease.

## 5. Discussion

Given the rarity of thymomas, its therapeutic approach has been evaluated solely in retrospective series. Furthermore, the therapeutic management of stage IVa is only mentioned in small series and case-reports.

In the initial Masaoka publications, patients with initial stage IV (including IVa and IVb) had survival rates of approximately 50% at 5 years and 0% at 10 years.<sup>24</sup> Since then, several authors have argued that a multimodal treatment approach

may increase the resectability of the disease and reduce recurrence rates.<sup>20</sup>

This multimodal approach should include preoperative or postoperative chemotherapy,<sup>1,2,4,20,25</sup> extensive surgery with maximum possible resection of the pleural disease and postoperative radiotherapy to the thymic bed with low dose irradiation to the entire involved hemithorax.<sup>24–26</sup>

In these stages, the most widely used chemotherapy schemes in the literature are based on cisplatin or doxorubicin, including ADOC (cisplatin, doxorubicin, vincristine and cyclophosphamide) and PAC (cisplatin, cyclophosphamide, and doxorubicin) with or without the addition of corticosteroids.<sup>1,2,20,25</sup> The review performed by Kondo<sup>20</sup> that included thymomas in advanced stages (III and IV) confirmed the benefit of adding chemotherapy, since it allowed to achieve an objective response in 67–100% of patients and complete responses in about 33%.

The surgical treatment of stage IVa (or pleural recurrence) cases consists in the maximum possible resection of all pleural and/or pericardial implants using, if necessary, extensive pleurectomy or resection of the pericardium. Despite the aggressiveness of this approach, Huang et al.<sup>25</sup> presented a series of 18 patients who underwent pleurectomy and wedge resections of involved lung with low morbidity, no operative mortality and high OS.

The rationale of using post-operative hemithoracic irradiation is based on three main points: the known sensitivity of such tumors to radiation; the known application of this radiotherapy technique in mesotheliomas after extra-pleural pneumonectomy and the fact that the risk of recurrence of the disease is much higher loco-regionally than distantly.<sup>8,10,14</sup> In this context, radiotherapy doses more often reported have been between 11.2 Gy and 16 Gy in 7–10 fractions.

Uematsu et al.<sup>27</sup> used total hemithoracic irradiation prophylactically in stages II and III, using doses between 10–16 Gy in 10–16 fractions. Recurrence-free survival of 100% at 5 years was achieved in the entire hemithorax irradiation group (with good clinical tolerance) versus 66% in the group that only received radiotherapy to the thymic bed. This reinforces the idea that the addition of radiotherapy is beneficial and produces low side effects.

According to Huang et al.,<sup>25</sup> this multimodal approach achieves OS rates of 91%, 78% and 65% at 3, 5 and 10 years, respectively, which is much higher than initially reported.<sup>24</sup>

## 6. Conclusion

There are few studies about the optimal therapeutic approach for stage IVa thymomas. Some publications report that for selected patients in stage IVa, postoperative (excision of metastatic lesions) radiotherapy to the entire hemithorax with doses ranging from 11 to 16 Gy with fractions of 1–1.6 Gy should be considered.

Total hemithoracic irradiation after resection of pleural lesions, appears to reduce the risk of pleural recurrence with acceptable toxicity. This could potentially lead to improvement in OS rates.

Prospective multicenter studies are needed to assess and validate the effectiveness of this modality approach to treat Masaoka stage IVa thymoma.

### Conflict of interest

None declared.

### Financial disclosure

None declared.

### REFERENCES

- Lu JJ, Tham IWK, Kong F-M. Thymic tumors. In: Lu JJ, Brady LW, editors. *Decision making in radiation oncology*, vol. 2. Heidelberg: Springer; 2011. p. 309–28.
- Wright CD. Management of thymomas. *Crit Rev Oncol Hematol* 2008;**65**(2):109–20.
- Engels EA. Epidemiology of thymoma and associated malignancies. *J Thorac Oncol* 2010;**5**(October (10 Suppl. 4)):S260–5.
- Venuta F, Anile M, Diso D, et al. Thymoma and thymic carcinoma. *Eur J Cardiothorac Surg* 2010;**37**(January (1)):13–25.
- Lucchi M, Ricciardi R, Melfi F, et al. Association of thymoma and myasthenia gravis: oncological and neurological results of the surgical treatment. *Eur J Cardiothorac Surg* 2009;**35**(May (5)):812–6, discussion 816.
- Marcin Z. Management of myasthenic patients with thymoma. *Thorac Surg Clin* 2011;**21**(1):47–57.
- Lee BW, Ihm SH, Shin HS, Yoo HJ. Malignant thymoma associated with myasthenia gravis, Graves' disease, and SIADH. *Intern Med* 2008;**47**(11):1009–12.
- Hung AY, Eng TY, Scarbrough TJ, Fuller Jr CD. CRT. Mediastinum and trachea. In: Halperin EC, Perez CA, Brady LW, editors. *Perez and Brady's principles and practice of radiation oncology*. 5th ed. Philadelphia: Wolters Kluwer Health/Lippincott Williams & Wilkins; 2008. p. 1109–17.
- Marchevsky AM, Gupta R, McKenna RJ, et al. Evidence-based pathology and the pathologic evaluation of thymomas. *Cancer* 2008;**112**(12):2780–8.
- Sovak MA, Aisner SC, Aisner J. Tumors of the pleura and mediastinum. In: Abeloff MD, Armitage J, Niederhuber J, Kastan M, McKenna W, editors. *Abeloff's clinical oncology*. 4th ed. Philadelphia: Churchill Livingstone/Elsevier; 2008. p. 1367–98.
- Suster S. Diagnosis of thymoma. *J Clin Pathol* 2006;**59**(December (12)):1238–44.
- Hosaka Y, Tsuchida M, Toyabe S-i., Umezumi H, Eimoto T, Hayashi J-i. Masaoka stage and histologic grade predict prognosis in patients with thymic carcinoma. *Ann Thorac Surg* 2010;**89**(March (3)):912–7.
- Fuller CD, Housman DM, Thomas CR. Radiotherapy for thymoma and thymic carcinoma. *Hematol Oncol Clin North Am* 2008;**22**(June (3)):489–507.
- Korst RJ, Kansler AL, Christos PJ, Mandal S. Adjuvant radiotherapy for thymic epithelial tumors: a systematic review and meta-analysis. *Ann Thorac Surg* 2009;**87**(May (5)):1641–7.
- Eng TY, Thomas Jr CR. Radiation therapy in the management of thymic tumors. *Semin Thorac Cardiovasc Surg* 2005;**17**(Spring (1)):32–40.
- Forquer JA, Rong N, Fakiris AJ, Loehrer PJ, Johnstone PAS. Postoperative radiotherapy after surgical resection of thymoma: differing roles in localized and regional disease. *Int J Radiat Oncol Biol Phys* 2010;**76**(2):440–5.
- Ogawa K, Uno T, Toita T, et al. Postoperative radiotherapy for patients with completely resected thymoma: a multi-institutional, retrospective review of 103 patients. *Cancer* 2002;**94**(March (5)):1405–13.
- Utsumi T, Shiono H, Kadota Y, et al. Postoperative radiation therapy after complete resection of thymoma has little impact on survival. *Cancer* 2009;**115**(December (23)):5413–20.
- Patel S, Macdonald OK, Nagda S, Bittner N, Suntharalingam M. Evaluation of the role of radiation therapy in the management of malignant thymoma. *Int J Radiat Oncol Biol Phys* 2011 [Epub 2011 May 17].
- Kondo K. Optimal therapy for thymoma. *J Med Invest* 2008;**55**(February (1–2)):17–28.
- Hetnał M, Małecki K, Wolanin M, Korzeniowski S, Walasek T. Thymoma: results of treatment and role of radiotherapy. *Rep Pract Oncol Radiother* 2010;**15**(1):15–20.
- Tagawa T, Kometani T, Yamazaki K, et al. Prognosis and therapeutic response according to the World Health Organization histological classification in advanced thymoma. *Surg Today* 2011;**41**(December (12)):1599–604.
- Huang J, Riely GJ, Rosenzweig KE, Rusch VW. Multimodality therapy for locally advanced thymomas: state of the art or investigational therapy? *Ann Thorac Surg* 2008;**85**(February (2)):365–7.
- Sugie C, Shibamoto Y, Ikeya-Hashizume C, et al. Invasive thymoma: postoperative mediastinal irradiation, low-dose entire hemithorax irradiation in patients with pleural dissemination. *J Thorac Oncol* 2008;**3**(1):75–81, 10.1097/JTO.1090b1013e31815e3181831873.
- Huang J, Rizk NP, Travis WD, et al. Feasibility of multimodality therapy including extended resections in stage IVA thymoma. *J Thorac Cardiovasc Surg* 2007;**134**(December (6)):1477–84.
- Yano M, Sasaki H, Yukiue H, et al. Thymoma with dissemination: efficacy of macroscopic total resection of disseminated nodules. *World J Surg* 2009;**33**(July (7)):1425–31.
- Uematsu M, Yoshida H, Kondo M, et al. Entire hemithorax irradiation following complete resection in patients with Stage II–III invasive thymoma. *Int J Radiat Oncol Biol Phys* 1996;**35**(2):357–60.