

Short Communication

Diversity in anti-N-methyl-D-aspartate receptor encephalitis: Case-based evidence

João Pinho, MD, João Rocha, MD, Margarida Rodrigues, MD, João Pereira, MD, Ricardo Maré, MD, Carla Ferreira, MD, Esmeralda Lourenço, MD and Pedro Beleza, MD*

Neurology Department, Hospital de Braga, Braga, Portugal

Antibodies against N-methyl-D-aspartate receptor (NMDAR) are identified in the form of immune-mediated encephalitis in which typical manifestations include neuropsychiatric symptoms, seizures, abnormal movements, dysautonomia and hypoventilation. The authors report two cases of anti-NMDAR encephalitis with different presentations and patterns of progression. The first patient presented with status epilepticus and later developed psychosis, pyramidal signs and diffuse encephalopathy. The second patient

presented with acute psychosis followed a week later by seizures, dystonia, rigidity, oromandibular dyskinesias and dysautonomia. Possible mechanisms responsible for the clinical manifestations of this disease are discussed in light of recently described additional clinical and laboratory findings.

Key words: encephalitis, immune-mediated, N-methyl-D-aspartate receptor.

ENCEPHALITIS WITH ANTIBODIES against N-methyl-D-aspartate receptors (anti-NMDAR) is an immune-mediated encephalitis in which antibodies against neuronal surface antigens are found.¹ In 2005, patients with paraneoplastic encephalitis presenting with psychiatric manifestations, short-term memory loss, hypoventilation and autoantibodies against unknown neuropil antigens were described.^{2,3} Subsequently, antibodies against NMDAR-NR1/NR2 heteromers were identified, and NR1 was considered the crucial epitope.^{4,5} Patients were young adult women with typical manifestations: initial psychiatric symptoms followed by seizures, dyskinesias, chorea, autonomic instability and central hypoventilation. Psychiatric manifestations are variable, including anxiety, bizarre behavior, mania, hallucinations, delusions, and pose diagnostic difficulties at onset. Lymphocytic pleocytosis, high protein or positive oligoclonal bands in cerebrospinal fluid (CSF)

are frequent.⁵ Pattern of progression and spectrum of manifestations led to the hypothesis of immunological response spreading against other central nervous system antigens.^{6,7} We report two patients with anti-NMDAR encephalitis and discuss underlying pathophysiologic mechanisms.

CASE REPORTS

Case 1

A 63-year-old Caucasian male with a medical history of febrile seizures was admitted for left facial motor status epilepticus. Despite treatment with phenytoin and valproate, he developed convulsive status epilepticus, requiring intensive care unit admission. CSF revealed high protein (0.78 g/L), positive unmatched oligoclonal bands, but was otherwise normal, including herpes simplex virus polymerase chain reaction (HSV-PCR). IV acyclovir was administered for 14 days. Brain magnetic resonance imaging (day 1) showed multiple cortical lesions (Fig. 1). On day 4, he had decreased consciousness, severe dysarthria and dysphagia, left hemiparesis and electroencephalography (EEG) showed a right temporal status

*Correspondence: Pedro Beleza, MD, Neurology Department, Hospital de Braga, Sete Fontes, São Victor, 4701-243 Braga, Portugal.
Email: beleza.76@gmail.com

Received 23 December 2010; revised 12 October 2011; accepted 4 November 2011.

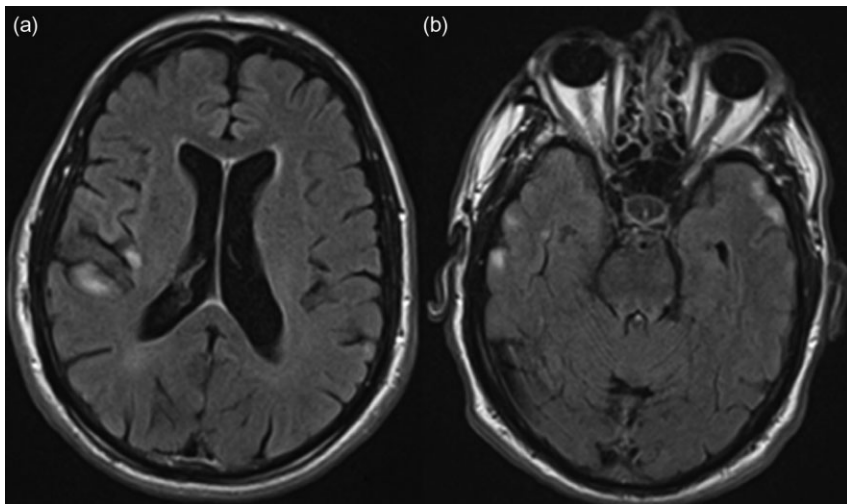


Figure 1. Brain magnetic resonance imaging, fluid attenuated inversion recovery – hyperintense lesions in right fronto-opercular, (a) right insular and (b) bilateral temporal cortex. Absent diffusion-weighted imaging abnormality or contrast enhancement.

epilepticus. Subsequently he developed persecutory delusions, and visual and auditory hallucinations which improved with olanzapine. During psychosis, EEG revealed moderate encephalopathy and no epileptiform activity. Extensive blood testing was normal. Between days 20 and 58 he became progressively stuporous with bilateral extensor plantars. High-dose IV methylprednisolone, followed by a 5-day course of IV immunoglobulins (IgIV), led to significant clinical improvement. Investigation for occult tumor was negative. Recurrence of psychosis occurred 1 month later, and examination revealed dysarthria, multifocal myoclonus and ataxic gait. Phenytoin intoxication was found, it was replaced by levetiracetam and after a 5-day course of IgIV, he recovered rapidly and has been asymptomatic for 3 years. Anti-NMDAR NR2B analysis was performed using a Western blot technique:⁸ antibodies in serum were IgG-positive and IgM-negative; in CSF both IgG and IgM were negative (samples collected several weeks after presentation and IV methylprednisolone).

Case 2

A 21-year-old previously healthy Caucasian woman was admitted for acute onset of delusions, ideas of grandeur, and visual and auditory hallucinations. Recent hallucinogenic drug ingestion was suspected. She had received a booster vaccination against tetanus 3 days earlier and since then had flu-like symptoms. She was admitted to the Psychiatry

Department, treated with risperidone, diazepam and a week later had a generalized seizure. At first neurological evaluation she was drowsy, with no verbal response, had generalized right-side predominant rigidity, with catatonia cerea, dystonia of the upper limbs, oromandibular dyskinesias and episodes of sinus tachycardia and peripheral desaturation. Extensive blood testing and urine toxicological screen were normal. CSF showed lymphocytic pleocytosis (10 cells/uL, 95% lymphocytes) and was otherwise normal including HSV-PCR and oligoclonal bands. Brain magnetic resonance imaging was normal (including T2, diffusion-weighted imaging and contrast-T1). EEG revealed left frontotemporal status epilepticus. Status epilepticus persisted despite phenytoin, levetiracetam and clonazepam. Brain positron emission tomography (PET) scan revealed left frontotemporal and left basal ganglia hypermetabolism (Fig. 2). Treatment with IgIV during 5 days and, later, a 5-day course of IV methylprednisolone led to progressive clinical improvement. At discharge she had attention and arithmetic deficits, global dysphasia and normal motor exam. She scored 17 in a Mini Mental State Examination. Investigation for occult tumor was negative, slow cognitive and language improvement was documented as the patient gradually recovered functional independence, with more than 18 months of follow up. Immunofluorescent cell-based assay was used to determine anti-NMDAR NR1/NR2:⁶ serum and CSF collected 3 weeks after admission were positive for anti-NMDAR NR1/NR2.

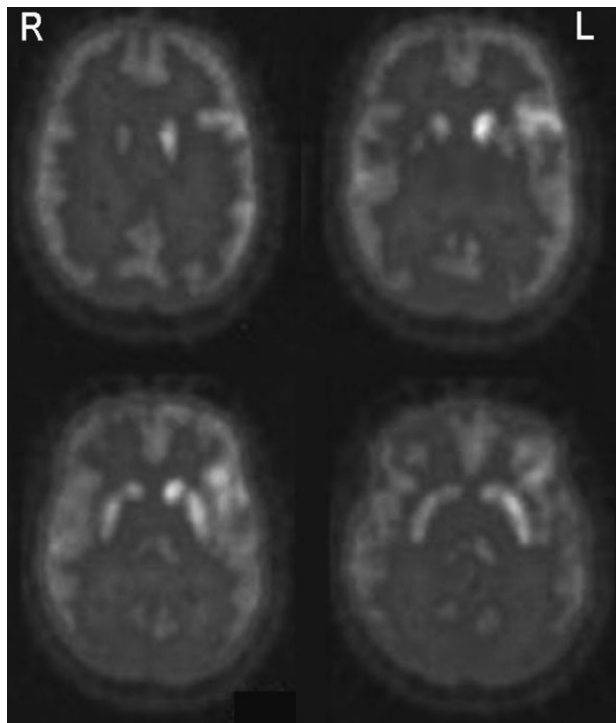


Figure 2. Brain positron emission tomography scan – left frontotemporal and left basal ganglia hypermetabolism.

DISCUSSION

Early clinical manifestations in both patients (convulsive status epilepticus and psychiatric manifestations) were likely secondary to cortical dysfunction. Suggested underlying mechanisms include direct neuronal damage of anti-NMDAR antibodies, cell deposition of membrane attack complex, antibody-mediated NMDAR internalization and decreased synaptic NMDAR-mediated postsynaptic currents.⁹ Additional manifestations developed in a time-dependent pattern: acute psychosis and other deficits in the first patient were possibly secondary to widespread cortical dysfunction, while the second patient developed basal ganglia and brainstem signs. Findings must be interpreted with caution. Antibodies against NMDAR-NR2B determined by Takahashi and collaborators' technique were found in a heterogeneous population of patients.^{10–12} NMDAR are transmembrane proteins consisting of a combination of NR1, NR2 (A–D) and NR3 (A–B) subunits.¹³ Since NR2B subunits have neocortical and hippocampal expression, this may explain the early cortical dysfunction of anti-NMDAR encephalitis. Widespread expression

of NR1 subunits (neurons, oligodendrocytes, astrocytes^{14,15}) could explain the spectrum of manifestations, but fails to explain the temporal pattern previously described. Myelin basic protein autoantibodies were identified in a patient with anti-NMDAR encephalitis who later developed transverse myelitis, optic neuritis and white matter lesions.⁷ Evidence of unmatched CSF oligoclonal bands in a later stage of anti-NMDAR encephalitis suggests the possibility of spreading of immunological response to other epitopes, leading to extra-cortical manifestations.⁶ An important limitation of the current report consists of the low specificity of anti-NMDAR-NR2B technique developed by Takahashi and collaborators, and paired analysis of serum and CSF from the same patients using both techniques could further clarify this point.

ACKNOWLEDGMENTS

We would like to thank Professor Yukitoshi Takahashi at the Shizuoka Institute of Epilepsy and Neurological Disorders, Professor Angela Vincent and Dr Isabel Leite at the University of Oxford. The authors have no conflicts of interests.

REFERENCES

1. Graus F, Saiz A, Dalmau J. Antibodies and neuronal autoimmune disorders of the CNS. *J. Neurol.* 2010; 257: 509–517.
2. Vitaliani R, Mason W, Ances B, Zwerdling T, Jiang Z, Dalmau J. Paraneoplastic encephalitis, psychiatric symptoms, and hypoventilation in ovarian teratoma. *Ann. Neurol.* 2005; 58: 594–604.
3. Ances BM, Vitaliani R, Dalmau J *et al.* Treatment-responsive limbic encephalitis identified by neuropil antibodies: MRI and PET correlates. *Brain* 2005; 128: 1764–1777.
4. Dalmau J, Tüzün E, Lynch DR *et al.* Paraneoplastic N-methyl-D-aspartate receptor encephalitis associated with ovarian teratoma. *Ann. Neurol.* 2007; 61: 25–36.
5. Dalmau J, Gleichman AJ, Lynch DR *et al.* Anti-NMDA-receptor encephalitis: case series and analysis of the effects of antibodies. *Lancet Neurol.* 2008; 7: 1091–1098.
6. Irani SR, Bera K, Waters P *et al.* N-methyl-D-aspartate antibody encephalitis: temporal progression of clinical and paraclinical observations in a predominantly non-paraneoplastic disorder of both sexes. *Brain* 2010; 133: 1655–1667.
7. Kruer MC, Koch TK, Bourdette DN *et al.* NMDA receptor encephalitis mimicking seronegative neuromyelitis optica. *Neurology* 2010; 74: 1473–1475.

8. Takahashi Y, Sakaguchi N, Kondo N *et al.* Epitope analysis of auto-antibodies against GluR ϵ 2 in patients with chronic progressive epilepsy partialis continua of childhood. *Epilepsia* 2002; 43 (Suppl. 9): 74.
9. Hughes EG, Peng X, Gleichman AJ *et al.* Cellular and synaptic mechanisms of anti-NMDA receptor encephalitis. *J. Neurosci.* 2010; 30: 5866–5875.
10. Takahashi Y. Epitope of autoantibodies to N-methyl-N-aspartate receptor heteromers in paraneoplastic limbic encephalitis. *Ann. Neurol.* 2008; 64: 110–111.
11. Takahashi Y, Mori H, Fujiwara T *et al.* Autoantibodies and cell-mediated autoimmunity to NMDA-type GluR ϵ 2 in patients with Rasmussen's encephalitis and chronic progressive epilepsy partialis continua. *Epilepsia* 2005; 46 (Suppl. 5): 152–158.
12. Takahashi Y, Mori H, Kondo N *et al.* Autoantibodies to NMDA receptor in patients with chronic forms of epilepsy partialis continua. *Neurology* 2003; 61: 891–896.
13. Cull-Candy S, Brickley S, Farrant M. NMDA receptor subunits: diversity, development and disease. *Curr. Opin. Neurobiol.* 2001; 11: 327–335.
14. Salter MG, Fern R. NMDA receptors are expressed in developing oligodendrocytes processes and mediate injury. *Nature* 2005; 438: 1167–1171.
15. Lalo U, Pankratov Y, Kirchhoff F, North RA, Verkhrastky A. NMDA receptors mediate neuron-to-glia signaling in mouse cortical astrocytes. *J. Neurosci.* 2006; 26: 2673–2683.