

## The Effects of Progesterone Administration in Mice During Pregnancy on Ovarian Development and Anogenital Distance of the Offspring

Najat A. Mohammad<sup>1</sup>, Mohammad O. Selman<sup>1</sup>, Nahla Al-Bakri<sup>2</sup>, Enas I. Matloupe<sup>3</sup>,  
Imad M. Al-Ani<sup>4</sup>, Ghasak Ghazi Faisal<sup>5\*</sup>, Azhar M. Suhail<sup>6</sup>

1. Department of Applied Embryology, High Institute for Infertility Diagnosis and Treatment, Al-Nahrain University, Iraq.
2. Department of Biology, College of Education for Pure Science (Ibn Al-Haitham), University of Baghdad, Iraq.
3. Department of Family Medicine, Al-Yarmouk Teaching Hospital, Ministry of Health, Baghdad, Iraq.
4. Department of Dentistry, Al-Hikmah University College, Al-Yarmouk, Baghdad, Iraq.
5. Department of Fundamental Dental and Medical Science, Kulliyah of Dentistry, International Islamic University Malaysia, Kuantan, Pahang, Malaysia.
6. Alkarkh Health Directorate Baghdad, Saydah, Baghdad, Iraq.

### Abstract

Progesterone is highly used in pregnant women as therapeutic agent to maintain and support pregnancy. To explore the effects of progesterone usage all over gestation till 7 days postnatally on mice offspring ovaries development and anogenital distance. Ten pregnant mice were equally divide into control group that was injected with sesame oil which is used as a solvent for progesterone and treated group that is daily intraperitoneally injected with progesterone (dissolved in sesame oil 1:10) at dose 10.2mg/kg (the equivalent human dose) all through gestation till 7 days postnatal then sacrificed and measuring the anogenital distance (the distance between anus and genital papilla). Histological slides were prepared, and Diameters of the ovary, primary oocyte and primordial follicles were measured and histopathological changes analysis was done. Progesterone administration cause significant increment ( $p > 0.05$ ) in anogenital distance, significant decrement in primary oocyte diameter and primordial follicle diameter, with no significant difference in the ovary diameter. Histopathological changes were seen as hemorrhage, detachment of follicular cells from basement membrane with irregular arrangement and thickening or death of follicular cells, pyknosis of primary oocytes and vacuolation. Stromal cells degeneration. The current study revealed that progesterone injection of mice with equivalent human dose during pregnancy is embryotoxic and teratogenic, may alter the female reproductive performance with virilizing the female genitalia. The benefit of progesterone as a therapies need to be proven before recommended as supportive treatment during pregnancy.

**Experimental article (J Int Dent Med Res 2019; 12(4): 1665-1670)**

**Keywords:** Progesterone, Ovaries, Mice offspring, Anogenital distance, Virilization.

**Received date:** 13 January 2019

**Accept date:** 20 April 2019

### Introduction

Implantation occurs as a result of effective interaction between blastocyst and endometrium.<sup>1</sup> Progesterone converts the endometrium to secretory phase to prepare the uterus for implantation. Progesterone cause maternal immune decrement as a response to allow for acceptance of pregnancy<sup>2</sup> and reduce the uterine smooth muscle contractility.<sup>3</sup> Progesterone

supplement used as therapeutic agent<sup>4</sup> during pregnancy to maintain pregnancy and prevent recurrent pregnancy loss<sup>5</sup> also to improve pregnancy rates in human.<sup>6</sup> Progesterone supplement is restricted to women with a previous spontaneous preterm birth.<sup>7</sup> Maternal exposure to progesterone during gestation lead to many effects on the developing fetus and embryo which must be concern in human therapy include cardiovascular malformations, kidney, limbs anus and altered genitalia of female virilization) and increased incidence of reproductive abnormalities in males as hypospadias (urethral opening on the penis) and cryptorchidism (the testis failed to descend into scrotum<sup>8</sup> exposure to synthetic estrogen cause genital tract abnormalities.<sup>9</sup>

#### \*Corresponding author:

Ghasak Ghazi Faisal

Department of Fundamental Dental and Medical Science,  
Kulliyah of Dentistry, International Islamic University Malaysia,  
Kuantan, Pahang, Malaysia.

E-mail: drghassak@yahoo.com

## Methods

### Animals

Ten female mice aged (8-10) weeks, and of 25-28 gram weight were selected, they housed in a plastic cages, with wood shavings floor, mice were placed in room with acceptable ventilation, the temperature about  $21-28 \pm 4^\circ\text{C}$  and 40%-60% humidity with 12 hours' light-dark cycle, vaginal smears were performed to determine the estrus phase, mice with estrus were mated with males to induce pregnancy. Mating indicated by a vaginal plug or a smear with positive sperm presence in the next morning which considered as first day of gestation.<sup>10</sup>

### Experimental design

Ten pregnant mice equally divide into two groups; the control group: daily intraperitoneally injected with sesame oil that is used as a solvent for progesterone, from the first day of gestation till 7 days postnatal. The treated group that is injected daily intraperitoneally with progesterone (dissolved in sesame oil 1:10) at dose 10.2 mg/kg (the equivalent human dose) first day of gestation till day7 postnatal. The offspring were sacrificed at day 7 postnatally.

### Measurement of anogenital distance

anogenital distance usually using as a measure for the response to virilization of female fetuses from pregnancies treated with progesterone, this was done by using a ruler and a dissecting microscope.

### Morphometric techniques

Histological processing for ovaries was made, staining by Harris-Hematoxylin Eosin (H&E) stain. Morphometric image analysis was done by using the image J program (Java-based image processing program which developed at the national institutes of health). The program was used to measure the lengths and diameters by using the straight tool.<sup>13</sup>

### Statistical analysis

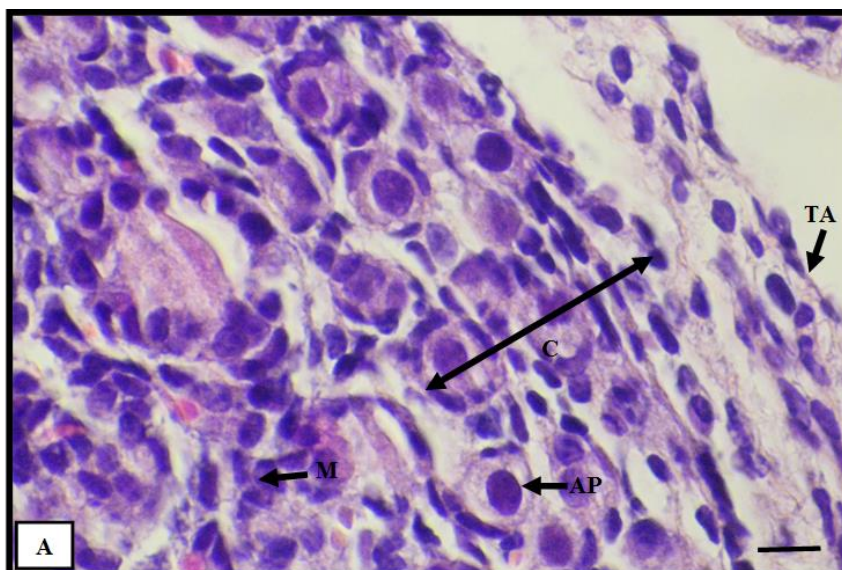
The IBM Corp. SPSS Statistics for Windows, Version 23. was used to analyze the data. All data in this study are presented as mean  $\pm$  SEM. Data were analysed by Mann-Whitney U test, the value of  $p < 0.05$  was considered as statistically significant.

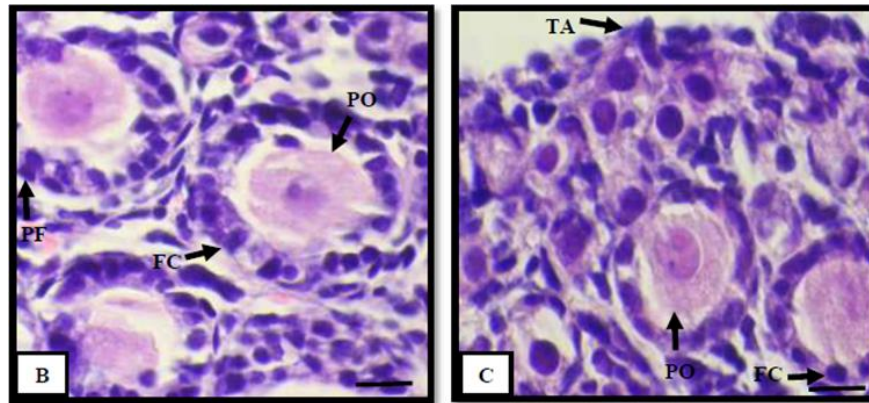
## Results

### Histological examination

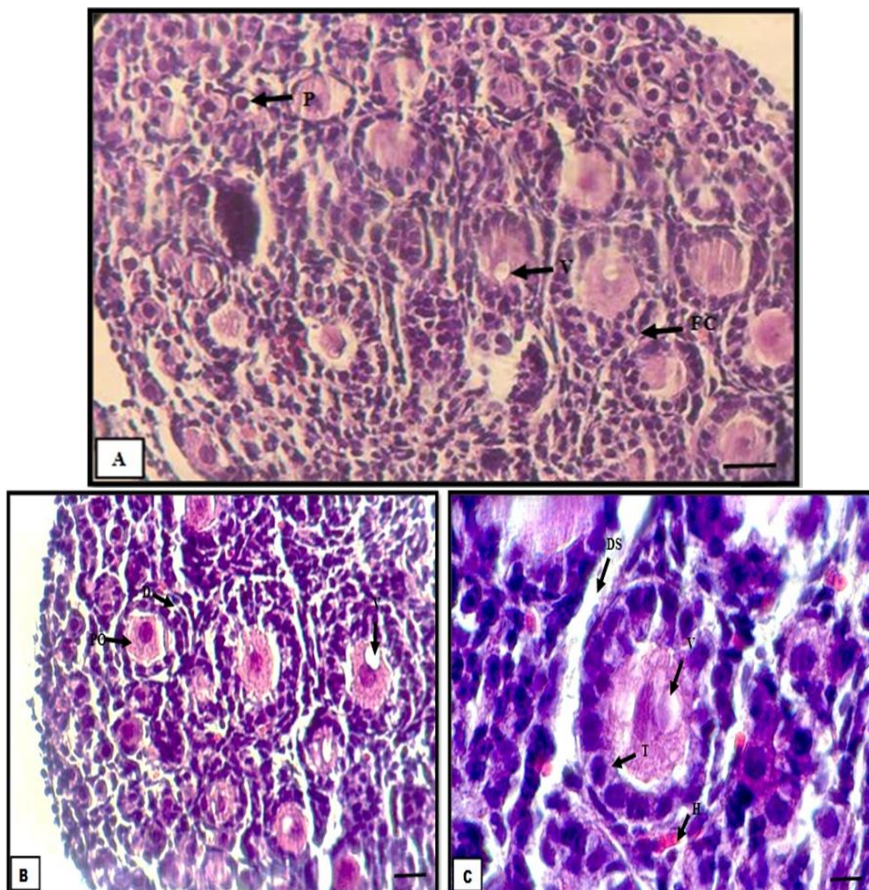
Histologically, the ovaries from the control group were shown to be covered by germinal epithelium overlying the tunica albuginea (dense connective tissue) below the tunica albuginea is the cortex that contains the primary oocyte surrounded regularly by single layer of follicular cells (squamous to columnar epithelium), and medulla that consist of connective tissue and blood vessels. (Figure 1: A, B, C).

While the treated group showed irregular arrangement of follicular cells ,also thickening or death of follicular cells layer, pyknosis of primary oocytes, vacuolation, stromal cells degeneration and hemorrhage (Figure 2:A,B,C)(Figure 3)

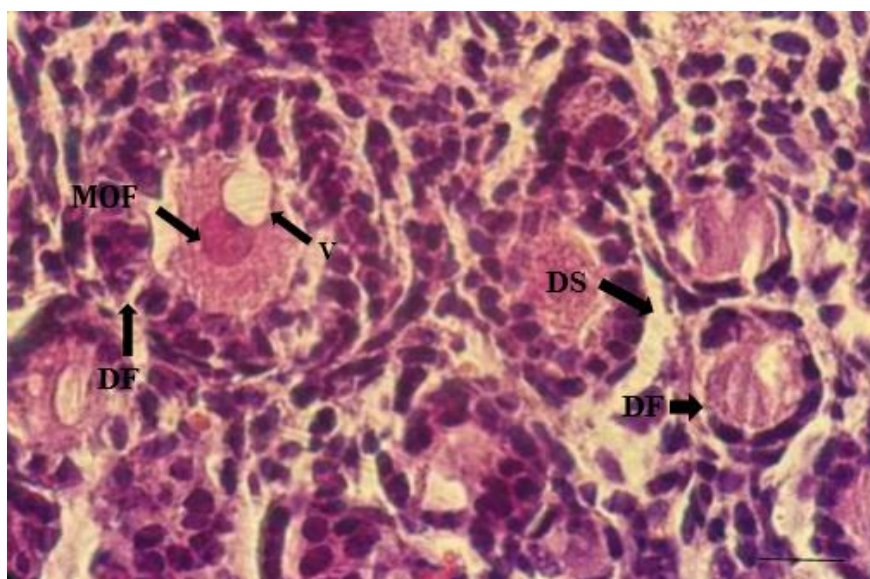




**Figure 1.** Cross sections through ovary at day seven postnatal of control group showing tunica albuginea (TA), cortex (C), Medulla (M), death cells (normal apoptosis) (AP), primordial follicle (PF), primary oocyte (PO), follicular cell (FC), (H&E). A, B, C: 40X, Scale bar: 40  $\mu$ m.



**Figure 2.** Cross sections through mice ovary at day seven postnatal of treated group showing follicular cell (FC), pyknotic primary oocyte (P), degeneration of stromal cells (DS) and hemorrhage (H), vacuolation (V) (H&E). A: 20X, Scale bar: 80  $\mu$ m; B, C: 100X, Scale bar: 10  $\mu$ m.



**Figure 3.** Cross sections through mice ovary at day seven postnatal of treated group showing multiple oocyte follicle (MOF) vacuolation (V), destruction of follicular cell (DF), destruction of stromal cells (DS), (H&E), 40X, Scale bar: 40  $\mu$ m.

**Statistical analysis**

Interestingly, a significant increasing ( $p < 0.05$ ) has been observed in anogenital distance after the treatment; the mean was (1.068  $\pm$  0.085) mm in control group and was (2.076  $\pm$  0.112) mm in treated group (Table 1).

On the contrary, the diameter of primordial follicles significantly decreased ( $p < 0.05$ ) after the treatment, and the mean was (7.568  $\pm$  0.382)  $\mu$ m in control group while it was (5.284  $\pm$  0.388)  $\mu$ m in treated group (Table 1).

Parameters	Mean $\pm$ S.E	
	Control group	Treated group
Anogenital distance (mm)	1.068 $\pm$ 0.085	2.076 $\pm$ 0.112*
Diameter of primordial follicles ( $\mu$ m)	7.568 $\pm$ 0.382	5.284 $\pm$ 0.388*
Diameter of primary oocyte	1.64 $\pm$ 0.083	0.679 $\pm$ 0.027*
Diameter of ovary( $\mu$ m)	92.115 $\pm$ 5.768	96.859 $\pm$ 5.663

\* Significant differences between control and treated groups

**Table 1.** Statistical analysis to the means and standard error of females mice embryo of control and treated groups at 7day postnatally.

Interestingly, the statistical analysis of the observed results revealed a significant decrease ( $p < 0.05$ ) in the mean of the diameter of primary oocyte in treated group in comparison to control group. The mean of diameter of primary oocyte

was (1.64  $\pm$  0.083)  $\mu$ m in control and was (0.679  $\pm$  0.027)  $\mu$ m in treated group (Table1).

In addition, the present study found there is no significant difference was seen in the diameter of ovary at 7 postnatal days; the means were (92.115  $\pm$  5.768)  $\mu$ m and (96.859  $\pm$  5.663)  $\mu$ m in control and treated groups respectively (Table1).

**Discussion**

Progesterone consider as substrate for the thecal cells, which under the stimulation of LH hormone, convert progesterone into androgens and attacks the hippocampus resulting in damage the pyramidal cells, which leading to neuronal cell apoptosis or degeneration and hypothalamic-pituitary axis dysfunction that cause FSH level decrease, that leading to decrease the number of FSH receptors on the granulose cells.<sup>14</sup> Progesterone supplement occupy the progesterone receptor site and inhibit the binding of endogenous progesterone to receptor, exogenous progesterone (synthetic progestin) do not activate P53 gene and preclude the production of the body own progesterone which cause progesterone deficiency that suppress eggs maturation by preventing the release of LH and FSH hormones.<sup>15</sup> The current study results showed a significant decrement in primary oocyte diameter and primordial follicle diameters may be due to role of progesterone on signal transduction

pathway,<sup>16</sup> and occurrence of multiple oocytes follicle (MOF) during primordial follicle formation<sup>17</sup> MOFs are postulated to be oocytes cluster that did not separate leading to many oocytes more than one enclosed in a single follicle.<sup>18</sup>

It also indicates reduction in oocyte apoptosis and primordial follicle assembly in treated group when compared with control group<sup>19</sup> that agrees with previous studies which indicate the oocytes apoptosis in the oocyte nests is required for assembly of follicle with involving of tumor necrosis factor-alpha (TNF $\alpha$ ) that promote oocyte apoptosis allowing the assembly of primordial follicle Progesterone suppressed the TNF $\alpha$  expression.<sup>20</sup> The present study results showed no significant difference in diameter of ovary, that agree with previous study finding that hint at mouse fetus depend on the of maternal steroid and cholesterol transfer during pregnancy for normal development.<sup>21</sup> The results of present study shown significant difference in the postnatally anogenital distance (measurement of anogenital distance reflect the virilizing effect of progesterone on offspring when maternal drug was given during pregnancy, previous hypothesis suggest that progesterone feedback inhibit the steroid synthesis enzyme (3  $\beta$  hydroxysteroid hydrogenase) lead to female virilization, this enzyme required for steroid synthesis from cholesterol at early steps. Lack of 3  $\beta$  hydroxysteroid hydrogenase activity in the adrenal of the female fetus lead to accumulation of dehydroepiandrosterone (DHEA) which lead to female genital virilization. A peak in activity of this enzyme in the adrenals of the female fetus at the time of urethrovaginal forming. Hypospadias in human males due to defect in 3  $\beta$  hydroxysteroid hydrogenase activity which reduced DHEA metabolism estimated human clinical dose. Testosterone action on the developing male urogenital system requires activity of this enzyme,<sup>22</sup> which is highly expressed in the testes of the mice at the beginning on day 15 perinatal. The associated accumulation of DHEA due to lack of 3 $\beta$  hydroxysteroid hydrogenase. Analysis of human reports and comparison with experimental animals results shows that the fetal effects of progesterone not analogous to effects of experimental animals fetus, many studies showed that progesterone exposure during developing of human female genital tract was not teratogenic.<sup>23</sup> Other studies that performed on laboratory animals found association between progesterone

administration during pregnancy and genital malformation.<sup>24</sup> that supported previous finding of other study which indicate that progesterone was inhibit 5 a-reductase (enzyme in steroid hormone metabolism), inhibition of 5a-reductase lead to decreased conversion of testosterone to the DHT(Dihydrotestosterone), so the testosterone increased result in masculinization of external and internal genitalia in female fetus also caused decreased in male anogenital distance and deviate the sex ratio toward female as well as hypospadias in human male fetus.<sup>25</sup> Dihydrotestosterone is known to be the local mediator of penile development. Another hypothesis suggest that progesterone inhibit 5 a-reductase lead to decrement of testosterone conversion into Dihydrotestosterone resulting in masculinization of internal and external human genitalia of female.<sup>26</sup> Histological section of treated group showed congested blood vessels and hemorrhage that support previous study point out to progesterone inhibitory effect on prostaglandins synthesis<sup>27</sup> which involved in regulation of blood flow leading to dilatation of blood vessels increasing blood flow. The slides of treated ovaries sections examination showed vacuolation which is a mechanism of defense to prevent interfering with cell activities by collecting the injurious substance<sup>28</sup> and pyknosis of primary oocyte that supported by previous study propose that internucleosomal rotational angle freedom that allows the basic histone tail of neighboring nucleosomes the nucleofilament to sharing resulting in pyknosis,<sup>29</sup> also showed follicular cell death and stromal cells destruction, this correspond the result of previous study that indicate cell death due to cytoskeleton loss and destruction of basement membrane.<sup>30</sup>

## Conclusion

The current study revealed that progesterone injection of mice with equivalent human dose during pregnancy is embryotoxic and teratogenic and may alter the female reproductive performance with virilizing the female genitalia.

## Acknowledgements

The authors would like to thank all the staff from the different institutes for their help in conducting this research and to the International

Islamic University Malaysia for participating in funding this research under Research Initiative Grant Scheme number:(P RIGS18-030-003).

## References

1. Mc GTA, Veterinary Embryology Black well Publishing; Singapore 2010;80.
2. Prabhu DM, Bonney E, Caron K, Dey S, Erlebacher A, Fazleabas, S. Fisher, T. Golos, M. Matzuk, J.M. McCune, G. Mor A, Schulz L, Soares M, Spencer T, Strominger J, Way SS, Yoshinaga K. Immune mechanisms at the maternal-fetal interface: Perspectives and challenges. *Nat Immunol* 2015;16:328–34.
3. Van DLM, Bukingham K, Farquhar C. Luteal phase support for assisted reproduction cycles. *Cochrane Database Syst Rev* 2011;5(10):134-45.
4. Kuhl H. Pharmacology of estrogens and progesterones: influence of different routes of administration. *Climacteric*; 8 supply 2005;1:3-63.
5. Lee HJ, Park TC, Kim JH, Norwitz E, Lee B. The influence of oral dydrogesterone and vaginal progesterone on threatened abortion: a systematic review and meta-analysis. *Bio Med Res Int* 2017;2017:361-72.
6. Coomarasamy A, Williams H, Truchanowicz E, Seed PT, Small R, Quenby S, Gupta P, Dawood F, Koot YE, Bender AR, Bloemenkamp KW. A randomized trial of progesterone in women with recurrent miscarriages. *New Engl J Med* 2015;26:373(22):2141-8.
7. American College of Obstetricians and Gynecologists, Committee on Obstetric Practice. Use of progesterone to reduce preterm birth. ACOG committee opinion. 2008;291:1115-6.
8. FH, Burdrof A, Deddens JA. Maternal and paternal Risk Pierik factor for cryptorchidism and hypospadias: A Case-Control study in newborn boys, *Environ Health Perspect*. 2004;112(15):1570-6.
9. Insaf JM, Mohammad OS, Wameedh RAS. Chronology of estrogen receptor expression in testes of mouse embryos. *Turk J Med Sci* 2015;45:526-33.
10. Suckow MA, Danneman P, Brayton C. The Laboratory Mouse, second Edition. CRC Press 2012;220-235.
11. Reagan SS, Faseb J, Faseb J, Nihal M, Ahmed N. Dose translation from animal to human studies revisited. 2007;22:659-61.
12. Nair AB, Jacob S. A simple guide for dose conversion between animal and Human. *J Basic Clin Pharm* 2016;7:27-31.
13. Spandorfer S, Rosenwaks Z. The impact of maternal age and ovarian age on implantation efficacy. In: Carson DD, ed. *Embryo implantation: molecular, cellular and clinical aspects*. New York: Springer-Verlag 1999;12-9.
14. Hiory S, Takeyuki T, Kazumi S. Glucocorticoid Generates ROS to induce oxidative injury in the hippocampus, Leading to impairment of cognitive function of rats. *Cli Bio Nutr J* 2010;47(3):224-32.
15. Sorlie DG. *Medical biostatic and epidemiology; examination and broad review* 1st edition Connecticut. 1995;47-88.
16. Zhang Z, Laping J. Gasser Mediators of estradiol stimulated mitosis in the rat uterine luminal epithelium. *Endocrin J* 1998;139:961-6.
17. Ying CWN, Jefferson RR. Newbold Elizabeth Padilla-Banks Melissa E. Pepling. Estradiol, Progesterone, and Genistein Inhibit Oocyte Nest Breakdown and Primordial Follicle Assembly in the Neonatal Mouse Ovary in Vitro and in Vivo. *Endocrin* 2007;148(8):3580–90.
18. Ying CWN, Jefferson RR. Newbold Elizabeth Padilla-Banks Melissa E. Pepling. Estradiol, Progesterone, and Genistein Inhibit Oocyte Nest Breakdown and Primordial Follicle Assembly in the Neonatal Mouse Ovary in Vitro and in Vivo. *Endocrin* 2007;148(8):3580–90.
19. Kezele P, Skinner MK. Regulation of ovarian primordial follicle assembly and development by estrogen and progesterone: endocrine model of follicle assembly. *Endocrin* 2003;144(8):3329-37.
20. Morrison LJ, Marcinkiewicz JL. Tumor necrosis factor  $\alpha$  enhances oocyte/follicle apoptosis in the neonatal rat ovary. *Biol Reprod* 2002;66(2):450-7.
21. Raunig JM. Assisted reproduction Technology alters steroid delivery to the mouse fetus during pregnancy. *J Steroid Biochem Mol* 2011;126(1-2):26-34.
22. Lutfallah C, Wang W, Mason JI, Chang YT, Haider A, Rich B, Castro-Magana M, Copeland KC, David R, Pang S. Newly proposed hormonal criteria via genotypic proof for type II 3 $\beta$ -hydroxysteroid dehydrogenase deficiency. *J Clin Endocrinol Metab* 2002;87(6):2611-22.
23. Cunha GR, Taguchi O, Lawrence WD. Absence of teratogenic effect of progesterone on developing genital tract of the human female fetus. *Humpathol*; 1988; 19(7):777-83.
24. Raman-Wilms L, Tseng AL, Wighardt S. Fetal genital effects of first-trimester sex hormone exposure: a meta-analysis. *Obstet Gynecol* 1995;85(1):141-9.
25. Thiele S, Hoppe U, Paul-Martin. Isoenzyme type 1 of 5 $\alpha$ -reductase is abundantly transcribed in normal human genital skin fibroblasts and may play an important role in masculinization of 5 $\alpha$ -reductase type 2 deficient males. *Eur J Endocrinol* 2005;152(6):875-80.
26. Silver RI, Rodriguez R, Chang TS, Gearhart JP. In vitro fertilization is associated with an increased risk of hypospadias. *J Urol* 1999;161:1954–7.
27. Naser SE, Elgendy MS, Sayed SS, Aly AM. Histological study on the effect of vitamin C on ischemia-reperfusion injury in the adult ovary. *Egypt J* 2014;37:562-70.
28. Cheville NF. *Ultrastructural pathology: the comparative cellular basis of disease* 2nd ed. USA: Wiley-Blackwell 2009;5-18.
29. Burgoyne LA. The Mechanisms of pyknosis: Hypercondensation and Death. *Exp Cell Res* 1999;248:214-22.
30. Vandewater B, Jaspers JJ, Masdam DH, Mulder GJ, Nagel KJ. In vivo and in vitro detachment of proximal tubular cell and F-actin damage: consequences for renal function. *Am J Physiol* 1994;5(2):888-99.