

POTENTIAL ORAL WOUND HEALING OF TOPICAL APPLICATION OF DENTAL GEL PREPARED FROM *BACCAUREA ANGULATA* FRUIT IN DIABETIC RATS

**Project Sponsor : International Islamic University Malaysia
(RIGS15-047-0047)**

Omar Abdul Jabbar Abdul Qader¹, Susi Sukmasari², Ahmad Faisal Ismail²,
Mohammad Nasrin Abdul Rahman³, Abd Almonem Doolaanea^{3,4,*}

¹*Department of Oral Medicine and Oral Pathology, Kulliyah of Dentistry, International Islamic University Malaysia, Bandar Indera Mahkota , 25200 Kuantan, Pahang, Malaysia*

²*Department of Paediatric Dentistry, Kulliyah of Dentistry, International Islamic University Malaysia, Bandar Indera Mahkota , 25200 Kuantan, Pahang, Malaysia*

³*Advanced Drug Delivery Lab, Department of Pharmaceutical Technology, Kulliyah of Pharmacy International Islamic University Malaysia, Bandar Indera Mahkota , 25200 Kuantan, Pahang, Malaysia*

⁴*IKOP Sdn Bhd, Kulliyah of Pharmacy, International Islamic University Malaysia*

**Corresponding: Abdul Almonem Doolaanea*

Email: abdalmonemdoolaanea@gmail.com H/P: +0136238628

POTENTIAL ORAL WOUND HEALING OF TOPICAL APPLICATION OF DENTAL GEL PREPARED FROM *BACCAUREA ANGULATA* FRUIT IN DIABETIC RATS

ABSTRACT

Objective: This study investigates the effect of *Baccaurea angulata* fruit extract towards wound healing activity at tooth extractions sites.

Significance: High antioxidant content in underutilised *Baccaurea angulata* were expected to open up new possibilities for tooth extraction procedure among diabetic patients.

Methods: Sprague dawley rats were divided into 6 groups, and 1 their left mandibular first molar tooth were extracted. The alveolar socket were treated accordingly where group 1, 2, 3, 4, and 5 were diabetic rats (induced using Streptozotocin) applied with plain gel, alveolex, 3%, 5%, and 10% *Baccaurea angulata* extract respectively. Group 6 were non diabetic rats applied with plain gel. On day 4, 7 and 18, rats were euthanized, and the tissue samples were processed for histomorphological analysis.

Results: It was found that *Baccaurea angulata* does significantly promotes tooth extraction wound healing in diabetic rats comparable to diabetic group treated with alveolex and non-diabetic rats at early phase of the wound. However the positive effect were not obvious at day 7, while at day 18, groups treated with *Baccaurea angulata* treated group had higher mean scores in most categories although may not statistically significant different. BADG concentration of 4% was found to give the best effects on wound healing.

Conclusion: To a certain extent, *Baccaurea angulata* extract does promotes tooth extraction wound healing in diabetic rats.

Keywords: *Baccaurea angulata*, tooth extraction, wound healing, diabetes, extracts, dental gel

INTRODUCTION

Human is occupied with the capabilities of natural wound healing upon having physical, chemical, microbial, thermal or immunological insults to our tissues trauma. However, this capability might be disrupted by improper wound healing due to diabetes mellitus. Wound is basically known as disruption of the cellular and anatomic continuity of tissues [1]. One is considered having a wound if he/she having a physical injury that results in breaking or an opening of the mucosa or skin. Wounds can sometimes be mild, or can be fatal. Diabetes mellitus patients are normally having disrupted system of integrated cellular and biochemical events. Diabetes was expected to change the integrity of immune response, thus will reduce the body resistance to infections. The infections itself will cause further delays in wound healing, thus worsening the condition [2, 3].

Tooth extraction is one of the dental procedures that will lead to wound. Wound healing is a phase that plays important part in recovering the wound caused by tooth extraction. However, not everyone is suitable to undergo tooth extraction procedures because extra precautions need to be taken for diabetes mellitus patients since their wound healing system might be impaired. Wound infection at the tooth extraction site is dangerous because the oral mucosa, which is the barrier separating the external environment and the internal body, might be exposed. Therefore, in this situation the internal environment is not protected, and is prone to more and more infections due to unhealed wound. This problem is mostly faced by diabetes mellitus patients. Therefore, we need fast and effective medicines that can support the healing process among diabetes mellitus patients who need to undergo tooth extraction due to dental reasons.

Diabetes mellitus problem is understood as impaired body function to maintain the blood glucose level and defects in insulin action, or insulin secretion [4]. However, it is not necessarily that diabetes mellitus patients will suffer obviously from improper wound healing since the predisposition to the developments of complications of diabetes mellitus is vary among patients [5]. Oral healthcare is one of the major concerns among diabetic patients in which the process of tooth extraction is very risky since it may lead to wound infections easily. Oral environment is full of bacterial, so there are many possibilities that infection can override and spoil the wound healing process after the tooth extraction procedure. Therefore, it is very important to speed up the wound healing process especially among patients with diabetes mellitus to prevent any

unwanted infections. Since diabetic patient is prone to wound infections, tooth extractions were not usually recommended. However in certain cases, there are situations that tooth extraction need to be proceed to prevent further pain, such as the removal of wisdom tooth which overlaps with the gums/ teeth.

Healing process involves 4 major phases, overlaps between each other in between the phases change. They are haemostasis, inflammation, proliferation phase, and remodelling. Each and every phase was inter-related and important for a complete wound healing and scar remodelling. Wound at the tooth extraction sites undergo the same pathways, with additional phases after the scar remodelling, which is bone remodelling in the alveolar socket [6]. Alveolar socket wound healing process involves soft tissue and bone remodelling, and it starts right after tooth extraction. The healing process will be affected by various factors such as systemic metabolite imbalances, local factors, diet supplementations, radiation, or others [7].

This research is significant in producing a new halal dental gel as medication that can help to accelerate the wound healing process. The active ingredient that will be used in this research contains high antioxidant and anti-inflammatory properties and most importantly, it is from local sources which is *Baccaurea angulata* (known as Belimbing Dayak as local Malaysian name). *Baccaurea angulata* is the fruit that has been used by ancestors to treat wound healing. However, there were no commercial product in the market using this extracts as medication, and no studies to prove the wound healing activity of this fruit. Positive results that might be found from this research will give a big impact in helping diabetes mellitus patient not to suffer from prolong wound pain f after having a certain operations/ procedures including dental's tooth extraction. The relevance is even more since the prevalence of diabetes mellitus patients among Malaysian is high, which is about 2.8 million individuals equivalent to 20.8% of total Malaysian (30 millions) [8] . This study can contribute to the development of halal topical wound healing products that is cheaper compared to other imported commercial products, thus contributing to more efficient health spending in government system. There were numerous study on wound healing after tooth extraction investigated by previous researcher [7, 9, 10], but none of them investigated the effect of *Baccaurea angulata* extract on tooth extraction wound healing on diabetic rats model.

OBJECTIVE

To investigate the potential of dental gels containing *Baccaurea angulata* extracts in promoting wound healing of tooth extraction in diabetic rats.

MATERIALS AND METHODS

Materials

***Baccaurea angulata* extraction**

Whole fruit of *Baccaurea angulata* (BA) were used for extraction using method done by Ahmed et al, 2015 [11]. *Baccaurea angulata* were couriered by local farmers in Bau, Sarawak directly to Kulliyyah of Allied Health Science International Islamic University Malaysia Kuantan campus. The fruits were directly rinsed under running tap water followed by oven drying at 50 °C. The dried fruit were ground until powder form and kept in amber bottle in -20°C to preserve its freshness. A total of 62.5 gram of the powders were suspended into 700 mL of ethanol for 24 hours, wrapped in aluminium foil, and stirred using magnetic stirrer. This was followed by centrifugation at 9000 rpm at 4 °C for 15 mins. The supernatants were collected using vacuum suction and filter paper Whatman® Grade 1, while the precipitates were re-extracted using another 700ml ethanol for another round of extraction. This was followed by centrifugation and filtration once again to collect the supernatants. The supernatants were evaporated until dryness using Ika RV8 rotary evaporator (Wilmington, USA) rotary evaporator.

***Baccaurea angulata* dental gel**

Baccaurea angulata dental gel (BADG) was prepared using carbopol 940 as the main gelling polymers with the concentration of 4 wt%, and ethanol extract of *Baccaurea angulata* fruit with concentration of 3, 5, and 10 wt% [12]. Propylene glycol (5 wt%) as solubilisers, methyl paraben (0.1 wt%) and propyl paraben (0.03 wt%) were incorporated as excipients of the gel [13]. Triethanolamine were added as alkalizing agent to neutralize carbopol to the intended pH of 7 which is the best gelling state for carbopol [14].

Rats diabetes induction

The experimental activity was approved by Integrated Centre for Research Animal, Care and Use (ICRACU) International Islamic University Malaysia (IIUM/ IACUC Approval / 2016 / (10) (61)). The induction of diabetes was made according to protocol

prepared by Furman, 2015 [15] with slight modifications. Sprague Dawley rats weighted approximately 200g each were induced with diabetes type 1 using Streptozotocin (STZ) purchased from Nacalai Tasque (Kyoto, Japan) at the dose of 70 mg/kg [15]. A total of 54 rats were purchased from local farm in Seri Kembangan, Selangor Malaysia and divided into 6 groups, 3 sub-group of day 4, day 7 and day 18, with 3 rats in each sub-group [16]. Rats were caged 3 rats per group, with 12 hours light-dark cycle and room temperature of 22 °C ± 1 °C. Prior to STZ injection, rats were fasted for 8 hours with access to water for drinking. The STZ was diluted with cold 50 mM sodium citrate buffer (pH 4.5) [17] to a final concentration of 32.5 mg/ml for each rats since it have to be directly injected into the rats intraperitoneally (i.p.) maximum within 5 minutes of being dissolved. A 26-G needle with a 1 mL syringe was used.

Confirmation of diabetes

On experimental day 10 after the first STZ injection, the blood glucose of the rats was measured from the tail vein, using One Touch UltraEasy glucometer. Rats were fasted for 8 hours before glucose measurement with continuous water supply. They were considered successfully diabetic if the fasting blood sugar value is higher than 250 mg/dL [18]. Those that does not successfully diabetic on day 10, will be retested their fasting blood glucose on day 21 with the same method. Unsuccessful diabetes rats will be reinjected with STZ at the same dose, and the procedure of diabetes confirmation is repeated.

Tooth Extraction

Appropriate animal care is given according to the guidelines outlined from Malaysian Code of Practice for The care and Use of Animals for Scientific Purposes. Fifty four Sprague dawley rats were randomly divided into 6 groups where group 6 (G6) is non-diabetic rats treated with plain carbopol gel, group 1 (G1) is diabetic rats treated with plain carbopol gel, group 2 (G2) is diabetic rats with common commercial treatment, while group 3,4 and 5 (G3, G4, G5) are diabetic rats treated with *Baccaurea angulata extract* gel in different concentration (3%, 5% and 10% respectively) [19, 20]. Extraction of left mandibular first molar was performed under general anesthesia using ketamine (50mg/kg) and Xylazine (5mg/kg) [21, 22]. Rats eye were hydrated with normal saline in order to prevent corneal defect

due to anesthesia induced eye dehydration. Rats were given Ampicillin IM 50mg/kg dose as antibiotic prophylaxis prior to procedure to prevent infections during procedure [18]. After extraction of tooth, rats were provided with grounded rat chow in powder form in order to ease them eating, and not to worsen the wound due to rough food.

Sample collection

Rats were sacrificed according to their assigned sub-groups, which were on day 4, day 7 and day 18 for each of the 6 groups. Rats were sacrificed by overdosing ketamine and xylazine) at 4 times anesthetic dose, and the confirmation of euthanasia was performed by physical methods (decapitations) [23, 24]. Samples of the lower mandible (exact area of tooth extraction) were taken and fixed in 10% formalin pH 7 [25] for 72 hours [26]. Later, the samples were rinsed under running tap water for 24 hours [27]. Samples were decalcified using 8% hydrochloric acid for 48 hours [28, 29]. This was followed by tissue processing (dehydration process), and embedding into paraffin wax block. The blocks were cut into 5 μ m using microtome. The tissue slides were stained using hematoxylin and eosin staining using manual explained by Cardiff, 2015 [30, 31].

Wound healing Assessment

The wound healing stages were observed under CX21 Olympus microscope exactly on the point of alveolar socket of the first molar tooth. A histopathologist who was blinded to the grouping of the slides will analyze the stages of wound healing of the slides and score them accordingly [32, 33, 34]. Each of the histology slides will be analyzed in terms of polymorphonuclear leucocyte (PMNL), macrophage, blood vessels, fibroblast, collagen fibers, epithelization, and woven bone formation.

Table 1: Scoring of the histological wound healing analysis [18, 32, 34]

Score	0	1	2	3	4
PMNL	Absent	Mild (within surrounding tissue)	Mild (demarcation line and granulation tissue)	Moderate (demarcation line and granulation tissue)	Marked (demarcation line and granulation tissue)
Macrophage	Absent	Minimal (granulation tissue)	Mild (granulation tissue)	Moderate (Granulation tissue)	Marked (granulation tissue)
Neo-angiogenesis	Absent	Mild (subcutaneous tissue)	Mild (granulation tissue)	Moderate (granulation tissue)	Marked (granulation tissue)
Fibroblast	Absent	Mild (surrounding tissue)	Mild (granulation tissue)	Moderate (granulation tissue)	Marked (Granulation tissue)
Collagen	Absent	Minimal (granulation tissue)	Mild (granulation tissue)	Moderate (Granulation tissue)	Marked (granulation tissue)
Epithelization	Thickness of cut edges	Migration of cells (less than 50%)	Migration of cells (more than 50%)	Bridging the excision	keratinization
Woven Bone	Absent	Minimal	Mild	Moderate	Marked

STATISTICAL ANALYSIS

The data were analyzed with the application of ANOVA (one-way analysis of variance) followed by Tukey test of multiple comparison using Minitab 17. The results were expressed as mean \pm standard deviation. The significance of the differences between mean values of each data measured was determined based on p value, where P value < 0.05 is considered statistically significant.

RESULTS

All successfully diabetic rats were selected to be included in experimental group G1, G2, G3, G4, and G5, while does that does not successfully become diabetic, were reinjected as mentioned in method. Table 1 illustrates the wound healing score based on semi quantitative method. The graph was divided into day 4, day 7 and day 18. Each of

the day analysis, the scorings were evaluated based on (PMNL), macrophage, neovascularization, fibroblast, collagen fibers, and epithelization.

Day 4

PMNL score had shown that G1 had the highest mean score. Nevertheless, the value was not significantly different with G2, G3, G4, and G5. G6 had significantly lowest PMNL. In term of macrophage, all the groups were having comparable score, but not statistically significant different from each other. Regarding presence of fibroblast, G1 had significantly the least mean score value. In term of collagen fibers, G1 had shown significantly the lowest mean score, while all other groups (G2, G3, G4, G5, and G6) were not significantly different between them. This indicates collagen fibers proliferation of diabetic group with treatment of alveolex or BA was comparable to non-diabetic group. Again, G1 had shown significantly the lowest epithelization mean score while other groups were not significantly different from G6. Regarding the new bone formation in the alveolar socket, it was observed that there were minimal woven bone formations in all groups, and their mean score were not significantly different from each other.

Day 7

PMNL mean score on day 7 is not really consistent with the score for day 4, because it was observed that G2 had the highest mean score followed by G1 ($p > 0.05$) between G1 and G2). Generally, all other groups had lower mean PMNL score indicating the inflammation phase is going to end soon. There were no significant different in the value of macrophage for all groups. Nevertheless, G1 had shown the lowest mean score. The same thing goes to neovascularization, presence of fibroblast, collagen fibers formation and epithelization where G1 had the least mean score. Nevertheless, the mean score of neovascularization for G1 is not statistically different from G2, G3, G5, and G6. For presence of fibroblast, the mean score were not statistically significant different from G2, G3, and G6. For collagen fibers formation, all other groups were significantly higher than G1. For epithelization, G1 was not

statistically different from G2, G3, and G5. G4 and G6 was found to have the highest epithelization mean score. Lastly, formation of woven bone was comparable in score for all groups.

Day 18

G1 had the highest PMNL mean score, but not statistically different from G2 while G4 had the least mean value, but statistically not significant different from G2, G3, G5, and G6. In term of presence of macrophage, G6 was found to have the least macrophage mean value, the same with neovascularization. Nevertheless statistically G6's neovascularization is not significantly different from G1, G3, and G4. Regarding presence of fibroblast and collagen fibers, it was found that all groups had comparable score ($p > 0.05$) with G6 had the highest mean score. In term of epithelization, G3, G4, and G6 were significantly scored the highest mean score, while G1 had the least mean score, but statistically not significant different with G2 and G5. Last but not least, all the groups had comparable woven bone formation with statistically not significant different mean score between them.

DISCUSSION

Based on the results obtained above, detailed wound healing processes were investigated for each of the phase. For all 3 types of groupings (day 4, 7, and 18), it was found that G1 (negative control) had the least wound healing activity towards a certain extent. This is because the mean PMNL score was highest at all three days, lowest neovascularization mean score at day 4 and 7, lowest fibroblast mean score, lowest collagen fibers formation mean score, and lowest epithelization mean score for all three days. Nevertheless, their value may not be significantly different with some other groups in respective category comparisons. Non diabetic rats (G6) had shown faster wound healing process, where the mean score of each category was better compared to the diabetic rats (G1, G2, G3, G4, and G5). However, some of the values may not be significantly different with other groups as explained in the results. G2 was used as

positive control where the commercial alveolar dressing, alveolex, purchased from Biodinamica (Parana, Brasil) was used to treat tooth extraction wound healing of diabetic rats. Alveolex which contains 10% propolis, 5% iodoform, thickener and beeswax is generally used to enhance wound healing at the alveolar socket after tooth extraction [35]. Propolis was found to possess biological activity as antibacterial, antifungal, antioxidant and others [36, 37].

Based on table 1 (day 4), G6 generally had lower PMNL mean score because the inflammation phase is about to end. However, for other groups which comprises of diabetic rats, PMNL is still high due to delayed and prolong inflammation. Generally, all diabetic groups (G1, G2, G3, G4, and G5) had comparable PMNL score regardless of being treated with plain gel, alveolex, or BADG. The same thing goes to macrophage. This proves the delayed and prolonged inflammatory phase in diabetic model and neither alveolex nor BADG helped to suppress the inflammation significantly at day 4. Diabetic rats treated with alveolex (G2) or BADG (G3, G4, G5) generally had improved the wound healing by increasing the angiogenesis to be comparable to non-diabetic rats (G6). This had contributed to better fibroblast and collagen fibers formation in them compared to G1. In term of epithelization, it was shown that alveolex and BADG helped to speed up the extent of epithelization making them to be values of 1+ (migration of cells less than 50%), and comparable to G6. Regarding woven bone formation, all the groups had minimal bone formation regardless of being treated with plain gel, alveolex, BA or in non-diabetic group. This means at day 4, the treatment does not affect the formation of new bone from osteoblast. Between 3% BADG (G3), 5% BADG (G4) and 10% BADG (G5), there were no marked statistical different between each of them in all the scorings. So at day 4, there are no definite lines indicating the different effect of different BA concentration. Fig 1(a, d, g) and fig 2 (a, d, g) shows obvious demarcation lines and necrotic tissue in all groups.

Based on table 2 (day 7), the PMNL mean score for all groups decreased compared to data in table 1. It was expected because the inflammation phase is about to end, and continued by proliferation phase of wound healing. At this time, all the groups are having about the same and comparable PMNL mean score between alveolex and BADG treated group, and they were not clearly differentiated compared to G1 and G6. Again, the same thing goes to macrophage. Angiogenesis score of G1 had increased compared to day 4, but then its mean value is still the lowest compared to other groups

indicating the angiogenesis was still delayed. Nevertheless, it is not statistically significant different from G2, G3, G5, and G6. Generally, there was no statistical prominent different in term of fibroblast presence in all groups (treated diabetic and non-diabetic group). But then, G1 still occupy the lowest mean score ranking expected due to the low angiogenesis mean score. This had caused the collagen fibers formation to be statistically the least in group 1, while groups treated with alveolex and BA was comparable to non-diabetic group. In term of epithelization, some of the data were statistically interconnected based on their standard deviation value. This has makes it hard to form a clear lines to see the effect of alveolex and BADG to the epithelization process at day 7. Again, the formation of woven bone is comparable in all groups at day 7, with their values about 1+ which means minimal to mild. Between 3% BADG (G3), 5% BADG (G4) and 10% BADG (G5), there were no marked statistical different between each of them in all the scorings. Nevertheless, G4 (5%) scored the highest mean value for each of the criteria at day 7. Fig 1 (b, e, h) and fig 2 (b, e, h) shows that the necrotic tissue now slowly being separated from demarcation line, and the surface is slowly covered by proper epithelization in all groups.

Based on table 3 (day 18), G1 remains the highest PMNL mean score which means the inflammation remains high even after 18 days tooth extraction procedure. However, to a certain extent, G1, G2 and G3 are comparable in term of their neutrophils scatter. G4 was found to had lesser neutrophils count, comparable to G6. This means 5% BA helped to minimize the acute inflammation of the wound at day 18. Non-diabetic group seems to have better macrophage reduction, and none of the diabetic group treated with plain gel, alveolex, and BADG can distinguish positive effect in reducing macrophage presence at day 18 compared to G1. This might be due to some chronic wounds that remain in diabetic rats, denoted by high macrophage scatterings. Besides, at day 18 there were no clear boundaries proving the positive effect of diabetic rats treated with alveolex or BADG to the angiogenesis, fibroblast and collagen. The angiogenesis scores in all groups decreased from day 7 to day 18. This is expected because proliferation phase is about to end, and wound maturation is about to start. Despite not being significantly different with all other groups, the mean score of fibroblast and collagen fibers of diabetic rats treated with 3% BA and 5% BA was the nearest to non-diabetic rats, while group treated with plain gel had the lowest mean score. This proves the benefits of 3% and 5% BADG to the wound healing towards fibroblast and collagen formation. It was also clear that 3% and 5% BADG helped in

term of epithelization significantly the same level with non- diabetic rats (G6). BADG of 5% concentration shown total keratinization effect to the epithelium, the same with non-diabetic rats, while BADG of 3% shows epithelization that bridge the excision and almost approaching total keratinization in most of the group. As seen in fig 1 (f, i) and fig 2 (c, f, i), keratinization of epithelium was shown with the green arrow in G2, G3, G4, G5, and G6. It was clear that these groups had total epithelization at day 18 except for G1. Theoretically, epithelization process started from the adjacent cells and edge of the wound graft. In healthy rats, the wound is expected to cover the entire graft's surface within 14 days [38]. That is why the mean epithelization score for G6 was the highest among others at day 7, and it is approaching entire coverage of the wound at 7 to 18 days. Regarding woven alveolar bone formation, all the groups shown mild to moderate score, indicating regardless of any treatment, the rate of bone formation remains the same. The progression of alveolar woven seems to be in the scale of nearest to mild for G1 and G2; and mild to moderate for G3-G6. According to Araujo et al. [39], a complete alveolar bone remodeling with marked dimensional alteration (expected as normal process after tooth extraction) progress within 8 weeks. Despite not being significant different within all groups, diabetic groups were seen to possess lower mean woven bone formation score. This is supported by Inouye et al, based on his review [40], where diabetic will cause incomplete bone healing, and the new woven bone formation will be less organized. This happens because of destruction of bone and connective tissue caused by reduction of collagen fibers formation. Overall, there is progressive bone formation in all groups from day 4, to day 18.

Basically, present research had found that alveolex significantly promotes faster angiogenesis, presence of fibroblast collagen fibres formation and epithelization on day 4, and promotes collagen fibres formation on day 7. However at day 18, the results were almost the same with diabetic group treated with plain gel only. According to Jacob et al [41], propolis (which is one of the ingredients of alveolex) had speed up the fibroblast migration and proliferation to the wound sites. This fact again proved by present study where fibroblast proliferation were clearly seen in G2 at day 4 compared to G1. BADG were believed to possess potential wound healing properties due to its ability in inhibiting the inflammatory biomarkers as well as improving blood plasma antioxidant content [42]. Traditionally, there were quite a number of plants and herbs being used to treat illness and diseases based on history by local communities [43, 44, 45, 46]. Diabetes mellitus is believed to cause excess production of reactive oxygen species

(ROS), mainly due to high blood glucose level thus causing oxidative stress to the body tissues. Basically, oxidative stress will cause a total excess in free radical production due to decreased antioxidant balance in reducing the free radicals. In patients suffering from diabetes mellitus, oxidative stress were believed to be the main contributor to chronic inflammation [47]. Due to this negative effect of ROS, it is important to re-stabilize them with the presence of antioxidant defence action [48].

Based on the present study, BADG was found to improve and speed up the process of wound healing in diabetic rats. It was proven by positive effect shown by G3, G4, and G5 mean score in major categories. Overall, better improvements in wound healing were seen in G4 (5% BADG) followed by G3 (3% BADG) and G5 (10% BADG). This is supported by previous study done by Geethalakshmi et al [49] had also found that 5% wt of *Sphaeranthus amaranthoides* methanol extracts were capable of contributing to better wound healing than positive control. A comparable study in which the results shows inter-group non-significant different was done by Poubel et al. (2017) [50]. He found that the inflammation intensity of tooth extractions wounds in rats treated with biphosphanates, denosumab, and control were not significantly different between each other.

Analysing in the context of BADG effect only, all BADG promotes new vessels, fibroblast migration to wound site, collagen fibres formation, and epithelization comparable to the positive control group (alveolex treated group), and non-diabetic group as early as day 4. However the mean scores differences in most categories was not really seen in day 7. At day 18, all BADG group generally had better mean score compared to diabetic group (G1. At day 18, G4 was found to obviously minimize the PMNL score, accompanied by low mean macrophage score making it at par with healthy non-diabetic groups. This proves BADG helps to suppress and minimize the prolonged chronic inflammation. In term of new vessel formation, it was found that BADG helped to stimulate the neovascularisation as early as day 4 compared to G1. The same effect happens in G2 and G6. Major reduction of neovascularisation was seen at day 18 for all the BADG groups, contradict to G1 which only reduce minimally. This means BADG does help to stimulate the neovascularisation earlier than G1, thus the phases of wound healing was approaching the final stage of proliferation phase upon day 18. This result was supported by Isler et al [51] who found that traditional medicinal plant extract (Ankaferd blood stopper) had conclusively decreased necrotic tissue and inflammation at the healing sites due to its high antioxidant content.

Regarding fibroblast migration to the granulation tissue, all BADG treated diabetic group were found to contain prominent fibroblast compared to GP1 for day 4 and 7, and comparable effect to alveolex treated group and non-diabetic group at all days 4, 7, and 18. Fibroblast is very important because it indicates the starts of proliferation phase, and produces the collagen fibre to cover and replace the empty space of the wound. Without prominent fibroblast (like in group 1), wound healing will be delayed. For collagen fibres score, BADG treated group had accelerated the production of collagen fibres in all concentrations of BADG. The values were also comparable to G2 and non- diabetic rats at day 4 and day 7, indicating the positive effect of BA in wound healing process. Comparable result was found by Yoneda et al. [52] who studied the effect of fat soluble antioxidant (rCoQ10) on the wound healing of tooth extraction rats after 3days. The group treated with rCoQ10 had improved collagen fibres production and the inflammatory reaction at the applied area was suppressed as early as 3 days compared to control group.

CONCLUSION

The overall result of this study suggest that BADG does significantly promotes tooth extraction wound healing in diabetic rats in term of angiogenesis, presence of fibroblast at the wound sites, collagen fibers formation, and epithelization comparable to positive control and non-diabetic rats at early phase of the wound. The positive effects were not obvious at day 7, while at day 18, groups treated with BADG had better mean values in most categories although may not statistically significant different. BADG concentration of 4% was found to give the best effects on wound healing. Therefore, the objective of this study was achieved, and the hypothesis were accepted where to a certain extent, *Baccaurea angulata* extract does promotes wound healing.

OUTPUT

The authors successfully presented and published partial findings from RIGS15-047-0047 in various conferences abstract/ proceedings, including:

- International Conference of Industrial Pharmacy (ICIP) 2016. (Poster Presentation).
- 13th Malaysian Pharmaceutical Society – Pharmacy Scientific Conference (MPSPSC2017). (Oral presentation)
- Kulliyyah of Pharmacy Research Symposium 2017 (Poster presentation)

- Postgraduate Intellectual, Research and Publication Week 2017 (Colloquium Oral presentation).
- Conference on Biomedical & Advanced Materials (Bio-CAM 2017) (publication in abstract book and proceedings)
- Publication in Malaysian Journal of Pharmacy (Vol 3, Issue 1, November 2017).
- In progress of submission for publication in Materials Today: Proceedings Journal. The abstract already been accepted by Bio-CAM 2017 conference.
- In progress in publication in ISI/scopus indexed journal.

FUTURE PLAN OF THE RESEARCH

Future research can be conducted to investigate in more details about the wound healing effect of *Baccaurea angulata*, including immunohistopathological study, and gene expressions.

ACKNOWLEDGEMENTS

This research was funded by the Research and Innovation Grant Scheme: RIGS 15-047-0047 of International Islamic University Malaysia.

DECLARATION OF INTEREST

The authors report no declarations of interest

REFERENCES

1. Dunhill C, Patton T, Brennan J, et al. Reactive oxygen species (ROS) and wound healing: the functional role of ROS and emerging ROS-modulating technologies for augmentation of the healing process. *International Wound Journal*. 2015;14(1):89-96. doi: 10.1111/iwj.12557.
2. Baltzis D, Eleftheriadou I, Veves A. Pathogenesis and treatment of impaired wound healing in diabetes mellitus: new insights. *Advances in therapy*. 2014;31(8):817-836.
3. Boulton AJ. The pathway to foot ulceration in diabetes. *Medical Clinics*. 2013;97(5):775-790.
4. Association AD. Diagnosis and classification of diabetes mellitus. *Diabetes care*. 2014;37(Supplement 1):S81-S90.
5. Sharma Y, Jeyabalan G, Singh R. Potential wound healing agents from medicinal plants: a review. *Pharmacologia*. 2013;4:349.
6. Larjava H. *Oral Wound Healing: An Overview*. First ed. Oxford: John Wiley & Sons Inc; 2012. (Oral Wound Healing: Cell Biology and Clinical Management).

7. Mohn CE, Steimetz T, Surkin PN, et al. Effects of saliva on early post-tooth extraction tissue repair in rats. *Wound Repair Regen.* 2015 Mar-Apr;23(2):241-50. doi: 10.1111/wrr.12271. PubMed PMID: 25693741.
8. Hussein Z, Taher SW, Gilcharan Singh HK, et al. Diabetes Care in Malaysia: Problems, New Models, and Solutions. *Annals of Global Health.* 2015 2015/11/01;81(6):851-862. doi: <https://doi.org/10.1016/j.aogh.2015.12.016>.
9. Barone A, Ricci M, Tonelli P, et al. Tissue changes of extraction sockets in humans: a comparison of spontaneous healing vs. ridge preservation with secondary soft tissue healing. *Clinical oral implants research.* 2013;24(11):1231-1237.
10. Manrique N, Pereira CCS, Garcia LMG, et al. Alveolar bone healing process in spontaneously hypertensive rats (SHR): A radiographic densitometry study. *Journal of Applied Oral Science.* 2012;20(2):218-221.
11. Ahmed D, Khan MM, Saeed R. Comparative Analysis of Phenolics, Flavonoids, and Antioxidant and Antibacterial Potential of Methanolic, Hexanic and Aqueous Extracts from *Adiantum caudatum* Leaves. *Antioxidants (Basel).* 2015 Jun 04;4(2):394-409. doi: 10.3390/antiox4020394. PubMed PMID: 26783712; PubMed Central PMCID: PMC4665467.
12. Kwansang J, Itthipanichpong C, Limpanasithikul W. Evaluation of wound healing activity of *Thunbergia laurifolia* supercritical carbon dioxide extract in rats with second-degree burn wounds. *Journal of advanced pharmaceutical technology & research.* 2015;6(3):103.
13. Das B, Nayak AK, Nanda U. Topical gels of lidocaine HCl using cashew gum and Carbopol 940: preparation and in vitro skin permeation. *Int J Biol Macromol.* 2013 Nov;62:514-7. doi: 10.1016/j.ijbiomac.2013.09.049. PubMed PMID: 24099938.
14. Gaikwad DD, Banerjee SK. Development and evaluation of herbal gel formulation of *Magnifera indica* linn extract. *Int J Res Pharm Sci.* 2013;4(2):260-5.
15. Furman BL. *Streptozotocin-Induced Diabetic Models in Mice and Rats.* Current Protocols in Pharmacology: John Wiley & Sons, Inc.; 2015.
16. Yao CH, Yeh JY, Chen YS, et al. Wound-healing effect of electrospun gelatin nanofibres containing *Centella asiatica* extract in a rat model. *Journal of tissue engineering and regenerative medicine.* 2017;11(3):905-915.
17. Ganesan A, Mahesh A, Sundararaj JP, et al. Antihyperglycemic and anti-oxidant activity of various fraction of *Parmotrema hababianum* in streptozotocin-induced diabetic rat. *Bangladesh Journal of Pharmacology.* 2016;11(4):935-939.
18. Bulut E, Baş B, Altunkaynak B, et al. Efficacy of Ankaferd Blood Stopper on bone healing in diabetic rats: a stereological and histopathological study. *Biotechnic & Histochemistry.* 2014;89(7):535-543.
19. Nugroho JJ, Hafsari WR. The effectiveness of betel leaf (*Piper betle* Linn) extract gel and cocoa bean (*Theobroma cacao* L) extract gel application against the hardness of enamel surface in vitro. 2017.
20. Niedzielska I, Puszczewicz Z, Mertas A, et al. The Influence of Ethanolic Extract of Brazilian Green Propolis Gel on Hygiene and Oral Microbiota in Patients after Mandible Fractures. *BioMed research international.* 2016;2016.
21. IACUC TUoP. IACUC Guideline: Mouse and rat anesthesia and analgesia recommendations. United States 2017 [cited 2017 3 /10/ 2017]. Available from: <http://www.upenn.edu/regulatoryaffairs/Documents/iacuc/guidelines/IACUCGuideline-MouseAndRatAnesthesiaAndAnalgesia.pdf>

22. Tascilar O, Çakmak G, Emre A, et al. N-acetylcysteine attenuates the deleterious effects of radiation therapy on incisional wound healing in rats. *HIPPOKRATIA*. 2014;18(1):17-23.
23. Pennsylvania TUo. IACUC Guideline Euthanasia of Rodents 2016 [updated Approved on 28/6/2016; cited 3 October 2017]. Available from: <http://www.upenn.edu/regulatoryaffairs/Documents/iacuc/guidelines/iacucguideline-rodenteuthanasia.pdf>
24. Leary SL, Underwood W, Anthony R, et al., editors. AVMA guidelines for the euthanasia of animals: 2013 edition 2013: American Veterinary Medical Association Schaumburg, IL.
25. Scudamore CL, Soilleux EJ, Karp NA, et al. Recommendations for minimum information for publication of experimental pathology data: MINPEPA guidelines. *The Journal of pathology*. 2016;238(2):359-367.
26. Vent J, Zimmermann C, Drebber U, et al. Influence of formalin fixation on tissue dimensions in palatal tonsils. *Pathology - Research and Practice*. 2014 2014/01/01/;210(1):59-61. doi: <https://doi.org/10.1016/j.prp.2013.10.002>.
27. Liu H, Zhu R, Liu C, et al. Evaluation of Decalcification Techniques for Rat Femurs Using HE and Immunohistochemical Staining. *BioMed research international*. 2017;2017.
28. Rolls G. An Introduction to Decalcification [cited 2016 3 November 2016]. Available from: <http://www.leicabiosystems.com/pathologyleaders/an-introduction-to-decalcification/>
29. FL C. *Histotechnology*. 2nd ed. Chicago: ASCP Press; 2007.
30. Cardiff RD, Miller CH, Munn RJ. Manual hematoxylin and eosin staining of mouse tissue sections. *Cold Spring Harbor protocols*. 2014;2014(6):pdb.prot073411.
31. Turkki R, Linder N, Kovanen PE, et al., editors. Identification of immune cell infiltration in hematoxylin-eosin stained breast cancer samples: Texture-based classification of tissue morphologies. *Proceedings of the International Society for Optics and Photonics (SPIE) Conference on Medical Imaging, San Diego, CA, USA; 2016*.
32. Gupta A, Kumar P. Assessment of the histological state of the healing wound. *Plastic and Aesthetic Research*. 2015;2(5). doi: 10.4103/2347-9264.158862.
33. Gal P, Toporcer T, Vidinsky B, et al. Early Changes in the Tensile Strength and Morphology of Primary Sutured Skin Wounds in Rats. *Folia Biologica (Praha)*. 2006;52:109-115.
34. Gal P, Kilik R, Mokry M, et al. Simple method of open skin wound healing model in corticosteroid-treated and diabetic rats: standardization of semi-quantitative and quantitative histological assessments. *Vet Med*. 2008;53(12):652-9.
35. Pereira NT, Issa JPM, Nascimento CD, et al. Effect of alveolex on the bone defects repair stimulated by rhBMP-2: Histomorphometric study. *Microscopy research and technique*. 2012;75(1):36-41.
36. Bankova V, Popova M, Trusheva B. Propolis volatile compounds: chemical diversity and biological activity: a review. *Chemistry Central Journal*. 2014;8(1):28.
37. Hames-Kocabas EE, Demirci B, Uzel A, et al. Volatile composition of anatolian propolis by headspace-solid-phase microextraction (HS-SPME), antimicrobial activity against food contaminants and antioxidant activity. *Journal of Medicinal Plants Research*. 2013;7(28):2140-2149.

38. Sculean A, Gruber R, Bosshardt DD. Soft tissue wound healing around teeth and dental implants. *Journal of Clinical Periodontology*. 2014;41:S6-S22. doi: 10.1111/jcpe.12206.
39. Araújo MG, Lindhe J. Dimensional ridge alterations following tooth extraction. An experimental study in the dog. *Journal of clinical periodontology*. 2005;32(2):212-218.
40. Inouye KAS, Bisch FC, Elsalanty ME, et al. Effect of Metformin on Periimplant Wound Healing in a Rat Model of Type 2 Diabetes. *Implant Dentistry*. 2014;23(3):319-327. doi: 10.1097/id.000000000000069. PubMed PMID: 00008505-201406000-00016.
41. Jacob A, Parolia A, Pau A, et al. The effects of Malaysian propolis and Brazilian red propolis on connective tissue fibroblasts in the wound healing process [journal article]. *BMC Complementary and Alternative Medicine*. 2015 August 25;15(1):294. doi: 10.1186/s12906-015-0814-1.
42. Mikail MA, Ahmed IA, Ibrahim M, et al. *Baccaurea angulata* fruit inhibits lipid peroxidation and induces the increase in antioxidant enzyme activities. *Eur J Nutr*. 2016 Jun;55(4):1435-44. doi: 10.1007/s00394-015-0961-7. PubMed PMID: 26091909.
43. Mikail MA, Ahmed IA, Ibrahim M, et al. Changes in the Markers of Atherosclerosis Following Administration of Belimbing Dayak (*Baccaurea Angulata*) Fruit Juice in Experimental Rabbits Fed with Cholesterol Diet. *International Journal of Advances in Agricultural and Environmental Engineering*. 2014;1(2). doi: 10.15242/ijaaee.c614516.
44. Surya S, Salam AD, Tomy DV, et al. Diabetes mellitus and medicinal plants-a review. *Asian Pacific Journal of Tropical Disease*. 2014 2014/10/01/;4(5):337-347. doi: [https://doi.org/10.1016/S2222-1808\(14\)60585-5](https://doi.org/10.1016/S2222-1808(14)60585-5).
45. Hübsch Z, Van Zyl R, Cock I, et al. Interactive antimicrobial and toxicity profiles of conventional antimicrobials with Southern African medicinal plants. *South African Journal of Botany*. 2014;93:185-197.
46. Molina-Garza ZJ, Bazaldúa-Rodríguez AF, Quintanilla-Licea R, et al. Anti-Trypanosoma cruzi activity of 10 medicinal plants used in northeast Mexico. *Acta tropica*. 2014;136:14-18.
47. Rochette L, Zeller M, Cottin Y, et al. Diabetes, oxidative stress and therapeutic strategies. *Biochimica et Biophysica Acta (BBA) - General Subjects*. 2014 2014/09/01/;1840(9):2709-2729. doi: <https://doi.org/10.1016/j.bbagen.2014.05.017>.
48. Brasnyó P, et al. Resveratrol and Oxidative Stress in Diabetes Mellitus, in *Diabetes: Oxidative Stress and Dietary Antioxidants*, . In: Preedy VR, editor. San Diego: Academic Press; 2014. p. 99-109.
49. Geethalakshmi R, Sakravarthi C, Kritika T, et al. Evaluation of antioxidant and wound healing potentials of *Sphaeranthus amaranthoides* Burm. f. *BioMed research international*. 2013;2013.
50. Poubel VLDN, Capella DL, Santos ARS, et al. Evaluation of mandibular bone after dental extraction in rats treated with antiresorptive drugs. *Journal of Oral and Maxillofacial Surgery*. 2017.
51. İŞLER SC, Demircan S, ÇAKARER S, et al. Effects of folk medicinal plant extract Ankaferd Blood Stopper(®) on early bone healing. *Journal of Applied Oral Science*. 2010 Jul-Aug

52. Yoneda T, Tomofuji T, Kawabata Y, et al. Application of coenzyme Q10 for accelerating soft tissue wound healing after tooth extraction in rats. *Nutrients*. 2014;6(12):5756-5769.

TABLES AND FIGURES

Table 1: Wound healing score for day 4

Group	PMNL	Macrophage	Angiogenesis	Fibroblast	Collagen	Epithelization	Woven Bone
1	3.77 ± 0.15 ^a	3.3 ± 0.26 ^a	0.67 ± 0.21 ^a	0.73 ± 0.49 ^a	0.57 ± 0.55 ^a	0.33 ± 0.15 ^c	0.17 ± 0.06 ^a
2	3.63 ± 0.15 ^a	3.3 ± 0.1 ^a	1.5 ± 0.36 ^b	1.67 ± 0.15 ^b	2.2 ± 0.10 ^b	1.13 ± 0.06 ^b	0.23 ± 0.23 ^a
3	3.6 ± 0.26 ^a	3.37 ± 0.15 ^a	1.8 ± 0.1 ^b	1.70 ± 0.10 ^b	2.5 ± 0.1 ^b	1.10 ± 0.35 ^b	0.27 ± 0.12 ^a
4	3.37 ± 0.15 ^a	3.37 ± 0.15 ^a	1.83 ± 0.06 ^b	1.53 ± 0.06 ^b	2.5 ± 0.1 ^b	1.50 ± 0.10 ^{ab}	0.20 ± 0.10 ^a
5	3.73 ± 0.12 ^a	3.3 ± 0.10 ^a	1.93 ± 0.06 ^b	1.63 ± 0.06 ^b	2.6 ± 0.1 ^b	1.63 ± 0.06 ^a	0.33 ± 0.15 ^a
6	2.6 ± 0.2 ^b	3.53 ± 0.12 ^a	1.77 ± 0.23 ^b	1.37 ± 0.21 ^b	2.27 ± 0.35 ^b	1.27 ± 0.12 ^{ab}	0.47 ± 0.15 ^a

Note: Values were expressed as mean + SD. Values with the same letter in a row means they are statistically significant different ($p < 0.05$), and vice versa.

Table 2 : Wound healing score for day 7

Group	PMNL	Macrophage	Angiogenesis	Fibroblast	Collagen	Epithelization	Woven Bone
1	3.07 ± 0.37 ^{ab}	3.00 ± 0.50 ^a	1.77 ± 0.32 ^b	1.33 ± 0.15 ^b	1.23 ± 0.15 ^a	0.77 ± 0.38 ^b	1.67 ± 0.23 ^a
2	3.50 ± 0.36 ^a	3.27 ± 0.21 ^a	2.57 ± 0.65 ^{ab}	2.23 ± 0.64 ^{ab}	2.90 ± 0.56 ^b	1.73 ± 0.59 ^{ab}	1.73 ± 0.50 ^a
3	2.07 ± 0.12 ^c	3.60 ± 0.10 ^a	3.00 ± 0.61 ^{ab}	2.50 ± 0.10 ^{ab}	2.83 ± 0.06 ^b	1.60 ± 0.52 ^{ab}	1.53 ± 0.25 ^a
4	2.67 ± 0.31 ^{abc}	3.30 ± 0.36 ^a	3.27 ± 0.25 ^a	3.03 ± 0.25 ^a	3.23 ± 0.21 ^b	3.10 ± 0.10 ^a	1.37 ± 0.38 ^a
5	2.53 ± 0.12 ^{bc}	3.17 ± 0.25 ^a	2.93 ± 0.61 ^{ab}	2.93 ± 0.51 ^a	2.80 ± 0.26 ^b	2.03 ± 0.38 ^{ab}	1.20 ± 0.30 ^a
6	2.37 ± 0.57 ^{bc}	3.57 ± 0.15 ^a	2.73 ± 0.21 ^{ab}	2.57 ± 0.93 ^{ab}	2.90 ± 0.5 ^b	2.70 ± 0.95 ^a	1.73 ± 0.15 ^a

Note: Values were expressed as mean + SD. Values with the same letter in a row means they are statistically significant different ($p < 0.05$), and vice versa.

Table 3: wound healing score for day 18

Group	PMNL	Macrophage	Angiogenesis	Fibroblast	Collagen	Epithelization	Woven Bone
1	2.43 ± 0.93 ^a	2.67 ± 0.42 ^a	1.67 ± 0.21 ^{abc}	2.73 ± 1.33 ^a	2.80 ± 1.39 ^a	1.93 ± 1.34 ^b	1.93 ± 0.40 ^a
2	1.97 ± 1.01 ^{ab}	2.67 ± 1.04 ^a	2.3 ± 0.95 ^a	3.07 ± 0.85 ^a	3.13 ± 0.75 ^a	3.07 ± 0.81 ^{ab}	1.99 ± 0.26 ^a
3	0.80 ± 0.17 ^{ab}	1.37 ± 0.15 ^{ab}	1.00 ± 0.26 ^{bc}	3.97 ± 0.06 ^a	3.97 ± 0.06 ^a	3.93 ± 0.11 ^a	2.10 ± 0.36 ^a
4	0.40 ± 0.10 ^b	1.37 ± 0.15 ^{ab}	1.27 ± 0.15 ^{abc}	4.00 ± 0.00 ^a	4.00 ± 0.00 ^a	4.00 ± 0.00 ^a	2.27 ± 0.32 ^a
5	1.00 ± 0.44 ^{ab}	2.03 ± 0.40 ^{ab}	2.17 ± 0.55 ^{ab}	3.47 ± 0.15 ^a	3.5 ± 0.17 ^a	2.73 ± 0.15 ^{ab}	2.17 ± 0.32 ^a
6	0.33 ± 0.23 ^b	1.17 ± 0.31 ^b	0.83 ± 0.06 ^c	3.97 ± 0.06 ^a	4.00 ± 0.00 ^a	4.00 ± 0.00 ^a	2.63 ± 0.15 ^a

Note: Values were expressed as mean + SD. Values with the same letter in a row means they are statistically significant different ($p < 0.05$), and vice versa.

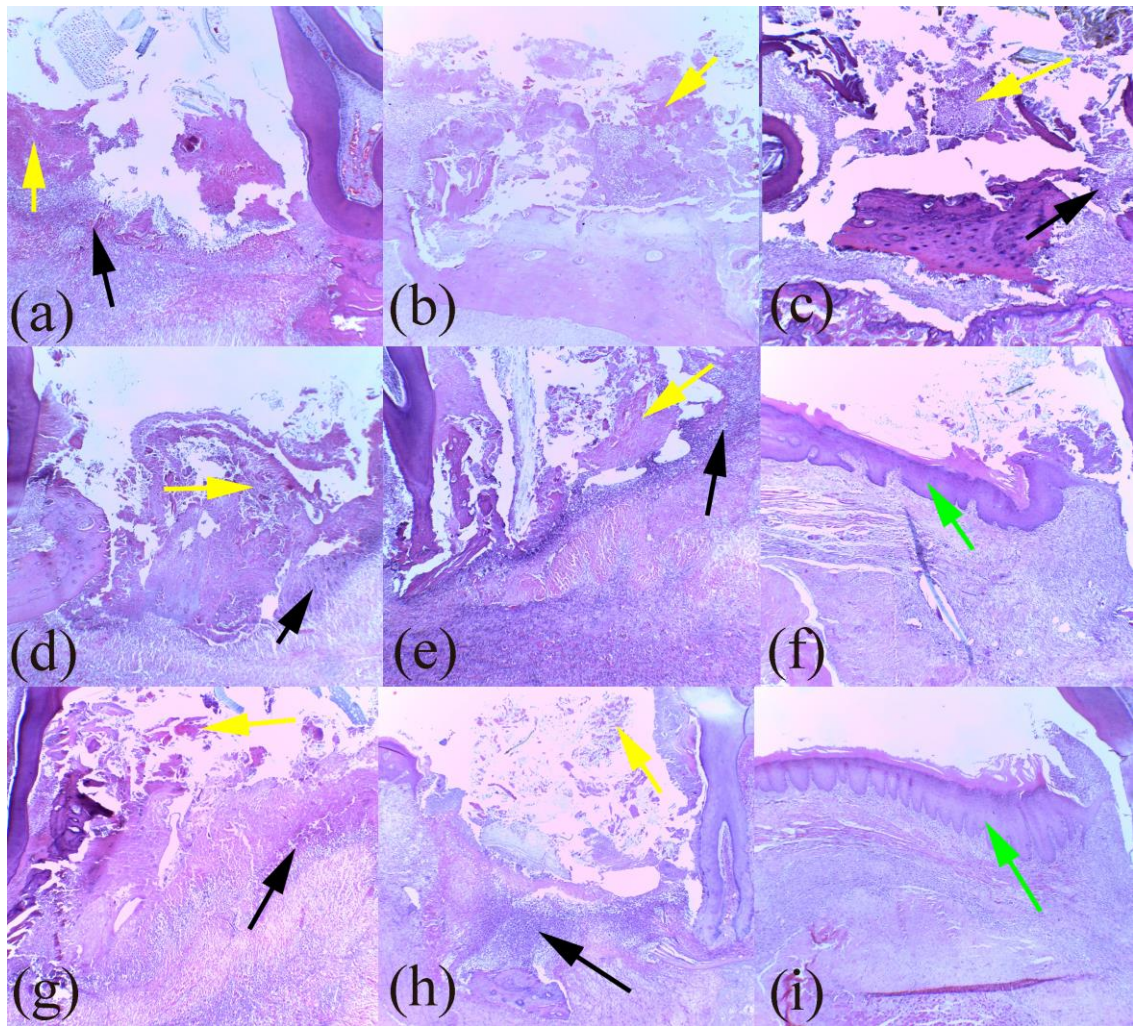


Fig 1: Histopathological evaluation of the alveolar socket in each for different group where (a), (d), and (g) is day 4 for G1, G2, and G3 respectively; (b), (e), and (h) are day 7 for G1, G2, and G3 respectively; (c), (f), and (i) are day 18 for G1, G2, and G3 respectively. Black arrow indicates the demarcation line with prominent PMNL; while yellow arrow indicated the necrotic tissue, and green arrow indicates the epithelization with proper keratinization.




Fig 2: Histopathological evaluation of the alveolar socket in each for different group where (a), (d), and (g) is day 4 for G4, G5, and G5 respectively; (b), (e), and (h) are day 7 for G4, G5, and G6 respectively; (c), (f), and (i) are day 18 for G4, G5, and G6 respectively. Black arrow indicates the demarcation line with prominent PMNL; while yellow arrow indicated the necrotic tissue, and green arrow indicates the epithelization with proper keratinization.