

DIFFERENCES BETWEEN UNTRANSFORMED AND SPATIALLY NORMALIZED PET IMAGES IN THE FUNCTIONAL COMPARISON OF SCHIZOPHRENIC PATIENTS AND CONTROLS



S. Reig*, J. Gisbert*, J. Pascau*, R. Martinez*, V. Molina†, J. Vaquero*, M. Desco*

*Dept. of Experimental Medicine, Hospital Gregorio Marañón; †Psychiatry, Hospital Clínico Universitario

Introduction: A common problem in quantitative studies involving multi-subject analysis of brain functional images is the requirement of a spatial normalization step to provide a standardized reference space.

Since SPM is one of the most widely used analytical approaches for functional studies, our aim is to investigate differences in metabolic activity measurements in positron emission tomography (PET) images with or without the spatial normalization performed by SPM. The possible effect of the normalization will be evaluated in a comparison of metabolic activity between schizophrenic patients and controls.

Patients and Methods: A total of 38 subjects (22 schizophrenic patients and 16 controls) were included in the study. Each subject underwent structural magnetic resonance imaging (MRI) and functional 2-deoxy-2-[18F] fluoro-D-glucose positron emission tomography (FDG-PET) scans. MRI studies were acquired on a Philips Gyroscan 1.5T scanner (gradient echo T1-weighted 3-D sequence). FDG-PET scans were obtained in resting condition with a Posicam EZL PET scanner 20 minutes after the injection of 370 MBq of FDG (matrix size 256 x 256 x 61, slice thickness 2.6 mm). Scans from each subject were realigned to a PET template following the standard procedure included in the SPM99 package. MRI enabled the use of a semi-automatic method for quantification and segmentation of the brain, based on the Talairach coordinate system. Seven brain structures were analyzed: thalamus, caudate head, pallidum-putamen, frontal, temporal, parietal and occipital lobes.

Results: The main differences attributable to the disease, which involve the frontal and parietal lobes, are detected using either of the data sets. However, using the normalized images we would conclude a group difference located in the thalamus, whereas original data suggest another pattern of differences, located in the pallidum-putamen. Group differences at the caudate nucleus are also more pronounced in the normalized data set.

Discussion: The results reported here confirm that the spatial normalization may introduce an important bias in the regional measurement of the metabolic activity. This potential bias arises from the geometric transformations applied to the original geometry of the brain to match the morphology of the SPM-PET template, particularly when there exist anatomical differences between the groups involved in the comparison. The relationships between brain morphological variability and the impact of spatial normalization in SPM analysis should be further investigated whenever significant deviations of brain morphology caused by the disease are expected, as it is the case of the schizophrenia.

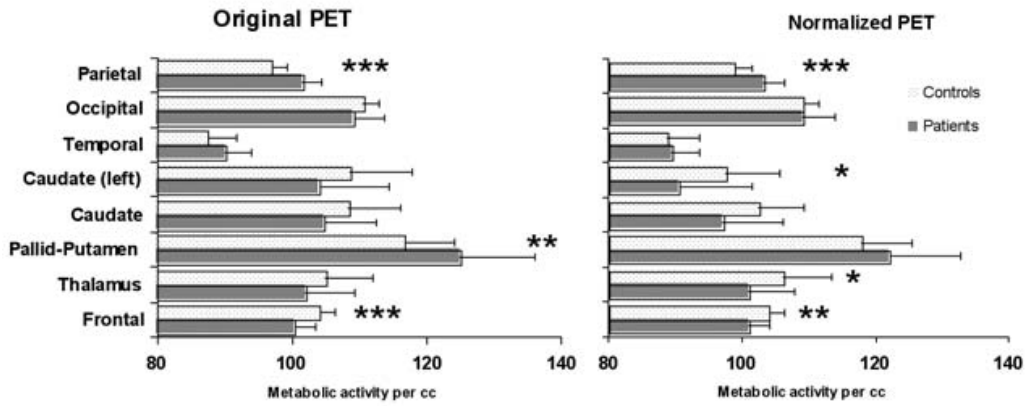


Figure1. Results of testing for group differences between patients and controls using original or spatially normalized PET. Regions showing significant differences (Student t test) between group means of patients and controls are marked with asterisks