



## Assessment of The Efficacy of CBCT Referral Forms at Faculty of Dentistry, International Islamic University Malaysia

Abu Bakar N<sup>1</sup>

<sup>1</sup> Assistant Professor, Department of Orthodontics, Dental Faculty, International Islamic University Malaysia, Kuantan Campus, Kuantan, Pahang, Malaysia

### ABSTRACT

**Introduction:** Cone beam computed tomography (CBCT) has gained interest for improving diagnosis, treatment planning and facilitating better patient's management in various dental fields. This study is part of the quality assurance programme in Dental Faculty, International Islamic University Malaysia (IIUM). This center offers dental radiography service not only for internal clinics but also act as a referral center for the eastern areas, Pahang, Malaysia. **Aims:** The aims of this study were; 1) to assess referral pattern for CBCT scans at the Dental Faculty, IIUM, Kuantan, and 2) to evaluate the completeness of the current referral form used by clinicians (for both internal and external referrals). **Methods:** An audit looking at both the external and internal referral CBCT forms of a four year period of examination (2010-2013) at the Radiology Unit, Dental Faculty, IIUM. Source of referrals, indications for CBCT and the referral forms were examined and analysed. **Results:** Total CBCT scans taken within the four-year period were 171, in which 96 were referred from internal sources whilst 75 were external referrals. External referrals were mainly from Paediatric Dentistry and Orthodontic clinics (59%), while other referrals were from implant clinic (20%), Paediatrics and Special Needs clinic (15%), Oral Maxillofacial Surgery clinic (4%) and Periodontic clinic (1%) and Oral Medicine Oral Pathology (OMOP) clinics (1%). All forms from external sources are completely filled. In the Internal referral form, 41% of them came with no indication of why CBCT need to be taken. Out of 59% of cases with indications, 33% came from Paediatric Dentistry and Orthodontic department, followed by Oral Surgery department (10%). Implant treatment planning accounted for 7% of cases, Periodontics 4%, Temporo-Mandibular Joint assessment 2%, 1% for Conservative dentistry and Prosthodontic cases respectively and 1% cleft case. Further analysis of the internal referral forms revealed that only 14% of the forms were filled with complete patients' details, 40% specified pregnancy status and 67% clearly stated patients' medical status. Area of interest was not specified in 69% of cases and clinicians' names were not stated in 94% of the cases. Majority of the forms were completed with clinicians' signature (99%) and also radiographers' details (97%). **Conclusions:** This study indicated that the majority of IIUM CBCT referrals were from internal sources. However, most of the referral forms were not completely filled. The internal form used, therefore, need to be improved and a much firmer referral framework should be in place.

**Key Words:** CBCT, Clinical effectiveness, Referral form

Please cite this article as: Abu Bakar N. Assessment of the efficacy of CBCT referral forms at Faculty of Dentistry, International Islamic University Malaysia. Malaysian Dental Journal 2015; 37(1): 30-38.

### INTRODUCTION

The use of cone beam computed tomography (CBCT) in dentistry was recorded since 1990 and has gained increasing interest since then as a modality for improving diagnosis, treatment planning and facilitating better patient management.<sup>1</sup>

CBCT works by utilizing a cone-shaped x-ray beam that rotates around the patient to acquire a

volumetric data set of the area of interest with a single rotation.<sup>2</sup> One of the advantages of CBCT is its low radiation dose compared to conventional CT scanning. In addition, it has an advantage over plain radiographs in its ability to reproduce three-dimensional images of anatomical structures.<sup>3</sup>

A variety of clinical applications of CBCT have been reported. These include localizing impacted maxillary canines,<sup>4</sup> examination of

temporo-mandibular joint,<sup>5</sup> planning orthognathic surgery with a 3D virtual planning software evaluation,<sup>6</sup> assessment of upper airway area and volume,<sup>7</sup> treatment planning of dental implants<sup>8</sup> and clinical assessment of bone grafting.<sup>9</sup> In spite all the advantages, repeated or unnecessary exposures may pose a potential hazard to individuals. Therefore, CBCT should be used with caution until more robust evidence based referral criteria are developed.<sup>10</sup>

The Dental Faculty of International Islamic University Malaysia (IIUM) has four CBCT machines, three units are installed in the main clinic (Plameca Promax 3D Max, Medium and Small) and one unit, Plameca Promax 3D, is located in the Satellite building. This center offers a dental radiography service not only for its internal clinics (internal referral) but also acts as a referral center mainly for Ministry of Health hospitals and clinics of the eastern areas of the state of Pahang, Malaysia (external referral).

This study was part of the quality assurance programme to assess the efficacy of the referral forms used for CBCT at the Dental Faculty, IIUM.

## AIMS

The aims of this study were:

- 1) To assess referral pattern for CBCT scans at the Dental Faculty, IIUM, Kuantan.
- 2) To evaluate the completeness of the current referral form used by clinicians (for both internal and external referrals).

## DESIGN AND SETTING

This was an audit, looking at the referral CBCT forms (both external and internal) over a four-year period (2010-2013) at the Radiology Unit, Dental Faculty, IIUM.

The source of referrals, the indications for CBCT scanning and the referral forms were examined and analyzed.

## STANDARD

There is no CBCT referral form available to serve as a reference modality.

## RESULTS

### 1) Demographics

Out of 17309 radiographs, the total of CBCT scans were taken within this four-year period were 171. Table 1 shows further breakdown of the CBCT scans taken annually from 2010-2013.

**Table 1.** CBCT scans taken within the four-year period at the Unit of Radiology, IIUM.

Year	Total of CBCT Taken
2010	18
2011	28
2012	45
2013	80
<b>TOTAL</b>	<b>171</b>

Out of 171 CBCT scans carried out in the (2010 to 2013), the majority were referred from internal clinics (Table 2).

**Table 2.** Referral Pattern for CBCT scans at Dental Faculty, IIUM Kuantan.

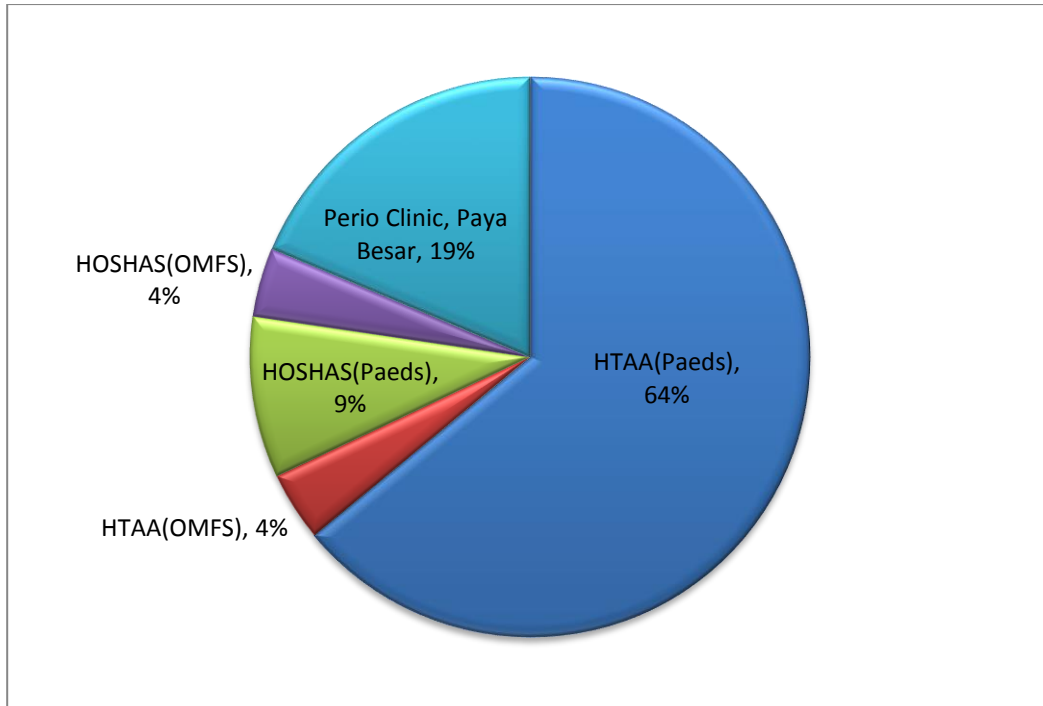
Referral	Total	Percentage
External Referral	75	44%
Internal Referral	96	56%

### 2) Analysis of Forms from External Referrals

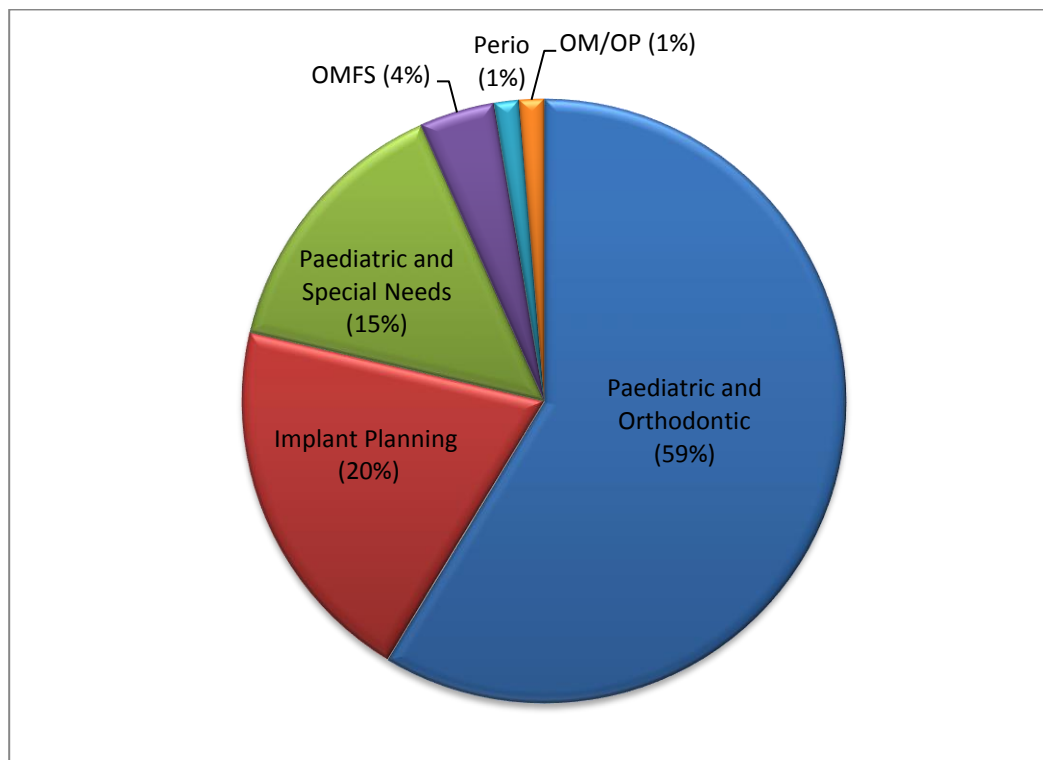
A majority of external cases were referred from Paediatric Dentistry Department, Hospital Tengku Ampuan Afzan (HTAA), Kuantan (64%), followed by Periodontic Clinic, Paya Besar, Kuantan (19%). Paediatric Dentistry Department, Hospital Sultan Haji Ahmad Shah (HOSHAS) Temerloh referred 9% of cases and Oral-Maxillo Facial Surgery (OMFS) Department from both HTAA and HOSHAS accounted for 4% of cases each (Figure 1). Figure 2 shows further analysis of the type of cases referred.

Most Paediatric and Orthodontic cases were indicated for assessing tooth impaction (89%). Other indications were to identify dilacerated tooth (4%), supernumerary (5%) and transposition (2%).

As for Paediatric and Special Need cases, they were referred due to swelling (7 cases), delayed eruption (2 cases), odontome (1 case) and gross caries with dentigerous cyst (1 case). One case was



**Figure 1.** The sources of external referrals.



**Figure 2.** The discipline pattern of the external referrals.

referred from Periodontics due to osteonecrosis of the jaw bone. Most cases from OMFS were indicated for assessment of impacted third molars prior to its removal and assessment of a lesion. All information was completely filled by the external

referred clinicians. An example of an external referral form is shown in Figure 3.

### 3) *Analysis of Forms from Internal Referrals*

Number of CBCT taken from internal source is shown in Table 3.




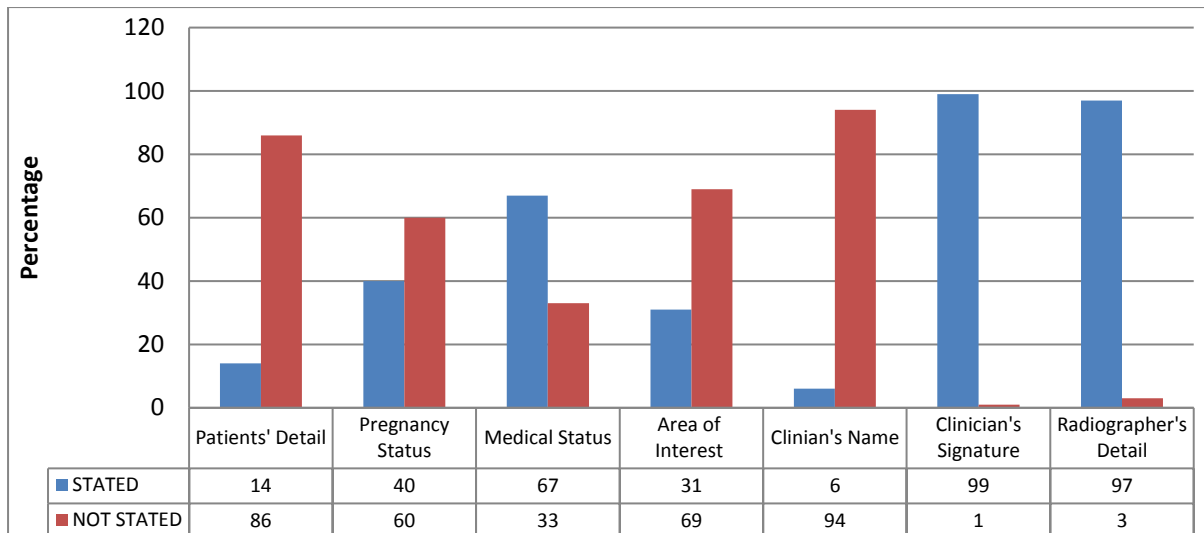
JABATAN PERKHIDMATAN PENGIMEJAN DIAGNOSTIK HOSPITAL							PER. SS-RA 301	
 <b>Borang Permohonan Pemeriksaan Radiologi</b> (Sila Isi Dalam 2 Salinan)								
1. Nama: (Huruf Besar) <b>Muhammad Afiq Syahmi</b>						KEGUNAAN JABATAN		
2. Alamat: <b>No. 644, Jg. Legok Kenen 20, Tanch Putih Baru</b>						23. Tarikh <b>15/2/2013</b>	24. No. X-Ray <b>1</b>	
3. No. Kad Pengenalan <b>701221-03-5066</b>	4. Keturunan <b>M</b>	5. Jantina <input checked="" type="checkbox"/> L <input type="checkbox"/> P	6. Tarikh Lahir <b>13/8/98</b>	7. Umur <b>15</b>	25. Bilik <b>Specialist KOD</b>	26. Waktu Terima <b>3.20 pm</b>		
8. No. Pendaftaran Hospital:			9. Wad/Klinik: <b>Dental Paeds</b>		27. Juru X-Ray <b>Mohd Nasfi (Clinic KOD)</b>			
10. Pakar/Perunding: <b>Dr. Suhaila</b>			11. Tarikh & Masa: <b>17/1/13</b>		28. Faktor Dedahan: <b>90 kV, 12 mAs</b>			
12. Pegawai Kerajaan <input type="checkbox"/> Ya <input type="checkbox"/> Tidak			13. Kelas	14. Bayaran <input type="checkbox"/> Bayar <input type="checkbox"/> Percuma	29. Ukuran & Jumlah Filem		30. Waktu Selesai <b>3.25 pm</b>	
15. Asma/Alergi: <b>Asma</b>			16. Berat Badan	17. Mengandung <input type="checkbox"/> Ya <input type="checkbox"/> Tidak				
18. Keadaan Pesakit <input type="checkbox"/> Kerusi Roda <input type="checkbox"/> Troli <input checked="" type="checkbox"/> Berjalan Kaki			19. <input type="checkbox"/> Mudah Gerak		31. Komen:			
PEMERIKSAAN						32. Temujanji		
<input checked="" type="checkbox"/> X-Ray <input type="checkbox"/> Ultrasound <input type="checkbox"/> M.R.I. <input type="checkbox"/> Angio <input checked="" type="checkbox"/> C.T. <input type="checkbox"/> Lain-lain (Sila Nyatakan) ..... Nyatakan Bahagian: <b>CBCT / CBVT <u>123</u></b>						Tarikh Masa		
21. Data klinikal: LMP: <b>15 y/o / M / O</b>						* kindly do cect/cbvt for <u>123</u> to locate exact position & relation of eye teeth. Td		
<b>Go: protruded ↓ jaw</b> <b>MHx: Asthma, inhaler p.n.</b> <b>O/E - Class 3 sh. base</b> - class III w/o 2 ant. open bite <u>123</u> - retained LC, unerupted <u>123</u> - distally angulated LL						 Nama, T/Tangan & Cop Pakar/Pegawai Perubatan		
22. Laporan Radiologi:								
								

Figure 3: Example of an external referral form

For CBCT prescribed internally, 41% of them came with no indication. Out of 59% of cases with indication, 33% were combined cases from Paediatric Dentistry and Orthodontic department,

followed by Oral Surgery (OS) department (10%). Implant treatment planning accounted for 7% of cases, Periodontics 4%, Temporo-Mandibular Joint (TMJ) assessment 2%, 1% for Conservative



**Figure 4.** Analysis of the completion of the internal referral forms.

Dentistry, 1% for Prosthodontic cases and 1% of cleft case.

Further analysis of the internal referral forms (Figure 4) revealed that only 14% of the forms were filled with complete patients' details whilst the majority (86%) were not.

**Table 3.** CBCT scans requested by internal source.

Year	Total of CBCT taken
2010	1
2011	10
2012	28
2013	57

Pregnancy status of female patients was clearly stated in 40% of cases but majority were not (60%). Majority (67%) clearly specified the medical status of the patients but 33% did not.

Area of interest was not specified in 69% of cases and clinicians' names were not stated in 94% of the cases. Majority of the forms were completed with clinicians' signature (99%) and also radiographers' details (97%). Example of an internal referral form is shown in Figure 5.

**LIMITATIONS**

Some forms were not able to be traced, especially in the early days of CBCT scanning. Hence for standardization, we had to disregard those scans. There were also issues with redundant forms. Some external referral forms had been duplicated with the internal forms. In this case, only one form

(primary source) was selected to portray the true number of the cases. Some cases also came with multiple clinical presentations stated as of why CBCT scans were taken. The most significant indication was chosen in such cases.

**DISCUSSION**

Based on the results, generally, the number of CBCT scans taken in Radiology Unit, Dental Faculty, IIUM has been greatly increased within the study period of 4 years. This unit received CBCT referral from both IIUM internal clinics and external sources, mainly Ministry of Health dental clinics and hospitals in eastern area of Pahang (HTAA, HOSHAS and Paya Besar Dental Clinic).

Analysis of the forms showed that the external referral forms were filled with all necessary information. This, however, was not the case for internal referral forms. The internal form was deemed to be lacking, as there was no room for clinical details and justification to be penned.

Important information such as patients' details, medical history and pregnancy status should be distinctly filled and written. The clinician's name, signature and stamp must be placed in every request form. This is aimed not only for good record and easy tracing should any problem arise, but most essentially to safeguard patients and to avoid unnecessary exposure.<sup>10,11,12</sup>

Clinicians must validate each exposure as CBCT scan has higher radiation dose compared to plain radiographs. In accordance to European

Full Name : [REDACTED]  
 Mykad/Mykid/P [REDACTED]  
 Age : \_\_\_\_\_ D.O.B : \_\_\_\_\_ Sex: F / M  
 Address : \_\_\_\_\_  
 \_\_\_\_\_  
 Contact No. : [REDACTED]  
 Pregnancy status (Female patient): Yes / No

**Type of X-ray**

<input checked="" type="checkbox"/>	Orthopantomograph (OPG)
<input type="checkbox"/>	Lateral Cephalometric
<input type="checkbox"/>	Temporomandibular Joint (TMJ)
<input checked="" type="checkbox"/>	Cone Beam Computed Tomography (CBCT)
<input type="checkbox"/>	Cone Beam Volumetric Tomography (CBVT- 3D )
<input type="checkbox"/>	Others :

**Indications:** \_\_\_\_\_

**Medical History:**

Clear [REDACTED]

\*Tick (✓) where appropriate

Radiographer In-charge [REDACTED]

Date/Time : 28/12/12 10:21 am

**Doctor/Signature:** [Signature] **Student/Signature:** \_\_\_\_\_

**Date:** \_\_\_\_\_ **Date:** \_\_\_\_\_

Figure 5: Example of an internal referral form.

Guideline: Radiation Protection No 172 and Ionising Radiation (Medical Exposure) Regulations 2000 (IRMER), scans can only be taken after comprehensive history and clinical examination were performed. A clinical justification is required prior to CBCT scan, to portray that the benefits outweigh the risks.<sup>11</sup> For this very reason, the justification in the request form must be penned evidently and the radiographer has the right to enquire more information from the clinician, should they have any doubt over the request. There

is also possible medico-legal repercussion to this.<sup>10,12,13</sup> The radiographer may be allowed not to perform CBCT scan when receiving incomplete form. Effort must also be in place to ensure that there is no redundant form or overlapping request.

Periodical additional training should be provided to Dentists/Radiographers accountable for CBCT amenities to ensure quality assurance. The design and delivery of CBCT training programmes should also involve Dental and Maxillofacial radiologists.<sup>11</sup>



Workstation: RAD  
 Version: 5  
 Revision: 1  
 Effective Date: 1<sup>st</sup> Jan 2015

**Kulliyyah of Dentistry  
 International Islamic University Malaysia  
 RADIOGRAPH REQUEST FORM**

<b>Name:</b>			
<b>Mykad / Passport/ Mykid No:</b>		<b>Gender:</b> <input type="checkbox"/> Male <input type="checkbox"/> Female	
<b>Address:</b>			
<b>Clinical Registration No:</b>		<b>DOB:</b>	<b>Age:</b>
<b>Phone No:</b>			
<b>Particulars for dental students ( compulsory to fill in)</b>			
<b>Clinic:</b>	<b>Doctor Supervise:</b>	<b>Dental Student:</b>	
<b>Date:</b>	<b>Time of procedure:</b>	<b>Clinical Year:</b>	
<b>Allergies:</b>			
<b>Any risk factor?</b>	<input type="checkbox"/> Yes <input type="checkbox"/> No	If any, please state:	
<b>Pregnancy Status (for female patients only)</b>	<input type="checkbox"/> Yes <input type="checkbox"/> No	Last Menstrual Period (LMP):	
<b>Method of Transport ( to the Imaging room)</b>	<input type="checkbox"/> Walking <input type="checkbox"/> Wheel Chair	<input type="checkbox"/> On Trolley	Accompanied: <input type="checkbox"/> Yes <input type="checkbox"/> No
<b>RADIOGRAPHIC PROCEDURES:-</b>			
<b>INTRAORAL:</b>			
<input type="checkbox"/> Periapical (tooth): _____			
<input type="checkbox"/> Bitewing: _____			
<input type="checkbox"/> Occlusal: _____			
<b>EXTRAORAL:</b>			
<input type="checkbox"/> Orthopantomograph (OPG).			
<input type="checkbox"/> Lateral Cephalometric.			
<input type="checkbox"/> Temporomandibular joints (TMJ); please state details: _____			
<input type="checkbox"/> Cone Beam Computed Tomography / Volumetric (CBCT /CBVT); please state details: _____			
<input type="checkbox"/> Others (Please state details): _____			



<b>Clinical Details:</b>                <div style="text-align: right; margin-top: 10px;"> <i>(Clinician's name, signature,</i>  <i>stamp &amp; date)</i> </div>			
<b>Radiographer</b>	Name:	Date:	Time:

Figure 6. Newly implemented internal referral form.

From this audit, a few recommendations can be drawn:

- 1) A standardized format and more comprehensive local referral CBCT form should be established.
- 2) Strict standard of procedures should be meticulously adhered to and radiographer should only accept complete forms including clear indication and justification for a CBCT scan.

A new referral form has been drafted as shown in Figure 6. After further discussion with the clinical management and additional amendment, this new internal referral form is now being used in Dental Faculty, IIUM, effective from 1st January 2015. A follow-up audit should be organized in future to assess the efficacy and completeness of this new form.

**CONCLUSIONS**

This study showed the majority of IIUM CBCT referrals were from internal sources and were not completely filled. Therefore a thorough revision to improve the current format of the internal form should be considered. A stricter referral framework should also be in place.

**REFERENCES**

1. C.H. Kau, S.Richmond (2005) Current products and practice, three dimensional CBCT in orthodontics. Journal of Orthodontics, 32: 282-293.

2. S.J Merrett, N.A Drage, P Durning (2009) Cone beam computed tomography: A useful tool in orthodontic diagnosis and treatment planning. Journal of Orthodontics, 36: 202-210.

3. I.H.Nasr, M.Sayers, (2011) Selection criteria for cone beam computed tomography in orthodontics: An Audit. The British Orthodontic Society Clinical Effectiveness Bulletin, 26: 12-13.

4. J Mah, R Enciso, M Jorgensen (2003) Management of impacted cuspids using 3D volumetric imaging. Journal of the California Dental Association, 31: 825-841.

5. K Tsiklakis, K Syriopoulos, H.C Stamakis (2004) Radiographic examination of the temporomandibular joint using cone beam tomography. Dentomaxillofacial Radiology, 33: 196-201.

6. G.R Swennen, W Mollemans, F Schutyser (October 2009) Journal of Oral and Maxillofacial Surgery, 67: 2080-2092.

7. C.A Aboudara, D Hatcher, I.L Nielson, A Miller (2003) A three-dimensional evaluation of the upper airway in adolescents. Orthodontics and Craniofacial Research, 6: 173-175.

8. D.C Hatcher, C Dial, C Mayorga (2003) Cone Beam CT for surgical assessment of implant sites. Journal of the California Dental Association, 31: 825-833.

9. Y Hamada, T Kondoh, K Noguchi et al (2005) Application of limited cone beam computed tomography to clinical assessment of alveolar bone grafting: A Preliminary Report. The Cleft Palate-Craniofacial Journal, 42: 128-137.



10. K.G Issacson, A.R Thom, K.Horner, E.Whaites (2009) Orthodontic Radiographs: Guidelines 3rd Edition. British Dental Journal, 206: 182.
11. Guidelines on CBCT for Dental and Maxillofacial Radiology, European Guideline: Radiation Protection, 172.
12. S. F. S. Halpin (2009) "Medico-legal claims against English radiologists: 1995–2006," British Journal of Radiology, 82(984): 982–988.
13. Guideline on Radiation Safety in Dentistry, Second Edition (2010) Malaysian Dental Council.

**Corresponding Author:**

Assistant Professor Dr Noraini Abu Bakar  
Department of Orthodontics,  
Dental Faculty, International Islamic University  
Malaysia,  
Kuantan Campus,  
25200 Kuantan, Pahang.  
Tel: +6012-714 0094  
Email: [nor\\_aini@iium.edu.my](mailto:nor_aini@iium.edu.my)