



Amyand's Hernia in Neonate: A Case Report

Norhafiza AR¹, Gunasekar S², Alia Maisyah AL²

¹*Department of Surgery, Kuliyyah of Medicine, International Islamic University Malaysia, Kuantan, Pahang, Malaysia*

²*Department of Surgery, Hospital Tengku Ampuan Afzan, Kuantan, Pahang, Malaysia*

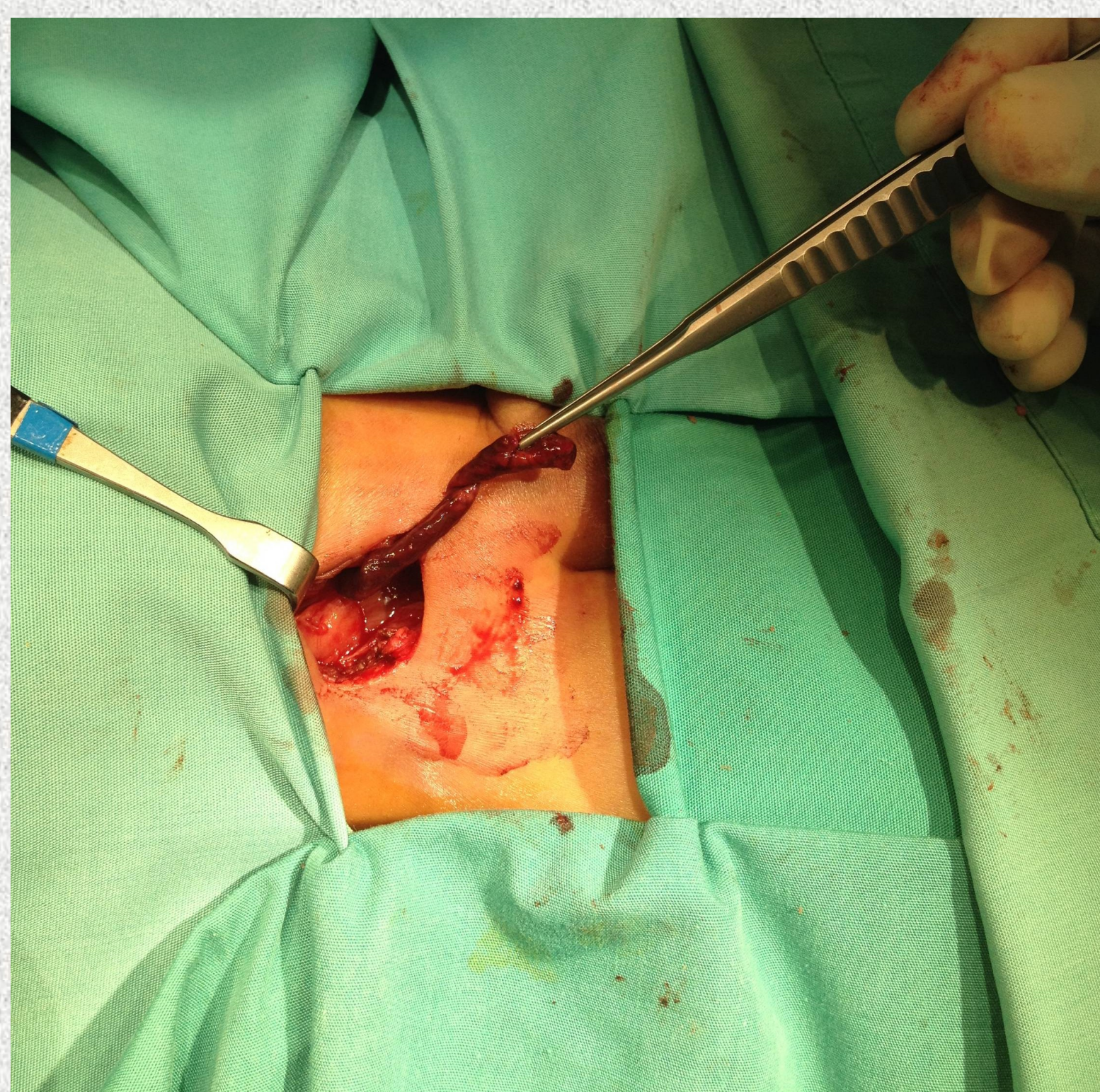


INTRODUCTION

Hernia is a medical condition in which there is a defect in the abdominal wall that lead to protrusion of abdominal content. Hernia sac usually contains omentum and bowel. Unusual contents of hernia sac include bladder, Meckel's diverticulum and appendix or commonly known as Amyand's hernia¹ as in this case, in honour of Claudius Amyand, the first surgeon who described the condition. Appendix in Amyand's hernia can either be normal, inflammed or perforated². It is a rare condition that can happen to both adults and children. The incidence of having an appendix in the hernia sac is about 1% and only 0.1% of all cases of appendicitis present as Amyand's hernia³. The commonest presenting complaint for patients with such condition is painful inguinal or inguino-scrotal swelling. It was observed in about 80% of patients⁴ that often lead to pre-operative diagnosis of obstructed or strangulated inguinal hernia. We are presenting a case of a day 8 of life baby boy who presented with sudden onset of right inguinal swelling. The definite diagnosis of Amyand's hernia with gangrenous appendix was only made intra-operatively for this case.

CASE DESCRIPTION

A full term, day 8 of life baby boy who was otherwise healthy with no known comorbid was brought in to casualty Hospital Tengku Ampuan Afzan (HTAA) for sudden onset of swelling over right inguinal region on the day of admission, noted by the mother. It was associated with one episode of vomiting but he was still able to pass motion. There was no abdominal distension but the child was irritable and refused feeding. Clinical examination revealed an irritable child with good hydration. Abdomen was soft, not distended with no features of peritonism but there was an irreducible, tender right inguinal swelling noted. Abdominal x-ray did not show any dilated bowel. He was then posted as strangulated right inguinal hernia for emergency herniotomy. Intra-operatively, the hernia sac was found to have gangrenous appendix and twisted at the base. 5 ml of pus evacuated. Caecum was found at the superficial inguinal ring and healthy. Open right herniotomy and appendicectomy were done and surgery was otherwise uneventful. He was then transferred to Neonatal Intensive Care Unit (NICU) for post-operative care.



Picture 1

Intra-operative finding of gangrenous appendix inside the hernia sac approached via right inguinal incision. Caecum is visible at the base of the appendix and otherwise healthy

DISCUSSION

Amyand's hernia is a rare entity, even so in children and neonates. When it occurred, the presentation is often misleading that lead to impression of obstructed or strangulated inguinal hernia in majority of patients⁴. Often, appendix is only found to be in the hernia sac intra-operatively and the correct diagnosis is only made after the hernia sac being opened. The pathophysiology of Amyand's hernia is unknown. However, inflammation of the appendix in cases of Amyand's hernia is attributed by the external compression of the appendix at the neck of hernia⁵. In general, clinical presentation can be varies with some patients can even present with septic shock and peritonitis, depending on the extent of inflammation in the hernia sac and the presence or absence of peritoneal contamination⁶.

Many authors recommended that the surgical approach to be depending on the inflammatory status of the appendix. Acute or perforated appendicitis warrant appendicectomy (via hernia sac) and herniotomy² but normal appendix should be left alone without appendicectomy⁴. The decision, however varies between individuals and the decision should always be made based on multifactorial including including location and length of the appendix⁵.

CONCLUSION

Surgeons operating in hernia should always be prepared of unusual contents of hernia sac such as appendix in cases of Amyand's hernia thus the appropriate management can be made. The decision to proceed with herniotomy with or without appendicectomy is often multifactorial² and appropriate individualized approach is always advocated.

REFERENCES

- ¹Syed M. Ali, Kamran A. Malik, Hani Al-Qadhi. Amyand's hernia: Study of four cases and literature review. Sultan Qaboos University Medical Journal. May 2012; 12(2): 232–236
- ²Cankorkmaz L *et al.* Amyand's hernia in the children: A single center experience. Surgery. 2010 Jan;147(1):140-3. doi: 10.1016/j.surg.2009.09.038. Epub 2009 Nov 11
- ³Logan MT, Nottingham JM. Amyand's hernia: A case report of an incarcerated and perforated appendix within an inguinal hernia and review of the literature. The American Journal of Surgery. 2001; 67, 628-629
- ⁴Sharma H *et al.* Amyand's hernia: a report of 18 consecutive patients over a 15 year period. Hernia. 2007; 11:31–5
- ⁵Kyriakos P *et al.* Amyand's hernia: A vermiform appendix presenting in an inguinal hernia: A case series. Journal of Medical Case Reports. 2011; 5:463