



# Placenta Cretas: Early diagnosis is needed

Hamizah I<sup>1</sup> ,Zalina N<sup>1</sup> ,Chou MM<sup>2</sup> ,RoZIAH I<sup>3</sup> ,Azrul MS<sup>3</sup> .

1. Department of O&G, Kulliyah of Medicine, International Islamic University of Malaysia
2. Taichung Veteran General Hospital, Taichung, Taiwan
3. Hospital Tengku Ampuan Afzan, Pahang, Department of Forensic Medicine, Hospital Tengku Ampuan Afzan Pahang.

# Abstract

*Incidence of placenta cretas increased in women who had previous caesarean or previous procedures for termination of pregnancy. The diagnosis of this emergency situation is often made at time of caesarean which could lead to increase maternal morbidity or even mortality. Placenta cretas had been reported to cause uterine rupture in early pregnancy. The availability of conventional 2D grayscale, color Doppler or the 3D power Doppler has changed the trend of time of the diagnosis made ie from at time of caesarean to as early as first trimester. These would give the advantage in anticipating and preventing complications. We demonstrate two cases of placenta increta one diagnosed at autopsy whereby presented as acute abdomen at 15 weeks of pregnancy and the other was diagnosed at 14 weeks by all the above ultrasound techniques.*

**First case:** *A 35 year old G6 with previous one caesarean for her first pregnancy and two dilatation and curettage (D&C) procedures during her fourth and fifth pregnancies. At 15 weeks of pregnancy, she was brought to the emergency department for an acute abdomen following sexual intercourse. However her condition deteriorated to asystole. At autopsy there was a ruptured uterus over the uterine lateral-fundal measured 8 x 4.5 cm exposing sac of fetus. The histopathology was reported as placenta increta.*

**Second case:** *A 33 year old G4 with two normal vaginal deliveries and a D&C for missed miscarriage during the third pregnancy. She first presented at 14 weeks for routine antenatal visit. 3D Power Doppler showed increased periplacental vascularity highly suggestive of morbidly adherent placenta. She was followed and had caesarean hysterectomy at 36 weeks with histopathology of placenta increta.*

**Conclusion:** *Placenta cretas may lead to ruptured uterus and maternal mortality even in early pregnancy. In early pregnancy, prenatal diagnosis by ultrasound techniques is possible. Women with risk factors of placenta cretas need further ultrasound evaluation at the earliest stage of pregnancy.*

# Introduction – Placenta cretas

- Incidence is increasing due to dramatic rise in caesarean section.
  - 1930-1950      1:30,000 deliveries
  - 1980            1: 2,500 deliveries
  - 1982 – 2002      1: 533 deliveries
- The changing trend for diagnosis
  - Time of diagnosis have changed from during caesarean → prenatal diagnosis
  - Modality of Ultrasound diagnosis
    - Use of 2D → color Doppler → 3D power Doppler
- Earliest case reported at 5 weeks gestation,
  - implanted near internal os – caesarean scar pregnancy
  - subtotal hysterectomy at 37 weeks – anterior placenta praevia/accreta

Wu 2005  
Chou MM 2009  
Shih JC, 2009  
Ben, 2005

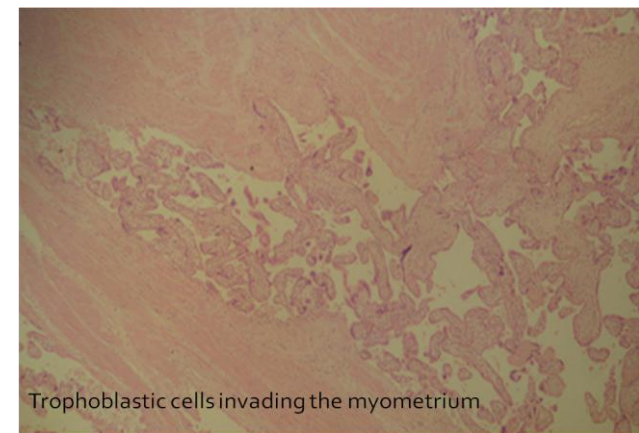
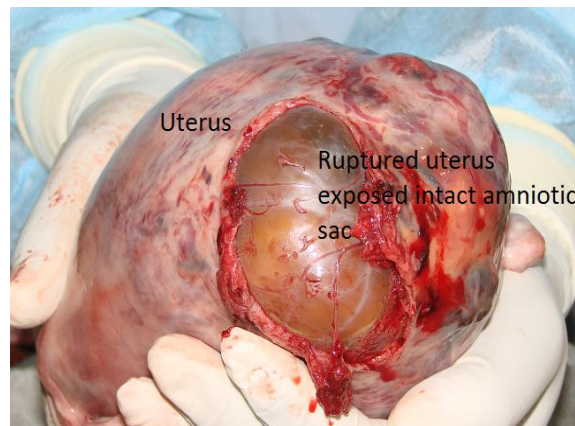
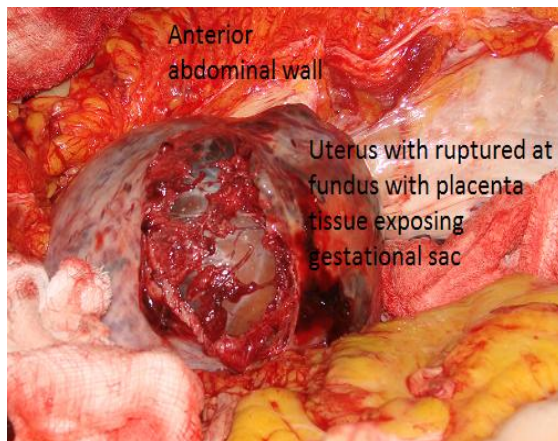
# Case 1

38 year-old G6 at 15 weeks POA, first delivery was caesarean for breech followed by two vaginal deliveries from her first husband. Her last two pregnancies from second husband ended with miscarriages whereby dilatation and curettage performed. She presented to the nearest clinic for sudden epigastric pain radiated to her back immediately following sexual intercourse. Her BP was 110/60 mmHg, PR of 100/min, T° of 37°C, RR of 26/min and SpO<sub>2</sub> 100%. She was given intravenous ranitidine, fluid and immediately transferred to tertiary hospital.

On arrival to tertiary hospital, she was gasping, pale, Glasgow coma scale of 5/15, her BP was 49/20mmHg, pulse rate of 138, T= 35°C and both pupils were 4mm fixed. She was immediately intubated. She went into cardio respiratory arrest soon after. A quick ultrasound of abdomen revealed no free fluid and no evidence of aortic aneurysm. She was referred to medical, surgical and obstetrics team. Her abdominal girth was noted to be increasing in size. Abdominal and pelvic ultrasound showed evidence of free fluid with an intrauterine pregnancy of a nonviable fetus. A peritoneal tap confirmed haemoperitoneum. Her haemoglobin dropped from 8.2 to 2.5g %, and platelet of 385 to 81 x 10<sup>3</sup>/mm<sup>3</sup>. She went into second asystole and succumbed.

## Autopsy

Haemoperitoneum of 2000mls of fresh blood mixed with clots. Ruptured of uterus at the fundus measured 8 x 5 cm exposed the fetal sac with the fetus (225gm) still inside the uterus. The caesarean scar was intact. Histopathology confirmed **placenta increta**.



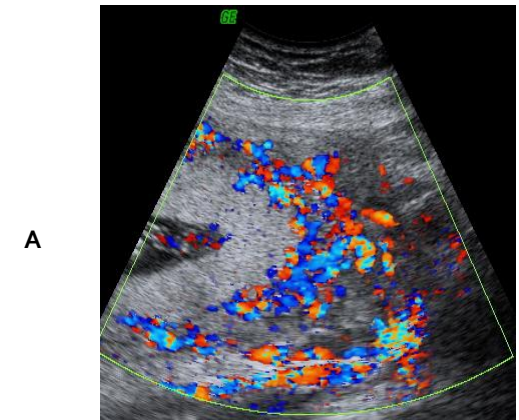
5

# Case 2

- A 33 year old G<sub>4</sub>P<sub>2</sub>A<sub>1</sub> with previous obstetrics history two SVD and one miscarried at 10 weeks POA 3 years ago which required D&C.
- First presented at 14 weeks for routine antenatal visit.

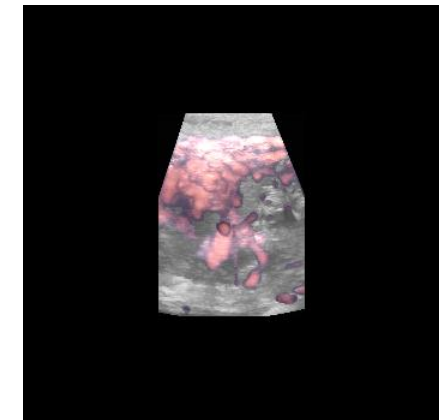
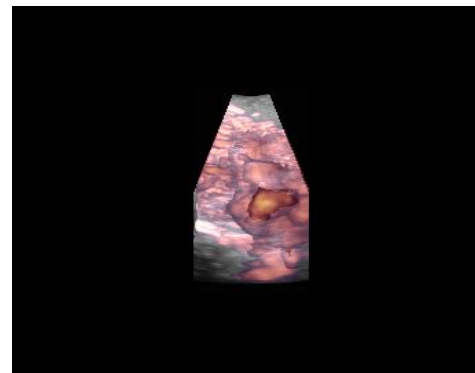
## ***Routine first trimester ultrasound showed (fig A)***

- Low lying placenta
- Increased periplacental vascularity – increased suspicion of placenta cretas
- She remained asymptomatic
- At 30 weeks dexamethasone was administered
- She was managed in other tertiary hospitals due to logistic problem
- She was hospitalized from 32 weeks POG
- Elective Caesarean performed at 36 completed weeks revealed;
  - Prominent vessels at right lower segment
  - Healthy baby boy
- Proceed with caesarean hysterectomy as placenta could not be separated
- Blood loss of 2liters



## **3D power Doppler spatial uteroplacental angioarchitecture**

- A. Normal placenta at 14 weeks
- B. Increased periplacental vascularity

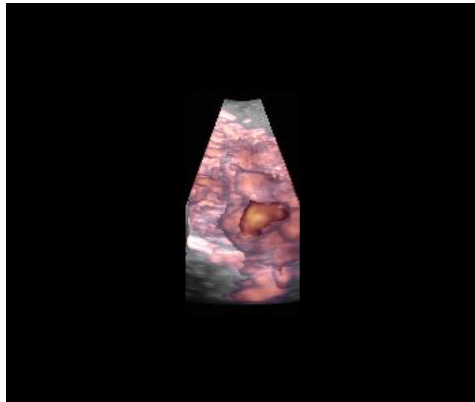


[Click image for cine view](#)

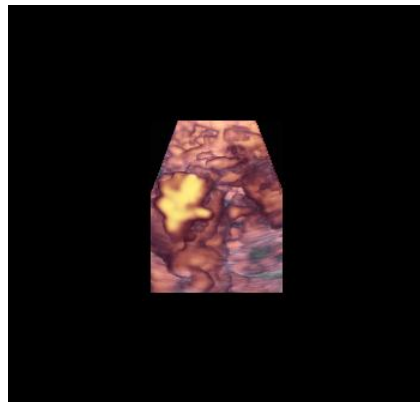
# Case 2

3D power Doppler spatial uteroplacental angioarchitecture (Note the increased periplacental vascularity especially on the right )

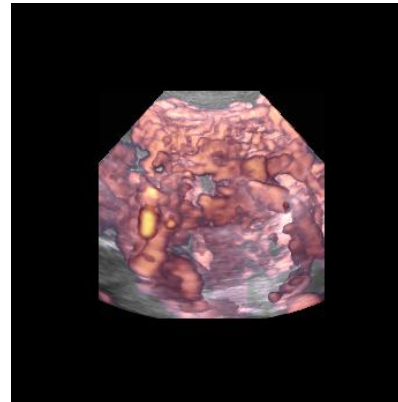
[Click image for cine view](#)



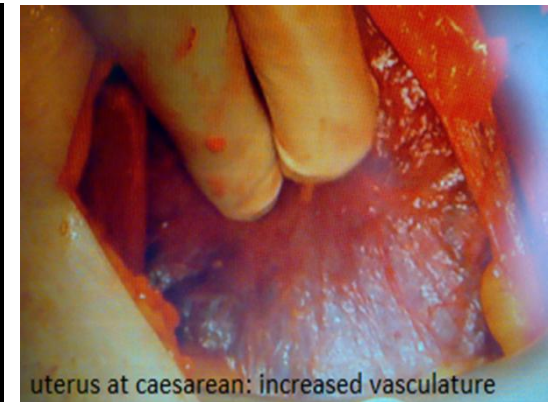
14 weeks POG



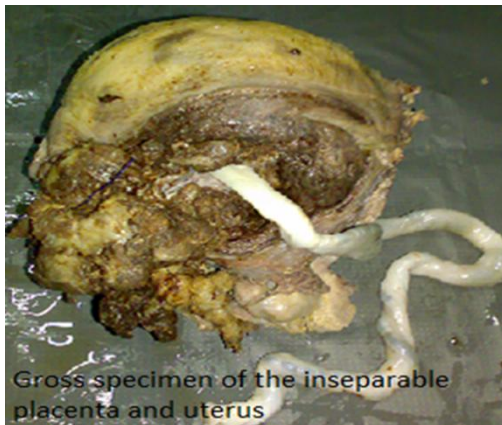22 weeks POG



30 weeks POG



uterus at caesarean: increased vascularity

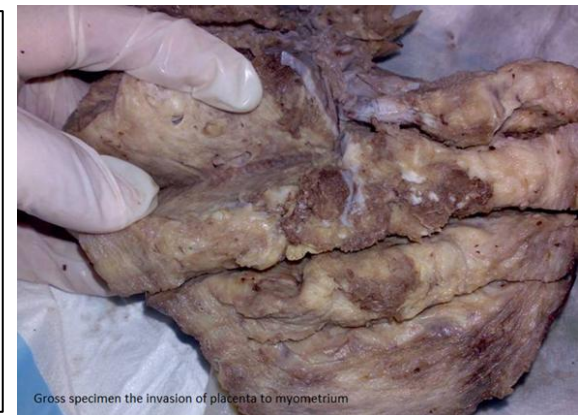

Gross specimen of the inseparable placenta and uterus

## Histopathology Report:

Sections of the uterus show areas of mature chorionic villi infiltrating into part of the myometrium without intervening decidua. The fetal and maternal vessels are unremarkable. No villitis or chorioamnionitis seen. The umbilical cord shows presence of two arteries and one vein. Acute on chronic inflammatory cells are seen infiltrating the cervix. A few Nabothian cysts are present. Both fallopian tubes are unremarkable.

Diagnosis: uterus, consistent with **placenta increta**



Gross specimen the invasion of placenta to myometrium

# Conclusion and References

- With the
  - increasing trend of caesarean and termination of pregnancy
  - known morbidity and mortality caused by placenta cretas
  - enhancement of ultrasound imaging technology
  - current concept of inverse antenatal pyramid
- Therefore screening and diagnosis of placenta cretas during early trimesters is
  - possible
  - recommended in high risk cases
  - crucial to reduced maternal morbidity and mortality
- Chou, M.M., et al, Prenatal diagnosis of placenta previa accreta by transabdominal color Doppler ultrasound. *Ultrasound Obstetrics Gynecol*, 2000. 15: 28-35
- Honig, A., et al., Placenta percreta with subsequent uterine rupture at 15 weeks of gestation after two previous cesarean sections. *Journal of Obstetrics & Gynaecology Research*, 2005. 31(5): p. 439-443.
- Shih J.C., et al, Role of three-dimensional power Doppler in the antenatal diagnosis of placenta accreta: comparison with gray-scale and color Doppler techniques. *Ultrasound Obstet Gynecol*, 2009,33:193-203
- Chou, M.M., et al, Prenatal Detection of Bladder Wall Involvement in Invasive Placentation with Sequential Two-Dimensional and Adjunctive Three-Dimensional Ultrasonography, *Taiwan J Obstet Gynecol*, March 2009. Vol 48. No 1. 398-45