

The Effect of Aqueous Olive Leaves Extract on the Pancreatic Islets of Streptozotocin Induced Diabetes Mellitus in Mice

Sanarya T¹, Al-Badri¹, Imad M. Al-Ani^{2*}, Karim A. Al-Jashamy³

¹ Department of Biology, College of Science, Al-Mustansiriyah University, Baghdad, Iraq

² Department of basic Medical Science, Kulliyah of Medicine, International Islamic University Malaysia, Kuantan, Pahang, Malaysia

³ Medical School SEGi University College, Kuala Lumpur, Malaysia

*Correspondence author: E-mail : imad_alani@yahoo.com, Contact Number: 0060179776014

ABSTRACT

The objectives of this study were to investigate the effects of the aqueous crude extract of *Olea europaea* on serum glucose level and histopathological changes in islets of Langerhans in an induced-diabetic mellitus in mice. The experimental recommended 60 male mice were divided into three groups contained 20 mice each. The first group was the control and they were given normal saline pH 7.0. The second group was intraperitoneally injected by a dose of 100mg/Kg of STZ and 10% glucose instead of normal drinking water over the 24 hours followed the treatment. The third group was injected intraperitoneally with 100mg/kg STZ and orally given 0.33g/ Kg aqueous extract of olive leaves everyday for four weeks. Blood specimens were collected, and the serum separated and stored at 4°C until it is used. The animals were dissected and the pancreatic tissues were obtained, the tissue specimens were fixed in the Boun's solution for 24 hr, and processed for histological studies. There was a significant increase in blood glucose level of the STZ- diabetic mice by the first week of injection with STZ in comparison with control group. A significant decrease in blood glucose level occurred in the STZ-diabetic group treated with *Olea europaea* aqueous extract. Islets of langerhans are hypertrophied in the STZ-diabetic group and this hypertrophy showed a significant increased in the average of islets size at the last week, while the treatment with *Olea europaea* aqueous extract showed a reduction of the islet size compared with the islets of the STZ –diabetic Mice

Keywords: Olive leaves; streptozotocin; diabetes mellitus

INTRODUCTION

Diabetes mellitus (DM) is a chronic disease caused by inherited and/or acquired deficiency in production of insulin by the pancreas, such a deficiency results in increased concentrations of blood glucose level (Sexton and Jarow 1997). It is a complex and multifarious group of disorders characterized by hyperglycemia that has reached epidemic proportions in the present century (Noor, et al 2008). The therapeutic measurements include use of insulin, analogues, and alpha glycosidase inhibitors like acarbose, miglitol, sulphonylureas and biguanides for the treatment of hyperglycemia. These drugs also have certain adverse effects like causing hypoglycemia at higher doses, liver problems, lactic acidosis and diarrhea (Yki-Jarvinen, 1994). Currently, many herbal medicines therapeutic available been recommended for the treatment of diabetes. Herbal drugs are prescribed widely because of their effectiveness, less side effects and relatively low cost (Venkatesh *et al.*, 2003). Olive mill waste (OMW) biophenols are efficient components for the low incidence of cardiovascular diseases in the Mediterranean area. Olive mill waste is potentially a rich source of a diverse range of biophenols with a wide array of biological activities (Obeid *et al.*, 2005). The beneficial health effects of OMW have been mainly attributed to its elevated phenols content (Casalino *et al.*, 2002). Among them, hydroxytyrosol (3,4-dihydroxyphenylethanol) stands out as a compound of high added-value, due to its interesting antioxidant and potential beneficial human health properties (Dudley *et al.*, 2008; Hamden *et al.* 2009). Preventing human erythrocytes from oxidative damage induced by hydrogen peroxide (Zhang *et al.*, 2008), anti-inflammatory, antithrombotic, and hypocholesterolemic effects in rats (Visioli *et al.*, 1998; Covas *et al.*, 2006). Streptozotocin (STZ) is a N-nitroso-n-methylurea derivative of 2-deoxy-d-glucose, produced by *Streptomyces acromogenes*, and has been shown in animal's model to induce a chronic diabetic state

by destruction of β cells of the pancreatic islets (Hardman and Limbird 2001). Streptozotocin induced diabetes mellitus in many animal species has been reported to resemble human hyperglycemic diabetes mellitus (Weir, et al 1981). It has been reported that STZ selectively damages pancreatic β -cells and produces much less toxic side effect than other chemical diabetogenic agents (Junod, *et al.* 1969) and induces diabetes similar to poorly treated human diabetes, it develops many features seen in human patients (Shafir, 1996).

The objectives of this study were to investigate the effects of the aqueous crude extract of *Olea europaea* on serum glucose level and histopathological changes in islets of langerhans in STZ- induced-diabetic mellitus in mice.

MATERIALS AND METHODS

Animals Used

Male Swiss albino mice (2.5-3) months of age and (20-25) gm of the balb/c strain were used in this study, the mice were in good health and they bred in the animals' house of Al-Mustansiriah College of science and kept in the plastic cages. The animals were kept at room temperature between (20-24°C). The mice received pellets and allowed free access of water *ad libitum*.

Olea europaea Leaves

Leaves of *Olea europaea* were collected from the science college gardens of Al-Mustansiriah University in summer, the leaves were cleaned and washed with distilled water and dried at room temperature of 25°C in the laboratory, the dried leaves were powdered in an electrical grinder and the powder was kept in plastic bags until used.

Preparation of the Aqueous Extract and Streptozotocin

The aqueous extract of olive (AEO) was prepared by soaked 50gm of the powdered material in one liter of distal water and kept overnight in shaking incubator at room temperature. The extract was filtrated after 24 hours and the filtrate was evaporate at 40°C under reduced pressure in a rotary evaporator (Subramoniam *et al.*, 1996), and the aqueous reparation of the residue was kept in the refrigerator until used in the experiment. Fresh Streptozotocin (STZ) solution was prepared by dissolving 57.6 mg STZ in 3.6 ml citric acid buffer pH= 5.4 and injected to mice with single dose intraperitoneally (IP) immediately (Yuanfeng, 1998).

Experimental Design and Sampling

Sixty mice were divided into three groups of 20 mice each. The first group (C) was the control was given normal saline pH 7.0. The second group (G1) was injected with single dose IP of 100mg/kg of STZ and 10% glucose instead of normal drinking water over the 24 hours only followed the treatment. The third group (G2) "STZ-AEO" was treated with single dose IP of 100mg/kg STZ and orally AEO by a dose of 0.33g/kg everyday for four weeks. Animals were anaesthetized by diethyl ether after fasting for 13-16 hours, Five mice from each group were scarified on day 7, 14, 21 and 28 of the experimental. Blood samples were collected in plastic tubes and the serum was separated by centrifugation at the speed of 3000 rpm, collected in sterilized plastic tubes and store at 4°C until it is used. Pancreatic tissues were fixed in the Bouin's solution for 24 hr, dehydrated by series of ethanol, cleared in xylene and impregnated and embedded in paraffin wax. Paraffin sections of 5 μ m thickness were cut using rotary microtome and stained by Orange Fuchsin Green (OFG).

RESULTS

The fasting blood glucose levels showed a significant increased ($P \leq 0.05$) in STZ diabetic mice (178 \pm 18.99) mg/100ml compared to control group (125.75 \pm 5.32) mg /100 ml. While there

was a significant decline ($P \leq 0.05$) in blood glucose levels of the STZ diabetic mice treated with AEO (113.75 ± 7.93) mg/100ml compared to STZ diabetic mice at the end day of first week of experiment.

On day 14, there was no significant ($P \geq 0.05$) increase in fasting blood glucose levels of STZ diabetic mice (126.5 ± 3.11) compared to control groups (117.5 ± 7.55). Thereafter a significant decrement ($P \leq 0.01$) in blood sugar levels was after the administration of AEO in STZ diabetic group (92 ± 10.68) mg/100 ml compared to the control group (117.5 ± 7.55) mg/100ml. The blood glucose levels of the STZ diabetic mice treated with AEO showed significantly declined ($P \leq 0.05$) (92.2 ± 1.68) mg/100ml compared to the STZ diabetic mice (126.5 ± 3.11) mg/100ml.

On day 21, the blood glucose levels increased but were not significant ($P \geq 0.05$) in the STZ diabetic mice (137 ± 25.11) compared to the control group (117.5 ± 7.55) mg/100ml. A significant decrement ($P \leq 0.01$) in blood sugar levels in the STZ diabetic treated with AEO group (92 ± 8.64) mg/100 ml compared to the STZ group (137 ± 25.11) and ($P \leq 0.05$) to control group (117.5 ± 7.55) mg/100 ml.

At the end of the fourth week of the experiment, the blood glucose levels increased but with no significant ($P \geq 0.05$) in the STZ diabetic mice (135 ± 6.2) compared to the control group (118.5 ± 5.35) mg/100ml. A significant decrement ($P \leq 0.01$) in blood sugar levels in the STZ diabetic treated with AEO group (89 ± 9.1) mg/100 ml compared to the STZ group (137 ± 25.11) and ($P \leq 0.05$) to control group (118.5 ± 5.35) mg/100 ml (Fig. 1).

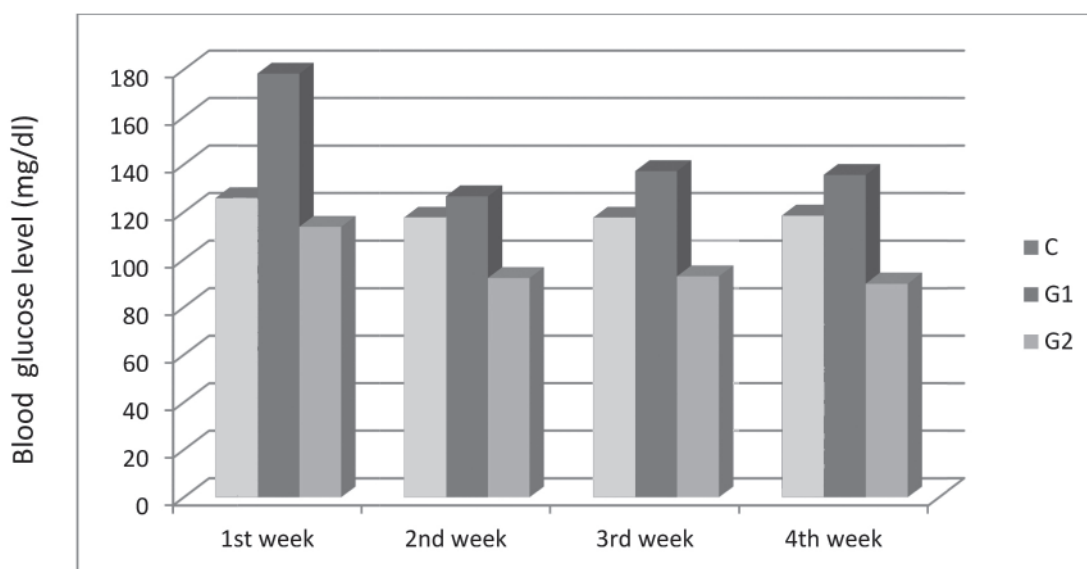


Fig. 1. The effect of aqueous olive leaves extract on blood glucose level in STZ-induced diabetic mice.

Histological Observations

On day 7 of the experiment, the pancreatic islets histopathology in STZ group showed variation in size and shape of islets cells and moderate β -cell degranulation (Fig. 2). The pancreatic islets in STZ-AEO and control groups showed normal structures with mild degranulation and congested blood vessels (Fig. 3). On day 14, the STZ group showed the regular of the pancreatic islets shape, hypertrophied cells, large nuclei and some islets appeared atrophied and showed exocrine- endocrine transformation with small thickening of the connective tissue. The STZ-AEO group showed normal pancreatic islets with regular shape similar to those of control group. On the day 21, the STZ group showed the hypertrophy of the pancreatic islets associated with infiltration of lymphocyte (insulinitis), also some signs of sclerosis, occlusion and hyalinization of

the intima in arterioles. Some islets showed lipid accumulation but those islets were rarely seen (Fig. 4). The islets of the STZ-AEO group showed irregularity in size, but they appeared normal with decreased granulation and some islets appeared atrophied & very small, few cells with large dilated blood vessels (Fig. 5). Animals of the control group showed normal structures during the stages of experiment (Fig. 6).

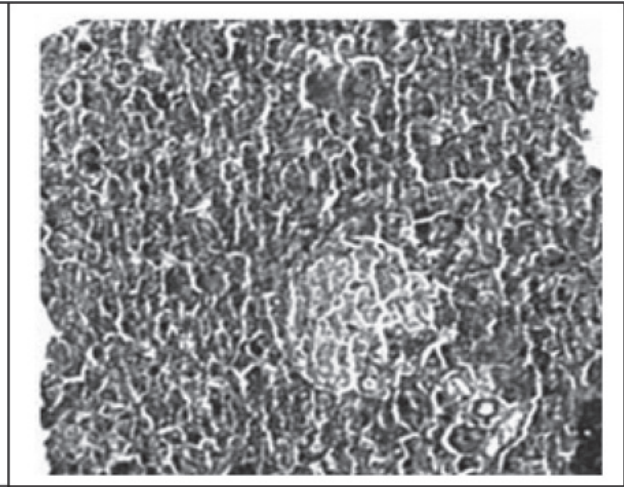
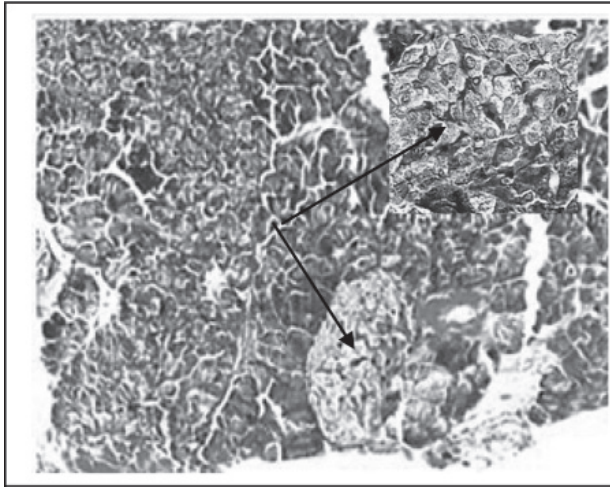


Fig. 2: Pancreatic islet of STZ diabetic mice on day 7, showing moderate beta cell degranulation (arrows), OFG X 330. Asterisk X 1320.

Fig. 3: Pancreatic islet treated with STZ and AEO on day 7, showing normal structures OFG X 330.

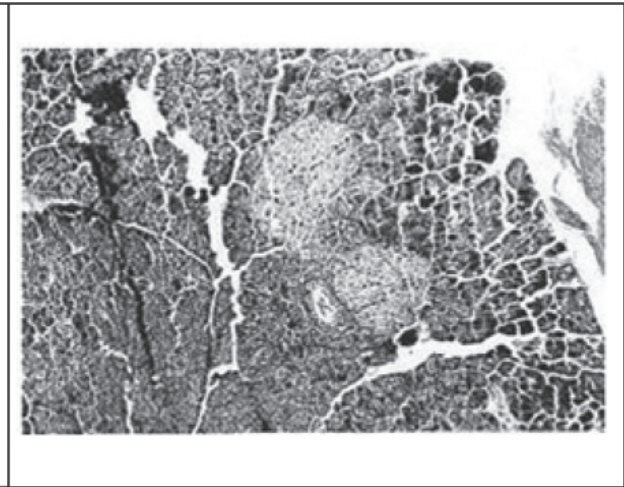
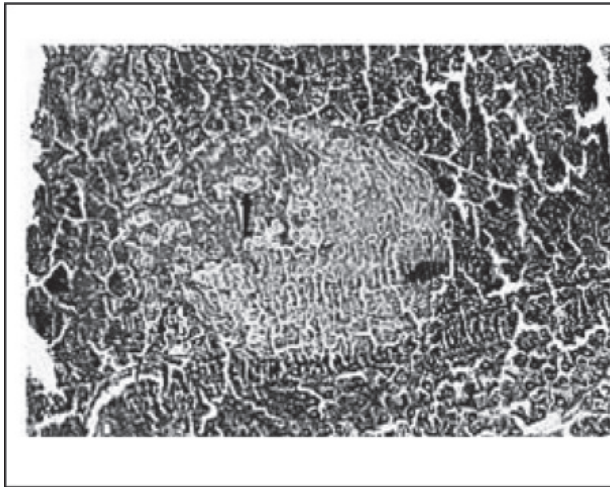


Fig. 4: Pancreatic islet of STZ diabetic mice on day 21, showing hypertrophy of beta (arrow). OFG X 330.

Fig. 5: Pancreatic islet treated with STZ and AEO on day 21, showing normal structures OFG X 330.

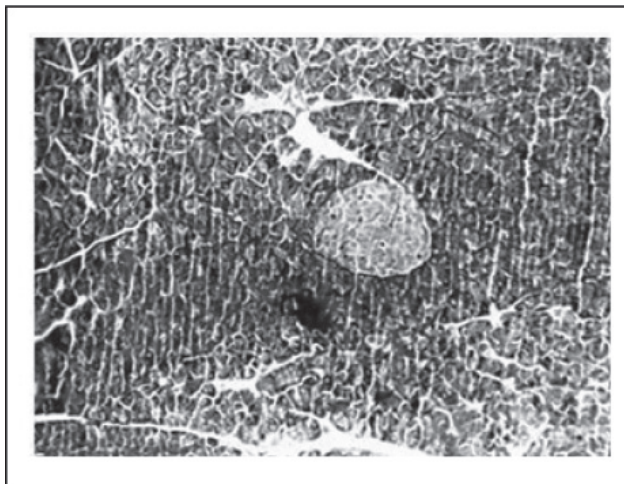


Fig. 6: Pancreatic islet treated with normal saline day 21, showing normal structures OFG X 330.

DISCUSSION

The present study illustrates the blood glucose lowering properties of the leaves of *Olea europaea* that focused onto the hypoglycemic property of this traditional plant. Streptozotocin causes massive reduction in insulin release, through the destruction of the beta-cells of the islets of Langerhans (Terazono et al., 1990). It is interesting to note that the aqueous extract of *Olea europaea* at the dose (0.35 g/kg) effectively prevented the increase in blood glucose levels. Since STZ induces diabetes by destroying β -cells, in the present study on AEO showed marked anti-hyperglycemic effect. It is important to notice the significant increase in blood glucose levels of the STZ diabetic mice and blood glucose levels of the STZ treated daily with aqueous extract animals showed a significant decrease compared to the STZ diabetic mice. This decrement was seen significantly on the second, third and fourth week. The results of this study reveal that a continuous administration of AEO for three weeks prevents elevation of the glucose level in blood. These results are in agreement with those of Cignarella *et al.* (1996) and Cardinal *et al.* (2001) since they showed that there was a significant decline in blood glucose levels on day 21 of the STZ diabetic rats daily treated with blue berry in Italy. The present study is in agreement with the hypoglycemic effect of the *Ziryphus spina*-Christi, is a plant used in Egyptian folk medicine, this plant reduced blood glucose levels in STZ diabetic rats (Glombitza *et al.*, 1994; Nesseem *et al.*, 2009).

The persistent hyperglycemia can be explained by the absence of insulin production in the destroyed B-cells. The significant increase in STZ diabetic animals compared to control animals agrees with the results that are similar to those obtained by (GruBner *et al.*, 1993). Although there was no scientific study of the antidiabetic property of AEO has been reported. The results of the present study showed similar agreements with the results obtained by Al-Shamaony et al. (1994) and Kumar *et al.*, (2009) who used the aqueous extract of *Artemisia herba alba* which is widely used in folk medicine at a dose of 0.39g/kg body weight for 2-4 weeks where found a significant reduction in blood glucose levels of the diabetic animals. This study reported a further reduction in blood glucose level at $p < 0.01$ during the treatment with plant extract for four weeks. The present work had indicated that the aqueous crude extract of AEO at the dose used, significantly reduced blood glucose level in STZ diabetic mice. It is still unclear by which mechanism does AEO produce its effect on blood glucose. It is possible that the plant may reverse the catabolic features of insulin deficiency, decreases the release of glucagon or increase that of insulin, stimulate directly glycolysis in peripheral tissues increase glucose removal form blood or reduce glucose absorption from the gastrointestinal tract.

During the first week, the STZ diabetic group showed β -cell degranulation, this might occurred as a rapid event following STZ administration which agrees with the study of (Arison

et al., 1967; Lengyel *et al.* 2007). β -cell degranulation is caused mostly by the deposition of glycogen, the presence of glycogen seems to be related to the height and duration of hyperglycemia. (Fraenkel *et al.*2008). While islets of the STZ- AEO group showed regular shape islets with less degranulation which means that not all islets or all β -cells are affected at the same rate, since small area of the islet showed almost normal picture. Eventually, islets of hyperglycemic mice were significantly altered with their overall size gradually increasing with the duration and severity of the hyperglycemia. By the end of second week, islets of the STZ diabetic animals showed hypertrophy with hyperplasia and this hypertrophy continued to the last week, those islets appeared regular in shape with hypertrophied cells and light nuclei and some islets appeared atrophied with dense nuclei compared to the control group. In a study of Juvenile diabetes Montanya *et al.*(2000) elucidated that islets appear hypertrophied, therefore they showed regularity in shape with hypertrophied cells and non regular shape nuclei, or appear with atrophy, which shows irregularity in shape with atrophied cells and dense nuclei, followed by small thickening of the connective tissue between cells, those islets were more active than hypertrophied islets, also Atkinson and Maclaren, (1999) indicated that those cells are similar to exocrine cells in islets of old obese mice. The STZ-AEO group islets showed normal shape similar to control islets. On the last week, STZ diabetic islets showed continuous hypertrophy and hyperplasia in islets of experimental animals and diabetic cases as sclerosis and insulinitis. Insulinitis is associated mostly with lymphocyte infiltration which has been noticed in chronic juvenile diabetes similar to those of Freyse *et. al.* (1982) and Pimentel *et al.*(2005). The increase in lymphocyte cells has been produced by a simple immune response which causes necrosis of islets or anti insulin serum injection, also small doses of the drug STZ (Swieten *et al.* 1991). The present study has illustrated for the first time the effect of AEO on the pancreatic islets and correlated changes observed to the levels of blood glucose. It is possible that AEO may have direct or indirect effect on insulin release; further radioimmunoassay studies are needed to elucidate the effect of AEO treatment of insulin and other hormones “related to glucose metabolism” secretion.

CONCLUSIONS

The AEO at dose of (0.35g /kg) leads to a mark reduction in blood glucose levels. Blood glucose levels of the STZ diabetic mice daily treated with AEO showed a significant declined ($P < 0.05$) on days 7, 14, 21 and 28 of experimental (92 ± 8.64) mg/ 100 ml compared to the STZ diabetic mice (137 ± 25.11) mg/100ml.

REFERENCES

- Al-Shamaony L. Al-Khazraji SM, Twaij HA. (1994) Hypoglycemic effect of *Artemisia herba alba*. II. Effect of a valuable extract on some blood parameters in diabetic animals. *J Ethnopharmacol.* 43:167-71.
- Arison RN, Ciaccio EI, Glitzer MS, Cassaro JA, Pruss. MP (1967). Light and electron microscopy of lesions in rats rendered diabetic with Streptozotocin. *Diabetes* 16:51-56.
- Atkinson MA, Maclaren NK (1994). The pathogenesis of insulin- dependent diabetes mellitus (review). *New Engl J Med* 331: 1428-1436.
- Cardinal JW, Geoffrey P, Margison, KJ, Mynett, AP, Donald P.C, Rhoderick HE (2001) Increased Susceptibility to Streptozotocin-Induced β -cell Apoptosis and Delayed Autoimmune Diabetes in Alkylpurine- DNA-*N*-Glycosylase-Deficient Mice. *Mol. Cell. Biol.* 21: 5605–5613.
- Casalino E, Calzaretto, GC, Sblano V, Landriscina, MF, Tecce C, (2002) Antioxidant effect of hydroxytyrosol (DPE) and Mn^{2+} in liver of cadmiumintoxicated rats. *Comp. Biochem. Phys.* 133: 625–632.
- Cignarella Andrea, Milena Nastasi, Elena Cavalli, Lina Puglisi.(1996). Novel Lipid-Lowering Properties of *Vaccinium Myrtillus* L. Leaves, A Traditional Antidiabetic Treatment, In Several

- Models Of Rat Dyslipidaemia: A Comparison With Ciprofibrate. Dec 1;84(5):311-22.
- Covas MI, De la Torre K., Farre-Albaladejo M (2006). Postprandial LDL phenolic content and LDL oxidation are modulated by olive oil phenolic compounds in humans, *Free Radical Biol. Med.* 40: 608–616.
- Dudley JI, Lekli I, Mukherjee S, Bertelli AA, Das DK (2008) Does white wine qualify for French paradox? Comparison of the cardioprotective effects of red and white wines and their constituents: resveratrol, tyrosol, and hydroxytyrosol, *J. Agric. Food Chem.* 56: 9362–9373.
- Fraenkel M, Ketzinel-Gilad M, Yafa A, Orit P, Melis K, Julien C, Marie-France B, Christophe M, Erol C, Nurit K and Gil L. (2008). mTOR Inhibition by Rapamycin Prevents Cell Adaptation to Hyperglycemia and Exacerbates the Metabolic State in Type 2 Diabetes. *Diabetes.* 57: 945-957.
- Freyre EJ, Hahn von Dorsche H, Fischer U (1982). Low dose streptozotocin diabetes after partial pancreatectomy in dogs. Histological findings in a new type of experimental diabetes. *Res Exp Med (Berl)* 189:141–152.
- Glombitza KW, Mahran GH, Mirhom YW, Michel KG, Motawi TK. (1994). Hypoglycemic and antihyperglycemic effects of *Zizyphus spina-christi* in rats. *Planta Med.* 60:244-247.
- GruBner R. Nakhleh R. GruBner A., Tomadze G, Diem p, Sutherland D (1993). Streptozotocin-induced diabetes mellitus in dogs. *Horm. Metabol. Res* 25: 199-203.
- Hamden K., Allouche N, Abdelfattah Elfeki MK. (2009). Hypoglycemic and antioxidant effects of phenolic extracts and purified hydroxytyrosol from olive mill waste in vitro and in rats. *Chemico-Biological Interactions* 180: 421–432.
- Hardman JG, and Limbird LE (2001): Goodman & Gilman's. The Pharmacological Basis of Therapeutics. 10th Ed. New York: McGraw-Hill, PP. 1399.
- Junod A. Lambert AE, Stauffacher W, Renold AE (1969). Diabetogenic Action of STZ. Relationship of Dose to metabolic Response. *J. Clin. Invest.* 48: 2129-2139
- Kumar V, Khanna, A. K. Khan M. M. , Singh R, Singh S, Chander R, Mahdi F, Saxena JK, Saxena S, Singh VS, Singh RS (2009) Hypoglycemic, lipid lowering and antioxidant activities in root extract of *Anthocephalus indicus* in alloxan induced diabetic rats. *Indian J. Clini. Biochem*, 24: 65-69.
- Lengyel C, László V, Tamás B, Norbert J, János M, Péter B, Erzsébet K, Réka S, Péter P. Nánási MT, Kecskeméti V, Papp JG, András V. (2007). Diabetes mellitus attenuates the repolarization reserve in mammalian heart. *Cardiovasc Res* 73: 512-520.
- Montanya E, Nacher V, Biarnés M, Soler J (2000). linear correlation between beta-cell mass and body weight throughout the lifespan in Lewis rats: role of beta-cell hyperplasia and hypertrophy. *Diabetes.* 49: 1341-1346.
- Nesseem DI, Michel CG, Sleem AA, El-Alfy TS (2009). Formulation and evaluation of antihyperglycemic leaf extracts of *Zizyphus spina-christi* (L.) Willd. *Pharmazie.* 64:104-109.
- Noor A, Gunasekaran S, Soosaihanickam A. Vijayalakshmi, MA (2008). Antidiabetic activity of Aloe vera and histology of organs in Streptozotocin induced diabetic rats. *Current Sci.* 94: 1070-1076.
- Obeid HK, Allen MS, Bedgood DR, Prenzied P, Drobards K, Stockmann R. (2005). Bioactivity and analysis of biophenols recovered from olive mill waste, *J. Agric. Food Chem.* 53: 823–837.
- Pimentel MA, Gómez CE, Delgado López M G, Jiménez VMI, Guerrero Díaz JF Hernández JP . (2005). An improved method of 90% pancreatectomy using a low dose of Streptozotocin at the pancreaticoduodenal artery results in a rapid diabetic stage in dogs. *Acta Diabetologica* 42: 153-355.
- Sexton WJ, Jarow JP (1997). Effect of diabetes mellitus upon the male reproductive function. *J Urology* 49: 508-515.
- Shafir E (1996). Animal Models of Diabetes in Pregnancy. *Diabetes Rev*, 4: 114-128

- Swieten Van JC, Van Den Hout JHW, Van Ketel BA, Hijdra A., Wokke JH, Van Gijn J. (1991). Periventricular Lesions In The White Matter On Magnetic Resonance Imaging In The Elderly. Brain, 114: 761-774..
- Subramoniam A, Pushpangadan P, Rajasekharan S, Evans DA, Latha PG, Valsaraj R. (1996). Effects of *Artemisia pollens wall* on blood glucose levels in normal and alloxan-induced diabetic rats. J Ethnopharmacol. 50:13-17.
- Terazono Y, Uchiyama M, Ide T, Watanabe H, Yonekura H, Yamamoto H, (1990). Expression of reg protein in rat regenerating islets and its co-localization with insulin in the Beta cell secretory granules. Diabetologia 33: 250-252.
- Venkatesh S, Reddy GD, Reddy BM, Ramesh M, Appa AV (2003). Antihyperglycemic activity of *Caralluma attenuata*. Fitoterapia, 74: 274-279.
- Visioli FG, Bellomo CG, (1998). Free radical-scavenging properties of olive oil polyphenols, Biochem. Biophys. Res. Commun. 247: 60–64.
- Weir GC, Clore ET, Zmachinski CJ Bonner-Weir S (1981): Islet secretion in a new experiment model for non-insulin dependent diabetes. Diabetes, 30, 590-595.
- Yki-Jarvinen H, (1994). Pathogenesis of non-insulin-dependent diabetes mellitus Lancet, 343: 91-95.
- Yuanfeng H, Yufei W, Lijuan W, Hong Z, Hongde Z, Baohua Z, Aifang Z, Yu l (1996). Effect of Nicotinimide on prevention and treatment of STZ-induced diabetes mellitus in rats. Chinese Med. J, 109: 819-822
- Zhang X, Jiang L, Geng C, Yoshimura H, Zhong L, (2008). Inhibition of acrylamide genotoxicity in human liver-derived HepG2 cells by the antioxidant hydroxytyrosol, Chem. Biol. Interact. 176: 173–178.