

Images In...

Disseminated histoplasmosis presenting with chronic ulcerative tongue lesions in a patient with diabetes

Mohamed Hadzri Hasmoni,¹ Azarisman Shah Mohd Shah,¹ Suhaimi Ayoub,² Lau Shin Hin,³ Mohd Amran Abd Rashid⁴

¹ Department of Internal Medicine, International Islamic University Malaysia, Kuantan, Malaysia

² Kuantan Medical Center, Kuantan, Malaysia

³ Department of Oral Pathology and Medicine, Institute for Medical Research, Kuala Lumpur, Malaysia

⁴ Department of Radiology, International Islamic University Malaysia, Kuantan, Malaysia

Correspondence to Azarisman Shah Mohd Shah, risman1973@hotmail

DESCRIPTION

We describe a case of chronic tongue ulceration with systemic symptoms in a patient with poorly controlled diabetes. A biopsy of a lesion from the posterior third of the tongue showed features typical of histoplasmosis (figure 1). A CT of the thorax and abdomen revealed a diffuse reticulonodular pattern bilaterally (figure 2A). The intra-abdominal organs were normal. A diagnosis of disseminated histoplasmosis was made. The patient was started on intravenous amphotericin B for 3 weeks followed by oral

itraconazole 100 mg twice a day for 1 month. A repeat CT thorax 6 weeks after antifungal treatment revealed resolution of the lesions (figure 2B).

Disseminated histoplasmosis refers to a process of severe fungus colonisation in the lungs and other organs and body sites.¹ The first ever case of disseminated histoplasmosis in a patient with diabetes living in a non-endemic area was reported in 1977.² Since the AIDS epidemic, disseminated histoplasmosis is more commonly seen. Chronic infection often presents with pancytopenia, hepatosplenomegaly,

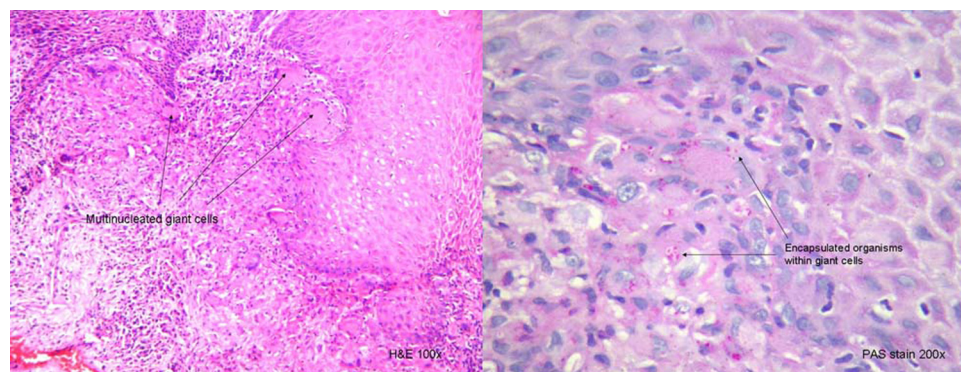


Figure 1 Tissue biopsy taken from the tongue lesion shows multinucleated giant cells containing encapsulated fungal organism.

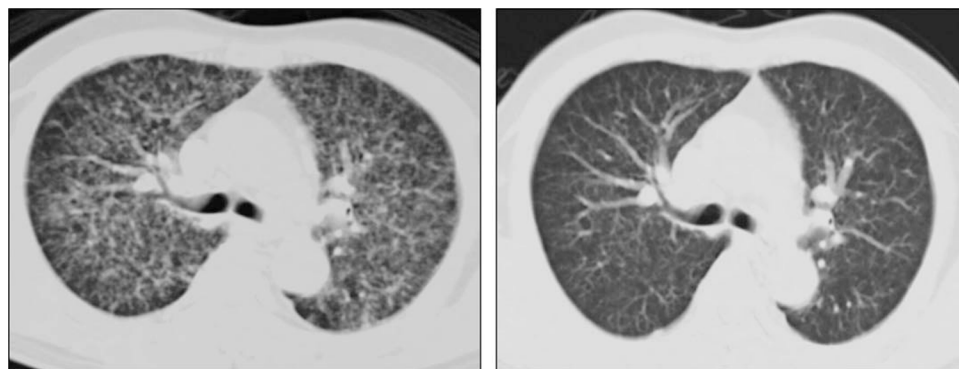


Figure 2 (A) CT of the thorax showing a diffuse reticulonodular pattern bilaterally which was more evident in the upper and middle zones. (B) CT of the thorax showing resolution of the reticulonodular shadowing 6 weeks after treatment.

hepatitis and oropharyngeal or gastrointestinal lesions.³ A definitive diagnosis requires a positive blood culture or histological demonstration in involved tissue.³

Learning points

- ▶ Despite no obvious immunocompromise except for diabetes, a high suspicion of index is required to diagnose disseminated histoplasmosis.
- ▶ Recognition of the typical fungal infection is essential for a correct diagnosis.
- ▶ The finding of a diffuse reticulonodular pattern on CT of the thorax should be correlated with clinical presentation for accurate diagnosis and treatment.

Competing interests None.

Patient consent Obtained.

REFERENCES

1. **Deepe GS.** Histoplasma capsulatum. In: Mandell GL, Bennet JE, Dolin R, eds. *Principles and Practice of Infectious Diseases*. Sixth edition. Philadelphia: Churchill Livingstone 2005:2718–33.
2. **Jariwalla A,** Tulloch BR, Fox H, *et al.* Disseminated histoplasmosis in an English patient with diabetes mellitus. *Br Med J* 1977;**1**:1002–4.
3. **Goodwin RA Jr,** Shapiro JL, Thurman GH, *et al.* Disseminated histoplasmosis: clinical and pathologic correlations. *Medicine (Baltimore)* 1980;**59**:1–33.

This pdf has been created automatically from the final edited text and images.

Copyright 2010 BMJ Publishing Group. All rights reserved. For permission to reuse any of this content visit <http://group.bmj.com/group/rights-licensing/permissions>.
BMJ Case Report Fellows may re-use this article for personal use and teaching without any further permission.

Please cite this article as follows (you will need to access the article online to obtain the date of publication).

Hasmoni MH, Shah ASM, Ayoub S, Hin LS, Rashid MAA. Disseminated histoplasmosis presenting with chronic ulcerative tongue lesions in a patient with diabetes. *BMJ Case Reports* 2010;10.1136/bcr.06.2010.3120, date of publication

Become a Fellow of BMJ Case Reports today and you can:

- ▶ Submit as many cases as you like
- ▶ Enjoy fast sympathetic peer review and rapid publication of accepted articles
- ▶ Access all the published articles
- ▶ Re-use any of the published material for personal use and teaching without further permission

For information on Institutional Fellowships contact consortiasales@bmjgroup.com

Visit casereports.bmj.com for more articles like this and to become a Fellow