

Automatic Diagnosis of Diabetic Retinopathy from Fundus Images Using Digital Signal and Image Processing Techniques

A.M Aibinu¹, M.I Iqbal², M. Nilsson², M.J.E Salami¹

¹ *Mechatronics Engineering Department
International Islamic University Malaysia
53100, Kuala Lumpur, Malaysia.
Tel: +601-73658247, E-mail: maibinu@gmail.com*

² *Department of Signal Processing
Blekinge Institute of Technology, Sweden.
14300 P.O Box 520 SE-37225 Ronneby, Sweden
E-mail muhammad.imran.iqbal,mikael.nilsson@bth.se*

Abstract

Automatic diagnosis and display of diabetic retinopathy from images of retina using the techniques of digital signal and image processing is presented in this paper. The acquired images undergo pre-processing to equalize uneven illumination associated with the acquired fundus images. This stage also removes noise present in the image. Segmentation stage clusters the image into two distinct classes while the abnormalities detection stage was used to distinguish between candidate lesions and other information. Methods of diagnosis of red spots, bleeding and detection of vein-artery crossover points have also been developed in this work using the color information, shape, size, object length to breadth ration as contained in the acquired digital fundus image. The algorithm was tested with a separate set of 25 fundus images. From this, the result obtained for Microaneurysms and Haemorrhages diagnosis shows the appropriateness of the method.

Keywords:

Diabetic Retinopathy, Fundus Image, Digital Image Processing, Segmentation, Retina.

Introduction

In recent times, there have been an increase in age and Society related diseases like diabetes [1]. The abnormalities associated with the eye can be divided into two main classes, the first being disease of the eye, such as cataract, conjunctivitis, blepharitis and glaucoma. The second group is categorized as life style related disease such as hypertension, arteriosclerosis and diabetes [2]. Diabetes can harm eyes by damaging blood vessels of eye retina, which in turn can cause loss of vision. When the retina is been affected as a result of diabetes, this type of disease is called diabetic retinopathy (DR).

Early detection and diagnosis have been identified as one of the ways to achieve a reduction in the percentage of visual impairment caused by DR with more emphasis on routine medical check-up for detection and monitoring of this disease [1]. During this process retina images (also called fundus images (FIs)) are carefully taken

using medical image camera and are manually searched by screeners and ophthalmologists for the presence of DR artifacts. A lot of approaches have been suggested and identified for reducing the stress caused by this regular screening exercises amongst which is the use of digital image and signal processing. This research work is one of the methods of applying digital signal and image processing techniques to the field of medical diagnosis in order to reduce the time and stress undergone by the ophthalmologists and other members of the team in the screening, diagnosis and treatment of DR.

A frame work for the automatic diagnoses of DR is presented in this paper. The proposed framework can augment the manual screening process for the detection and diagnoses of DR. This algorithm can determine the presence of DR artifacts. The input image with low quality reduce the effectiveness of the algorithm so in the pre-processing stage, the input image is enhanced to a certain quality level to minimize false detections. Segmentation is used to cluster the enhanced image into vein network and background information images. The segmented images are used in the classifier stage for detecting the presence or otherwise of features of DR. The algorithm has been tested with a separate database of 25 FIs and the results (i.e.98% sensitivity and 61% specificity) shows the accuracy of the proposed frame work.

The organization of this paper is as follows; Section. 2 give an introduction to: diabetes; D; different stages of DR and its artifacts. Section.3 discusses some of the related work and in Section.4 proposed frame work is elaborated whilst experimental results are presented in Section.5 and Section.6 concludes the paper.

Diabetes and Diabetic Retinopathy

Diabetes is a metabolism disorder of the body. The energy required by the body is obtained from glucose which is produced as a result of food digestion. The digested food entered into the blood stream, reaches the body cells with the aid of a hormone called insulin which allows and controls the glucose absorption from the blood into the cells. Pancreas take cares of producing the correct amount of insulin. In individuals with diabetes, the pancreas either

produces too little or no insulin or the cells do not react properly to the insulin that is produced. This in turn increases glucose in the blood, overflows into the urine and then passes out of the body. Uncontrolled diabetes can be extremely dangerous, resulting in; loss of vision, damage to the nerves, kidneys and increased risk of heart attack and the list could continue.

The progressive nature of DR, if not properly treated increases the peril with the increasing age of the patient [3] and it might eventually lead to loss of vision. DR occurrence has been generally categorized into three main phases and these are as explained sub sequently.

1) **Background Diabetic Retinopathy (BDR):** In this phase, the arteries in the retina become weak and start to leak, forming small, dot-like bodies called Haemorrhages. These leaking vessels often lead to swelling or edema in the retina and decreased vision.

2) **Proliferate Diabetic Retinopathy (PDR):** In this phase, circulation problems cause areas of the retina to become oxygen-deprived or ischemic. New fragile, vessels develop as the circulatory system attempts to maintain adequate oxygen levels within the retina. This phenomenon is called Neovascularisation. Blood may leak into the retina and vitreous, causing spots or floaters, along with decreased vision.

3) **Severe Diabetic Retinopathy (SDR):** In this phase, there is continued abnormal vessel growth and scar tissue, which may cause serious problems such as retinal detachment and glaucoma and gradual loss of vision.

These three phases can occur with any of the following artifacts:

Microaneurysms: These are the first clinical abnormality to be noticed in the eye. They may appear in isolation or in clusters as tiny, dark red spots or looking like tiny Haemorrhages within the retina light sensitive area. Their sizes range from 10-100 microns and are circular in shape [3]. At this stage, the disease is not yet eye threatening.

Haemorrhages: Occur in the deeper layers of the retina and are often called blot Haemorrhages because of their round shape.

Hard Exudates: This is one of the main characteristics of DR. It can vary in size from tiny specks to large patches with clear edges. These can impair vision by preventing light from reaching the retina.

Soft Exudates: Soft exudates of pale yellow-white in color are often called cotton wool spots. Their shapes are round or oval and are formed as a result of capillary occlusions which lead to the permanent damage of the retina functions [3].

Neovascularisation: This can be described as abnormal growth of blood vessels in areas of the eye including the retina and is associated with vision loss. This occurs in response to ischemia, or diminished blood flow to ocular tissues. These new blood vessels have weaker walls and may break and bleed, or cause scar tissue to grow that can pull the retina away from the back of the eye. When the retina is

pulled away it is called a retinal detachment and if left untreated, can cause severe vision loss, including blindness. In more advanced proliferate retinopathy; diabetic fibrous or scar tissue can form on the retina [3].

Abnormal Vein-Artery Crossover: An increase in the blood pressure in the blood artery presses the vein at the vein-artery cross over points which reduces or stops blood flow in the vein thus increasing pressure on its walls. This increased pressure can cause the veins swelling which might result in the leakage of the vein. This type of cross over points is called abnormal vein-artery crossover.

These artifacts are illustrated in Fig.1. The presence of any of the artifact means the occurrence of DR at some stage. The proposed algorithm emphasizes on the early detection of Microaneurysms, Haemorrhages and abnormal vein-artery crossovers for DR diagnosis.

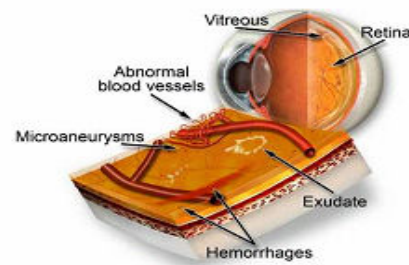


Fig. 1. Diabetic Retinopathy [4]

Related work

There has been an increase in the use of digital image processing techniques for the screening of DR after it was recommended as one of the method for screening DR [1]. Thus more work have been done to improve some of the existing screening methods while new approaches have also been introduced in order to increase the sensitivity and the specificity of the method. Sensitivity and specificity are the parameters used to measure the accuracy of an algorithm or a proposed diagnostic system. In this proposed work, Sensitivity refers to the percentage of abnormal fundus image classified as abnormal by the system while specificity can be defined as percentage of normal fundus image classified as normal. Abnormal image here means image with DR artifacts while normal means images without DR artifacts. The higher the values of these two factors the better is the system for the detection of DR. Most of the available work done can generally be categorized into screening of BDR and PDR while diagnosis of SDR has been left for the ophthalmologist. However, only few works have really been reported in the detection of Microaneurysm and exudates using geometric features of the artifacts. In this section, some of these past works are reviewed.

In [3], scale and orientation of selective Gabor filter are used to detect and classify the retina images into mild or severe case. The input image is first filtered through Gabor filter banks, the banks consist of several filters tuned to specific scales and orientation and the operation is

performed in frequency domain, the output of which is then analyzed. Detection of BDR is done by analyzing the width of the blood vessels. The presence of one local maxima in the plot of energy against orientation for more than 100 test images signify the presence of mild to BDR while the presence of more than one local maxima signify severe PDR. This method only signifies the presence of BDR and PDR without specifying the coordinates and the actual spots or disease type.

As reported in [5], an improvement to the tracking based method in [6] proposed a four step algorithm for detection and extraction of blood vessels in FIs. The blood vessels were first enhanced by the use of matched filtering. Entropy based thresholding was used to distinguish between background and vessels in the generated matched filter response image of step one. Length filtering was then employed to eliminate misclassified pixels before the application of a 3x3 and 11x11 neighbourhood windows to probe for branching points and intersection or crossovers. This algorithm works very well with normal FIs without lesions but perform poorly with images with lesions.

In [7], a computational model to extract vasculature From FIs and detect bifurcation and cross over points was presented by the use of six different steps. Naka-Rushton filters, cluster filter, hyperbole filter, median filter and skeletonization were used in order to remove noise and produced an optimized skeleton version of the veins. The sixth step was used for detecting and classifying cross over and bifurcation points. Naka-Rushton filtering method uses the non-linear retinal features to correct the problem of unequal illumination. The vein networks were extracted using the cluster filter similar to K-mean algorithm for two clusters one for each veins and the background. Impulsive noise contained in the binary segmented image was removed by the use of hyperbole filter. The resulting image was then reduced to one pixel thick by the skeletonization based on Zhang-Suen algorithm [8]. In the bifurcation and crossover detection, cross-point number (CPN) method was used. The presence of noise affects the performance of this algorithm as reflected in the result of the twelve images analyzed by this technique. Recommended method of improvement includes the use of a hybrid approach which combines genetic and heuristic procedures for detection of crossover points.

As reported in [9], a three step approach for detection and classification of bright lesions in colour fundus images was presented. The fundus image was first passed through a local contrast enhancement as a pre-processing stage, and then an improved fuzzy C-means (IFCM) is applied to the luminance/chrominance (LUV) colour space to segment all candidate bright lesions. This segments all possible bright lesions as well as false positives due to clusters overlapping, non uniformity of colour distribution and noise [9], thus a setback for this approach. The third step is hierarchal support vector machine (SVM) which diagonise true bright lesions from non lesions.

A similar system was developed in [2] to assist physician in detecting abnormalities associated with FIs of

the retina. An improvement to a four step diagnosis for reds pot recorded fairly good result on tested 230. The initial four steps involve converting an RGB FI to monochrome; from which areas of low density were extracted using binarization. This is followed by deletion of vascular regions and the last stage involves deletion of unnecessary elements. The above method suffered from lots of mis-detection and this necessitates its improvement. Improvement method suggested on mis-detection around the optic disk offers improvement only for fundus images with visible optic disk while is-detection that occurred around areas with multiple blood vessels were left unresolved.

Proposed Framework for the Diagnoses of DR

This frame work can be divided into three stages, thus making it more flexible to implement. Though it was originally developed for DR diagnoses, but due to its flexible nature it may be used for other digital image based computer aided diagnosis systems. Fig. 2 shows all the three stages of the frame work. Two graphical user interfaces (GUIs) were also developed, one for the ophthalmologist to mark the disease symptoms in the images for generating database and training the algorithm, the other was to diagnose and display these symptoms. A comprehensive discussion of the developed framework is subsequently discussed.

4.1 Pre-Processing Stage (PPS)

The acquired fundus images are sometimes of low quality. Common problems with FIs include presence of noise, low resolution and uneven illumination. The possible reasons for this quality degradation include sudden movement of camera and or the body part under examination at the time of image acquisition and unfavorable lighting conditions. All aforementioned quality issues can be addressed using different techniques in the PPS. In this proposed DR diagnostic system, aside from solving quality problems, this stage is also responsible for colour space conversion and image size standardization. The block diagram is as shown in Fig. 2 and are subsequently explained.

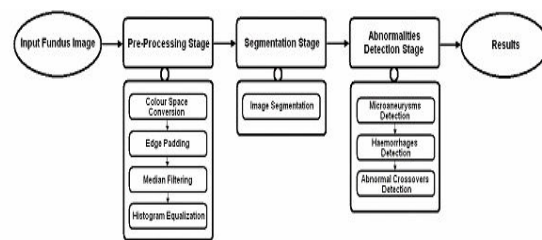


Fig. 2. Framework for the diagnosis of DR.

a) Colour Space Conversion: The input FIs can either be a colour image or grey scale image. In the case of a colour image, the system converts it to Hue, Saturation and Intensity (HSI) colour space [10]. The choice of HSI is based on the fact that the intensity component of the image can be disassociated from other components. In this work, the information needed for the diagnosis can be obtained from the intensity space. Apart from this, colour space conversion to HSI provides a meeting point for all types of input images

from which processing of images can commence.

b) Edge Padding: Usually in some FIs, retina information is contained in circularly shaped region surrounded by outer black region. The intensity of this black region is in the range of 0 to 32 (On a scale of 0-255), which in most cases can be considered as noise. The quality of the image can be affected by the presence of such noise. Experiments proved that filling this outer region with intensity value zero will not only minimize degradation of the image quality near the boundary but also improve the quality of the resulting image. Apart from zero filling and edge padding, other preprocessing activities performed on the image include intensity thresholding, minimum and maximum intensity detection and retina mask generation in this stage.

c) Median Filtering: Median filtering operation replaces a pixel by the median of all the neighboring pixels in a window (3x3 in our case). The whole image can be filtered by sliding this window over the whole image. The median filter is a non linear filter, which can reduce impulsive noise (as in our case) from an image without distorting the edges. Median filtering is an effective method of suppressing isolated noise without blurring sharp edges. It also has the capability of filtering outliers and is thus an excellent choice for the removal of salt and pepper noise and horizontal scanning artifacts.

d) Histogram Equalization: One of the problems associated with FIs is an uneven illumination. Areas at the centre of the image appears to be well illuminated, hence appears very bright while the sides appear to be very dark, showing that illumination decreases as the distance from the centre of the image increases. Amongst methods tried in resolving this problem are Naka- Rushton method [7] and adaptive histogram equalization (AHE) method. Though the former method works well for small parts of the image but it does not perform well for large image size. AHE method on the other hand, gives better performance, higher processing speed but with the main drawback of adding lots of noise to the image leading to very poor segmentation. A new approach termed Global-local Adaptive histogram equalization using Partially-Overlapped Windows (GLAPOW) [11] was used to alleviate the problem of uneven illumination without introducing noise and distortion to edges. The input and output images is shown in Fig.3 (a) Fig.3 (b) respectively. Further detail of all the phases involved in pre-processing can be found in [11].

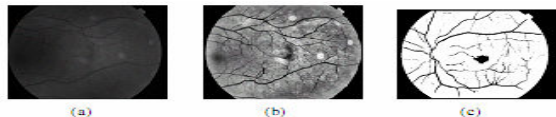


Fig. 3. Images at different stages (a) input image and (b) pre-processed image (c) a different segmented image.

4.2 Segmentation Stage

The main objective of segmentation stage is to group the image into regions [10] with same properties or characteristics. This plays a major role in image analysis system by facilitating the description of anatomical structures and other regions of interest. Different techniques used for image segmentation include simple thresholding,

K-means algorithm and fuzzy c-means. In this research work, segmentation by K-means with two non-overlapping clusters has been proposed based on its performance compared with other methods. Background and noisy pixels were segmented into one class and FI features which consist of the spots, exudates veins were segmented into another class. The non-overlapping of this method made it suitable for this research work since it is important to distinguish between the background and the main FI features. A sample of segmented image is shown in Fig. 3(c).

4.3 Abnormalities Detection Stage

This stage is dedicated to the final detection and classification of artifacts. After binary images have been created one for each symptom in the segmentation stage, each of these binary images can be processed differently based on the artifacts features (e.g. size, shape and other features) and each symptom (if present) can be detected separately. In this work, the DR diagnoses process at this stage was divided into three distinct stages in order to detect Microaneurysm, Haemorrhages and crossover points. This is as explained below.

a) Microaneurysms Detection: This is the first phase in abnormalities detection. Based on the features of Microaneurysms, a set of decision criteria were made for its diagnosis, this consist of: pixel counts; ratio of minor to major axes; robustness test; length and holes test. Pixel counts involve counting the number of pixel that constitutes a candidate Microaneurysm. A threshold of 0.5 was set for the ratio of minor to major axes with the assumption that Microaneurysm or red spots are cylindrical or circular in shape. All the candidates having minor to major axis ratios less than 0.5 were then excluded. In compactness test each candidate object is enclosed in a rectangular region and the ratio of the object area to the total area is calculated. This gives compactness of the objects. A threshold was defined for the known compactness of Microaneurysms and haemorrhages. Length test checks for the length of each candidate which could be used to distinguish between Microaneurysms and the disconnected veins. Finally, the hole test was conducted which determines the solidity of a region in order to finally accept it as a Microaneurysm or not. This test is based on the assumption that an object with a hole (off pixel) cannot be regarded as a candidate reds pot but can be a bleeding or other non vein related information.

b) Haemorrhages Detection: All tests conducted for Microaneurysms detection were also applied to haemorrhages detection but with different thresholds. The only exception was the hole test which was not included in haemorrhages detection.

c) Abnormal Crossover Detection: After removing all the Microaneurysms, Haemorrhages, fovea and noise, the image is ready for cross over or vein intersection points detection. Vein-artery cross over points were detected by using two different approaches, these are Simple cross-point number (SCN) method [7] and modified cross-point number (MCN) method. In MCN method, a 5x5 window is used instead of a 3x3 used in SCN method. The criterion used was cross point number (cpn > 4), where cpn is obtained from Eq. 1 with $P_{17} = P_1$. This is as shown in Fig.4.

$$cpn = \frac{1}{2} \sum_{i=1}^{16} |P_i - P_{i+1}| \quad (1)$$

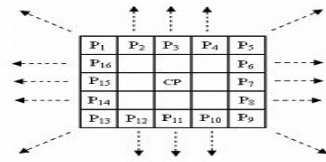


Fig. 4. Window used to find crossover points.

5. Experimental Result

In evaluating this proposed system, a small database of 25 FIs with size 1320x1032 pixels was used for the experiments. The database contained 10 images without DR artifacts and 15 images with different DR artifacts. Detection of abnormalities is centered on detecting red spots (microaneurysms) and bleeding (haemorrhages). The classification involves classifying an image as normal or abnormal. This involves the presence or otherwise of any of the mentioned symptoms. From this the specificity and sensitivity of the system was calculated. The value of sensitivity obtained is 98% while specificity value is 61%. There are two types of vein-artery cross over in FIs, one is regarded as normal cross over point and the other is regarded as abnormal cross over points. The abnormal crossing occurs when an artery crosses a vein and during the high blood pressure it presses the vein and causes a stop of the blood flow in vein which might lead to bleed from vein at that point. All other types of vein-artery crossings are normal. In this work, vein artery crossings were detected only but further probing needs to be done for classification purpose.

Conclusion

In this paper a new and flexible frame work for the detection of DR artifacts has been presented. This framework can be used for the diagnoses of other diseases. A system based on this framework which is able to diagnose patients with BDR and PDR artifacts from either colour or grey level FIs was developed. The DR artifacts of interest during this work include red spots, bleeding and abnormal vein artery crossovers. Two MATLAB GUIs were also developed during this research work, namely Data acquisition GUI (DAG) which was used by the ophthalmologist to marked the FIs and the second GUI called CVision was used for the diagnoses and display of diagnosed image with detected DR artifacts highlighted in different colors. The result obtained by this system, that is, specificity of 61% and sensitivity of 98%, can augment the diagnosis of DR. Other achievement of this work includes the detection of red spots and bleeding with relatively high level of accuracy using the geometric properties obtained from the artifacts. Future work would be to increase the specificity, improve the abnormal vein-Artery cross over detection and to include more artifacts.

Acknowledgments

We shall like to express our appreciation to Benny Lovstrom,

Victor Adolfsson and Dr. Jack Bergen for their support and encouragement. Furthermore, our appreciation goes to Asim Khan and Nagendra Gubbala for their support during this work

References

- [1] Conference Report: "Screening for Diabetic Retinopathy in Europe 15 years after St.Vincent: The Liverpool Declaration 2005", Liverpool, UK, Nov. 2005.
- [2] J. Hayashi, T. Kunieda, J. Cole, R. Soga, Y. Hatanaka, M. Lu, T. Hara and H. Fujita, "A Development of Computer Aided Diagnosis System Using Fundus Images", Proceeding of the 7th International Conference on Virtual Systems and Multi Media, Berkeley, California, USA, pp.429-438, Oct.2001.
- [3] D. Vallabha, R. Dorairaj, K.R. Namuduri and H. Thompson, "Automated Detection and Classification of Vascular Abnormalities in Diabetic Retinopathy", Conference Record of the 38th Asilomar Conference on Signals, Systems and Computers, Pacific Grove, CA, USA, vol.2, pp.1625-1629, Nov.2004.
- [4] Sample Image, [Online], Available, <http://www.dambrosio-eye-care-boston.com/diabetic-retinopathy.html>, Aug. 2007.
- [5] T. Chanwimaluang, and G. Fan, "An Efficient Blood Vessel Detection Algorithm for Retinal Images Using Local Entropy Thresholding", Proceedings of the 2003 International Symposium on Circuits and Systems, Bangkok, Thailand, vol.5, pp.V-21-V-24, May2003.
- [6] L. Zhou, M.S. Rzeszotarski, L.J. Singerman, and J.M. Chokreff, "The Detection and Quantification of Retinopathy Using Digital Angiograms", IEEE Trans. On Medical Imaging vol.13, no.4, pp. 619-626, Dec.1994.
- [7] V. Bevilacqua, S. Cambo, L. Cariello and G. Mastronardi, "A Combined Method to Detect Retinal Fundus Features", European Conference on Emergent Aspects in Clinical Data Analysis, Pisa, Italy, Sept.2005.
- [8] T.Y. Zhang and C.Y. Suen, "A Fast Thinning Algorithm for Thinning Digital Patterns", Communication of ACM, vol27, no.3, pp.236-239, March 1984.
- [9] Z. Xiaohui and O. Chutatape, "Detection and Classification of Bright Lesions in Colour Fundus Images", International Conference on Image Processing, Singapore, vol.1, pp.139-142, Oct. 2004.
- [10] R.C. Gonzalez, R.E. Woods and S.L. Eddins, "Digital Image Processing Using MATLAB", 2nd edition, ISBN 0-201-18075-8, Prentice Hall, 2002.
- [11] A.M. Aibinu, M.I. Iqbal, M. Nilsson and M.J.E. Salami, "A New Method of Correcting Uneven Illumination Problem in Fundus Images", Submitted to: International Conference on Robotics, Vision, Information, And Signal Processing, Penang, Malaysia, Nov.20

