

False Positive Detection Rate of R2-CAD in Evaluation of Breast Lesions at Full-Field-Digital Mammogram (FFDM)

Radhiana H, Humairah SC, Mohd Amran AR, Siti Kamariah CM, Fitriana Yusrin Y
 IIUM Breast Centre, Department of Radiology, Kulliyyah of Medicine,
 International Islamic University Malaysia, Kuantan, Pahang.



Introduction

Mammogram interpretation is challenging and the performance level varies between radiologists. Double reviewing increases cancer detection¹, however was not feasible in many centres due to lack of radiologist and cost.

CAD (computer aided diagnostic) system was developed to improve radiologist performance by simulating double reviewing. It identifies suspicious regions on mammograms (microcalcifications and focal densities), to draw the reader's attention to these areas for evaluation of possible abnormalities². Reported series have shown that the sensitivity of CAD ranges from 76% to 94%^{3,4}.

R2-CAD is one of the soft ware available in clinical use, and has been on the market for several years with FDA approval. It is currently being used in our centre⁵.

Aim

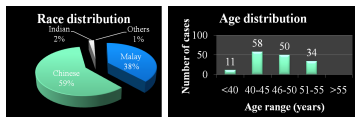
The objective of our study is to evaluate the detection rate of breast lesions by R2-CAD, with FFDM (full-field digital mammogram) in diagnostic and screening mammography.

Method

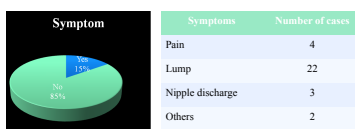
- This is a retrospective study
- Mammography cases done between January 2008 until May 2008 were reviewed on the BARCO monitor with CAD applied.
- A total of 191 cases in which R2-CAD prompted possible mass lesions or calcifications were included in this study.
- The images were reviewed by 2 radiologist blinded to the final diagnosis.
- Each CAD lesion was documented and correlation was made with supplementary imaging and sampling by FNAC or biopsy wherever applicable.
- Final diagnosis with conclusion of CAD detected lesion whether it was malignant, benign or normal breast tissue were made.

Results

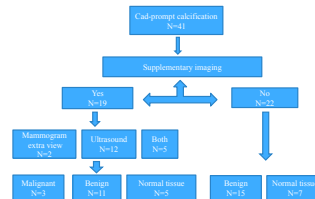
1. Demographic data:



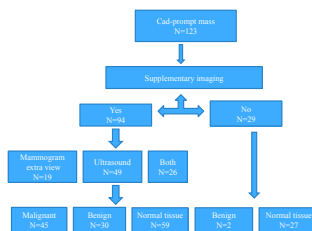
2. Screening versus diagnostic mammogram



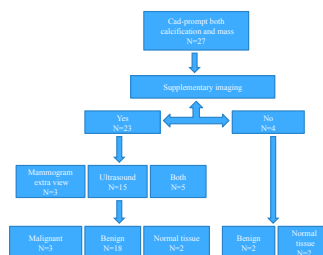
3. Evaluation of CAD-prompt calcification



4. Evaluation of CAD-prompt mass



5. Evaluation of CAD-prompt calcification and mass



6. Conclusion of CAD-prompt lesion

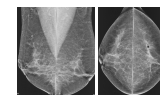
CAD-prompt	Malignant lesion	Benign lesion	False positive/ (normal tissue)	Total
Calcification	3	26	12	41 (21.5%)
Mass	5	32	86	123 (64.4%)
Both	3	20	4	27 (14.1%)
Total	11 (5.8%)	78 (40.8%)	102 (53.4%)	191 (100%)

References

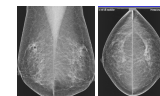
- Kopans DB. Double reading. Radiol Clin North Am. 2000; 38:719-724
- Dean JC, Ilvento CC. Improved cancer detection Using Computer-Aided Detection with diagnostic and screening mammography: Prospective study of 104 cancers. AJR 2006; 187:20-28.
- Helvie MA, Hadjiiski L, Makariou E, Chan HP et al. Sensitivity of non-commercial computer-aided detection system for mammographic breast cancer detection: Pilot clinical trial. Radiology 2004; 231:208-214.
- Gur D, Stalder JS, Hardesty LA, Zheng B et al. Computer-aided detection performance in mammographic examination of masses: Assessment. Radiology 2004; 233:418-423.
- Humairah SC, Radhiana H, Mohd Amran AR. Preliminary experience in the use of CAD in FFDM in Asian women with breast lesions. Poster for 6th ABDA Jakarta, 2008.

Example of cases

False-positive

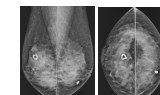


Case 1: Asymptomatic 51-year old lady. Mammogram showed no dominant mass lesion. CAD marked a normal breast tissue which showed no interval change compared with previous mammogram done.

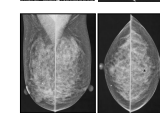


Case 2: A 65 years old lady who had a positive family history and came for screening mammogram which was normal. CAD-prompt mass was normal breast parenchyma, confirmed on breast US and comparison with previous mammogram.

Inaccurate CAD-prompt

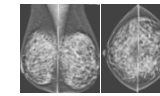


Case 3: A 47-year old lady came for screening mammogram which showed benign macro-calcifications in both breasts. CAD marked this calcification as lump on the right side and didn't mark the similar calcification on the left side.

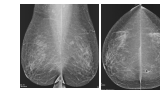


Case 4: A 44 year-old lady presented with a right breast lump. Mammogram showed a low density mass in the right breast and on US this is a solid lesion. CAD did not mark the lesion. Another CAD marker on the contra-lateral side with no definite mass seen. Biopsy of right breast lesion showed no malignant cells.

Benign cases

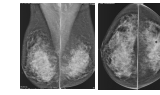


Case 5: A 53 years old lady who came for screening mammogram. There was no family history of breast cancer. CAD marked multiple bilateral calcifications which were vascular calcifications.

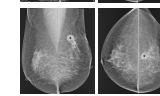


Case 6: A 52-year old lady for screening mammogram. CAD marked a benign lump in left CC view which was suggestive of a fibroadenoma (US correlation). Another CAD -prompt mass on the same view was false-positive.

Malignant cases



Case 7: Asymptomatic 57-year old lady and mammogram showed stromal distortion with stellate configuration at LUOQ (marked by CAD on CC view). US showed a 6 mm suspicious lesion which was confirmed cancer.



Case 8: A 64-year old lady presented with left breast lump. Mammogram showed a mass with speculated margin. CAD marked this lesion on both views, suggestive of it's strong positive possibility. It was confirmed invasive ductal carcinoma.

Conclusion

R2-CAD has a high false positive prompt rate and low detection rate for malignant lesions.

In our CAD program, after a preliminary study that showed this system missing about one third of malignant lesions, we deliberately set a relatively low threshold for abnormal detection for the benefits of non-subspecialty trained radiologist interpreting mammograms in our centre.

As such, it is only used for a diagnostic aid and not to replace radiologist in mammographic interpretation. Sorting meaningful marks from unhelpful marks will therefore remains the crux of effectively using CAD.

Acknowledgements:

- The Director General of Health, MOH Malaysia
- Research Management Centre, IIUM
- MRTs Dept of Radiology IIUM
- All staff in IIUM Breast Centre