

CASE REPORT

A Case of Focal Eventration of Left Hemidiaphragm with Transthoracic Left Kidney confused with a Traumatic Diaphragmatic Hernia

H Radhiana*, MMed (Rad), M Y Mubarak**, MMed (Rad)

*Department of Radiology, Kulliyyah of Medicine, International Islamic University Malaysia (IIUM), Kuantan, Pahang, Malaysia,

**Department of Diagnostic Imaging, Hospital Tengku Ampuan Afzan, Kuantan, Pahang, Malaysia

SUMMARY

Focal eventration of the diaphragm with transthoracic kidney is a very rare condition. It is usually asymptomatic and often revealed as an incidental finding on imaging studies. We presented a case of previously undiagnosed focal eventration of left hemidiaphragm with transthoracic left kidney confused with traumatic diaphragmatic hernia. Differentiation of these two conditions is important as each were managed differently. A traumatic diaphragmatic hernia needs early surgical intervention whereas no treatment was required for focal diaphragmatic eventration in most cases. Diagnostic laparoscopy confirmed the findings in this case and the patient was managed conservatively.

KEY WORDS:

Transthoracic kidney, Diaphragmatic eventration, Diaphragmatic hernia

INTRODUCTION

Focal eventration of the diaphragm occurs when there is a local weakness of the diaphragm causing a focal elevation but the diaphragm retains its continuity and attachments to the costal margins. The weakness causes abdominal contents to herniate into the chest¹. An unusual variation of eventration is when there is associated upward migration of a kidney. The kidney lies cranial to its normal position known as transthoracic kidney, which is a rare type of kidney ectopia. This condition is usually asymptomatic and requires no treatment but may be confused with a traumatic rupture of the diaphragm in trauma patients.

CASE REPORT

A 47-year-old man who was involved in a motor vehicle accident was admitted with fractures of left superior and inferior pubic rami; and midshaft of left femur. On admission, vital signs were normal and blood investigations were unremarkable. One day later, he had an episode of haematuria with a drop in blood pressure and hemoglobin level. There was no episode of respiratory distress. Urgent ultrasound of the abdomen and pelvis showed generalized thickening of the urinary bladder wall. There was no haematoma within the urinary bladder. The right kidney was normal but the left kidney fossa was empty. Review of chest radiograph showed a well-defined opacity at the left lower

zone with no obliteration of cardiac border or lateral border of left hemidiaphragm (Figure 1a). This opacity was a focal eventration of left hemidiaphragm, clearly demonstrated by the scanogram of computed tomography (CT) performed urgently for this patient (Figure 1b). The CT showed the left kidney located higher than its normal position in the thoracic cavity with parts of large bowel. There was no feature suggestive of injury of this abnormally located kidney and bowels (Figure 2). There was generalized thickening of the wall of the urinary bladder with small amount of haematoma within its lumen. However, no contrast extravasations from the urinary bladder were seen post contrast infusion. CT scan findings were suggestive of congenital transthoracic kidney with focal eventration of left hemidiaphragm and urinary bladder contusion. Diagnostic laparoscopy was performed to rule out diaphragmatic hernia. The findings were intact left hemidiaphragm with no evidence of defect, normal hiatal opening, left kidney ectopia and urinary bladder contusion. Other intra abdominal organs were normal. Plating for closed fracture at midshaft of left femur was done for this patient. His condition was complicated with hospital-acquired pneumonia, which was fully treated. He was discharged well 12 days after the admission.

DISCUSSION

Focal eventration of the diaphragm is caused by anatomical or functional deficiency of part of the diaphragm allowing abdominal contents to herniate into the chest. It is usually asymptomatic and identified incidentally when imaging studies particularly chest radiograph were performed for unrelated reasons¹. Depending upon its location, upward migration of different organs can be seen associated with this eventration. The incidence of transthoracic kidney in diaphragmatic eventration is rarely reported².

In a trauma patient, focal diaphragmatic elevation can be caused by traumatic diaphragmatic rupture and differentiation with focal diaphragmatic eventration can be difficult based on clinical or imaging findings¹. It is important for the surgeon to differentiate these two conditions due to its different management. Early surgical repair of traumatic diaphragmatic hernia is done to avoid potentially catastrophic risk of herniation, incarceration and strangulation of the abdominal viscera whereas focal diaphragmatic eventration often requires no treatment^{1,2}.

This article was accepted: 2 March 2011

Corresponding Author: Radhiana Hassan, Department of Radiology, Kulliyyah of Medicine, IIUM, Jalan Hospital Campus, 25100 Kuantan, Pahang, Malaysia Email: radhianahassan@gmail.com

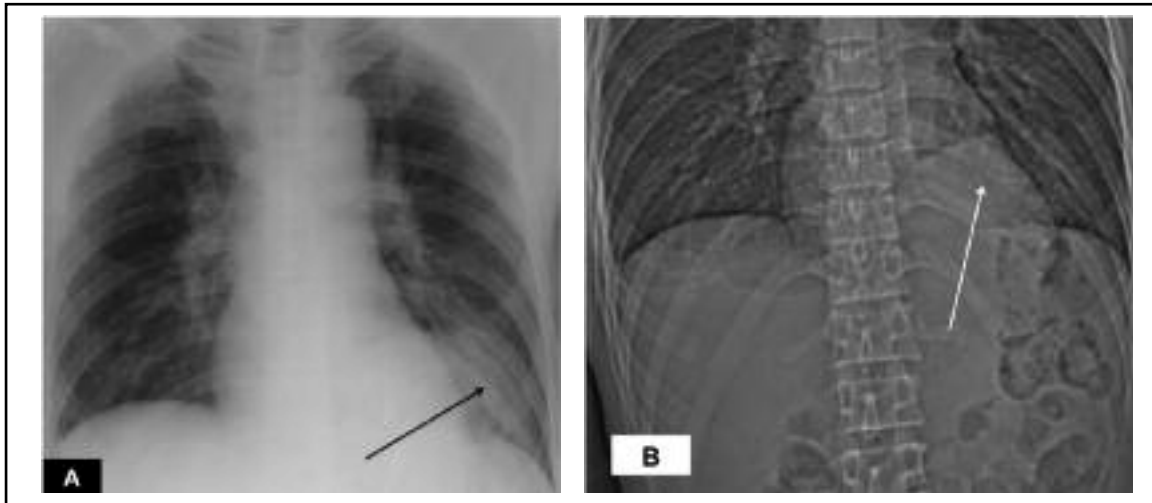


Fig. 1: (A) Postero-anterior chest radiograph showed well-defined focal opacity at left lower zone (black arrow). (B) Scanogram from CT scan of this patient clearly demonstrated focal eventration of the left hemidiaphragm (white arrow).

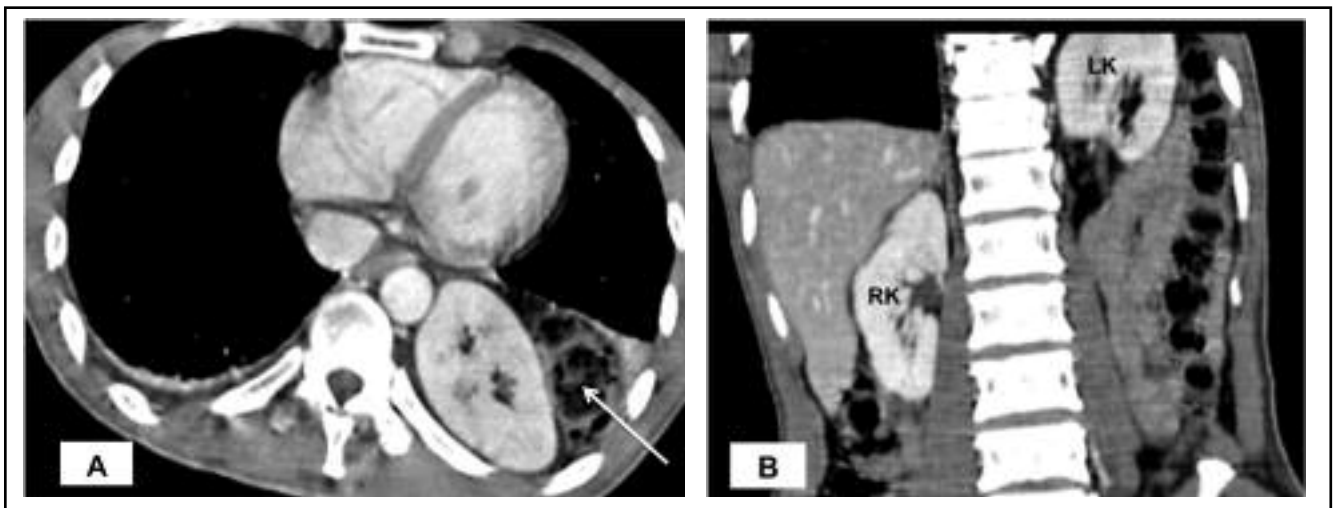

Fig. 2: Computed tomography of the abdomen. (A) Axial contrast-enhanced scan showed the left kidney and part of the bowel (arrow) within the thoracic cavity, in this image at the level of T10. (B) Coronal reformatted image showed higher location of left kidney (LK) compared to normal position of right kidney (RK).

Chest radiograph as initial and most commonly performed radiological imaging can demonstrate focal elevation of the diaphragm, especially if it was right-sided eventration¹. Left-sided focal eventration is more difficult to be assessed on chest radiograph due to overlying cardiac shadow³. Occasionally, it demonstrated an opacity mimicking a mass lesion as in this case. Further assessment can be done with CT and reformatted images can delineate the diaphragmatic outline better⁴. Ectopic kidneys can be evaluated with excretory urography and ultrasonography³. Magnetic resonance imaging can be helpful but is not feasible in acute trauma cases.

Diagnostic laparoscopy is an excellent tool in the evaluation of a stable patient with suspected diaphragmatic injury, which may be difficult to differentiate from diaphragmatic eventration on imaging^{1, 5}. No intervention is required in asymptomatic cases³. Associated anomalies in other organs are rare².

This case illustrates the challenge in managing trauma patient with coincidental findings of a rare form of congenital anomalies, which can be confused with conditions related to the trauma itself.

REFERENCES

1. Mantoo SK, Mak K. Congenital diaphragmatic eventration in an adult: a diagnostic dilemma. *Singapore Med J* 2007; 48: 136-37.
2. Sozubir S, Demir H, Ekingen G, Guvenc BH. Ectopic kidney in a child with congenital diaphragmatic hernia. *Eur J Pediatr Surg* 2005; 15: 206-09.
3. Andrezej D, Elzbieta CC, Ryszard M, Grzegorz JS, Kamil T. Thoracic ectopic kidney in adults: a report of 2 cases. *Folia Morphol* 2003; 62: 313-16.
4. Brink AJ, Heiken JP, Semenkovich J, Teefey SA, McClellan BL, Sagel SS. Abnormalities of the diaphragm and adjacent structures: findings on multiplanar spiral CT scans. *Am J Roentgenol* 1994; 163: 307-10.
5. Yamashita J, Iwasaki A, Kawahara K, Shirakusa T. Thoracoscopic approach to the diagnosis and treatment of diaphragmatic disorders. *Surg Laparosc Endosc* 1996; 6: 485-88.