

Updated Diagnosis Criteria for Confluent and Reticulated Papillomatosis: A Case Report

Seongmoon Jo¹, Hyun Sun Park^{1,2}, Soyun Cho^{1,2}, Hyun-Sun Yoon^{1,2}

¹Department of Dermatology, Seoul National University College of Medicine,

²Department of Dermatology, SMG-SNU Boramae Medical Center, Seoul, Korea

Dear Editor:

Confluent and reticulated papillomatosis (CRP), a rare skin disorder of unknown etiology, is characterized by hyperkeratotic papules confluent in the central area and reticulated hyperpigmented patch in the peripheral area¹. Since Gougerot and Carteud first identified CRP in 1927, this disease has been diagnosed by using clinical courses, histological findings, and treatment results. However, other diseases, such as fungal infection or other pigmented skin diseases, were frequently misdiagnosed as CRP because of the lack of diagnostic criteria for CRP. Therefore, Davis et al.¹ proposed the diagnostic criteria for CRP on the basis of a study on 39 patients, as follows: (i) clinical findings of scaly brown macules and patches, with at least some appearing reticulated and papillomatous; (ii) involvement of the upper trunk and neck; (iii) negative fungal staining of scales; (iv) no response to antifungal treatment; and (v) excellent response to minocycline. However, a few cases of CRP sparing the upper trunk have also shown the typical histopathological findings, clinical findings, and treatment responses of CRP.

A 42-year-old Korean woman presented to our clinic with a 4-year history of asymptomatic, brownish, and reticulated skin lesions in her antecubital and axillary regions (Fig. 1A). She reported that her skin lesions had worsened

in May and improved slightly in October without any specific treatment. We performed a potassium hydroxide test to rule out fungal infection. Because the test result was negative at the antecubital fossa but positive at the axilla, we began treatment with oral itraconazole and topical flutrimazole cream for 2 weeks. Despite the 2 weeks of treatment, her skin lesions persisted. We then performed an axillary skin biopsy. Histopathological evaluation revealed papillomatosis and hyperkeratosis of the epidermis, and downward growth of the epidermis between the rete ridges (Fig. 2). Periodic acid Schiff staining did not reveal any fungal organism. On the basis of these findings, we diagnosed her condition as CRP limited to the flexural areas. After 2 months of doxycycline treatment (100 mg twice a day), her skin lesions completely disappeared (Fig. 1B).

Our patient exhibited only limited lesions at the antecubital fossae and axilla, which is inconsistent with the previous diagnostic criteria for CRP¹. Several cases of CRP had involved various flexural areas alone, including the axilla^{2,3}, popliteal fossa², or antecubital regions⁴. These lesions fulfilled other diagnostic criteria for CRP. Therefore the criteria related to the primary affected sites should be revised. In addition, the criteria for fungal staining and response to antifungal treatment should be modified. Occasionally, CRP and fungal infection coexist⁵, as in this patient, however an important diagnostic consideration is that CRP lesions cannot be improved with antifungal treatment even in the presence of a positive fungal examination. Finally, minocycline^{3,4} has been known as the treatment of choice for CRP; however, other antibiotics have also been efficacious³. The exact reason for the effect of antibiotics is unclear, but many dermatologists speculate that their anti-inflammatory effect may be more predominant than their anti-bacterial effect¹.

As mentioned above, the previous diagnostic criteria for

Received April 1, 2013, Revised June 3, 2013, Accepted for publication June 14, 2013

Corresponding author: Hyun-Sun Yoon, Department of Dermatology, SMG-SNU Boramae Medical Center, 20 Boramae-ro 5-gil, Dongjak-gu, Seoul 156-707, Korea. Tel: 82-2-870-2382, Fax: 82-2-831-0741, E-mail: hsyoon79@gmail.com

This is an Open Access article distributed under the terms of the Creative Commons Attribution Non-Commercial License (<http://creativecommons.org/licenses/by-nc/3.0>) which permits unrestricted non-commercial use, distribution, and reproduction in any medium, provided the original work is properly cited.

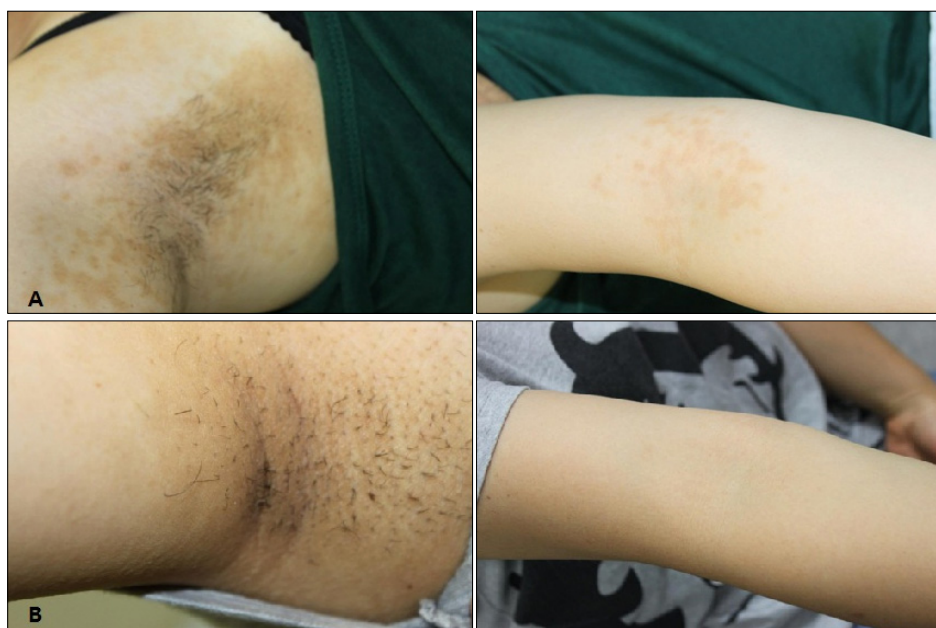

Fig. 1. (A) Hyperpigmented scaly macules with a reticular pattern on the axilla and antecubital fossa. (B) Complete resolution of the skin lesions after 2 months of doxycycline treatment.

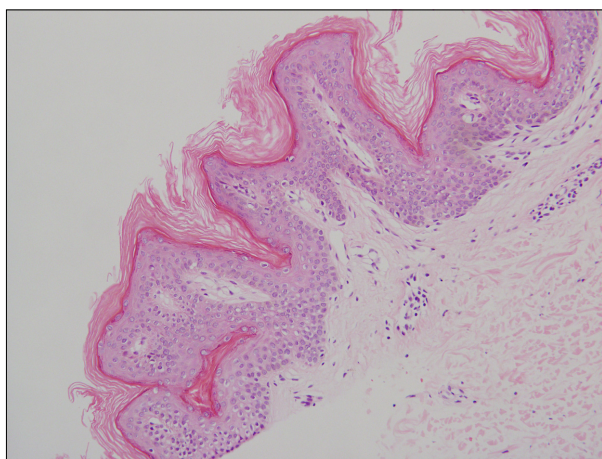


Fig. 2. Histopathological findings of the axillary lesion showing an orthokeratotic epidermis with acanthosis and papillomatosis plus mild perivascular lymphocytic infiltrate in the superficial dermis (H&E, $\times 200$).

CRP had several limitations in cases of unusually involved location, co-infection with fungus, and use of antibiotics other than minocycline. Therefore, we propose a modified diagnostic criteria, as follows: (i) clinical findings including scaly brown macules and patches, with at least some

appearing reticulated and papillomatous; (ii) involvement of the upper trunk, neck, or flexural areas; (iii) negative fungal staining of scales or no response to antifungal treatment; and (iv) excellent response to antibiotics.

REFERENCES

1. Davis MD, Weenig RH, Camilleri MJ. Confluent and reticulate papillomatosis (Gougerot-Carteaud syndrome): a minocycline-responsive dermatosis without evidence for yeast in pathogenesis. A study of 39 patients and a proposal of diagnostic criteria. *Br J Dermatol* 2006;154:287-293.
2. Lee D, Cho KJ, Hong SK, Seo JK, Hwang SW, Sung HS. Two cases of confluent and reticulated papillomatosis with an unusual location. *Acta Derm Venereol* 2009;89:84-85.
3. Davis RF, Harman KE. Confluent and reticulated papillomatosis successfully treated with amoxicillin. *Br J Dermatol* 2007;156:583-584.
4. Kim MR, Kim SC. Confluent and reticulated papillomatosis on the arm successfully treated with minocycline. *J Dermatol* 2010;37:749-750.
5. Stein JA, Shin HT, Chang MW. Confluent and reticulated papillomatosis associated with tinea versicolor in three siblings. *Pediatr Dermatol* 2005;22:331-333.