

일측성 구순열 환자에서 3차원 수치사진측량 스캔과 직접계측 방법의 비교

석효현¹ · 권근용² · 백승학³ · 최태현¹ · 김석화¹

¹서울대학교 의과대학 서울대학교병원 성형외과학교실, ²질병관리본부 역학조사과, ³서울대학교 치과대학 교정학교실

Comparison of the 3D Digital Photogrammetry and Direct Anthropometry in Unilateral Cleft Lip Patients

Hyo Hyun Seok¹, Geun-Yong Kwon², Seung-Hak Baek³, Tae Hyun Choi¹, Sukwha Kim¹

¹Department of Plastic and Reconstructive Surgery, Seoul National University Hospital, Seoul National University College of Medicine, Seoul;

²Division of Epidemic Intelligence Service, Korea Centers for Disease Control and Prevention, Osong;

³Department of Orthodontics, Seoul National University School of Dentistry, Seoul, Korea

Background: In cleft lip patients, the necessity of a thorough preoperative analysis of facial deformities before reconstruction is unquestioned. The surgical plan of cleft lip patient is based on the information gained from our preoperative anthropometric evaluation. A variety of commercially available three-dimensional (3D) surface imaging systems are currently introduced to us in plastic surgery for these use. However, few studies have been published on the soft tissue morphology of unrepaired cleft infants described by these 3D surface imaging systems.

Methods: The purpose of this study is to determine the accuracy of facial anthropometric measurements obtained through digital 3D photogrammetry and to compare with direct anthropometry for measurement in unilateral cleft lip patients. We compared our patients with three measurements of dimension made on both sides: heminasal width, labial height, and transverse lip length.

Results: The preoperative measurements were not significantly different in both side of labial height and left side of heminasal width. Statistically significant differences were found on both side of transverse lip length and right side of heminasal width. Although the half of preoperative measurements were significantly different, trends of results showed average results were comparable.

Conclusion: This is the first study in Korea to simultaneously compare digital 3D photogrammetry with traditional direct anthropometry in unilateral cleft lip patients. We desire this study could contribute the methodological choice of the many researchers for proper surgical planning in cleft lip reconstruction field.

Keywords: Anthropometry / Cleft lip / Photogrammetry

Introduction

Accurate, reliable, and objective anthropometric system for quantifying the soft tissue of the face is required in effective treat-

ment planning and regular postsurgical outcome assessment in many craniofacial anomalies including cleft lip patients [1].

Measurements of the human face as part of the body have been performed since the Greek era, and many aspects of Greek proportion sciences, the golden proportion, canons of important Renaissance artists, physical anthropology, and cephalometry can be found in modern clinical anthropometry. Measurement of cleft patients' faces was started only in the twentieth century and, in 1936, the first such anthropometric study in patients with cleft palate was published by Peyton [2].

Correspondence: Sukwha Kim

Department of Plastic and Reconstructive surgery, Seoul National University College of Medicine, 101 Daehak-ro, Chongno-gu, Seoul 110-744, Korea
Tel: +82-2-2072-3530 / Fax: +82-2-3675-3680 / E-mail: kimsw@snu.ac.kr

*This study was supported by grant no 04-2008-0130 from the SNUH Research Fund.

Received February 4, 2013 / Revised March 22, 2013 / Accepted March 26, 2013

Since 1936, the facial soft tissue appearance of cleft patients has been evaluated by means of various anthropometric and cephalometric techniques. But few studies have been published on the soft tissue morphology of unrepaired cleft infants.

Developments in computer technology have made possible the three-dimensional (3D) evaluation of hard and soft tissues in diagnosis, treatment planning and post-treatment results [3]. Most of all, digital 3D photogrammetry has important advantage, which could avoid unnecessary ionizing radiation and the young patients to be suffered during inevitable long time to scan them.

The purpose of this study is to determine the accuracy of facial anthropometric measurements obtained through digital 3D photogrammetry and to compare with direct anthropometry for measurement in unrepaired unilateral cleft lip patients.

Materials and Methods

1. Study population

The subjects of this study were consecutive patients presenting to the plastic surgery department at Seoul National University Hospital since for two years from October 2009 to December 2011. We have analyzed randomly enrolled cases of cleft lip patients preoperatively. It was 24 cases (18 males and 6 females), with 11 complete unilateral cleft lip and 13 with incomplete unilateral cleft lip, aged 3 to 26 months who were treated by a single experienced surgeon. Cleft lip was present on left side in 14 cases and right side in 10 cases. They are unrepaired unilateral cleft lip patients including acceptably qualified manual and 3D photogrammetric anthropometric data.

2. 3D Photogrammetry Imaging System

The 3D Photogrammetry Imaging System, 3D facial scanner (RS-400FL, MXR Ltd., Seoul, Korea) we used was developed and patented by MXR Communications Inc. and is named 'RENAI system'. The maximal area scanned simultaneously is 230 mm × 300 mm in a single capture. The photographs were scanned at a resolution of 640 × 480 pixels per inch. The minimal walking distance is 600 to 700 mm. It takes in 0.8 seconds. This system is worked with optical space encoding methods.

3. Evaluation of anthropometric measurements

For direct anthropometry, anthropometric points were located

with a sharpened toothpick dipped in gentian violet solution by the most experienced surgeon intra-operatively after anesthesia. We measured with spreading caliper and fabric tape measure.

For 3D digital photogrammetry, we sent our patients to 3D facial scanner unit in alert status, we did not use any sedation agent (such as chloral hydrate syrup) and got our 3D photography data with their permission. The images were captured in the rest position. Distances were digitally measured twice for each subject.

The anthropometric results including 3D photos were requested to be assessed on two separate occasions, with at least a two week interval between each evaluation to minimize the potential for memory recall bias. And we compared each data with those of direct anthropometry.

4. Measurement error

All the scanned data of the involved patients was analyzed twice.

5. Statistical analysis

The comparison of the measurements was performed with Student's paired *t*-test (or Wilcoxon signed ranks test) by SAS ver. 9.1.3 (SAS Inc., Cary, NC, USA). To compare two measurements, a paired *t*-test was used on variables satisfied in the normal distribution. Wilcoxon signed ranks test was used on the other variables as shown in Table 1. A difference between the measurements was regarded statistically significant if *p*-value < 0.05.

6. Three anthropometric measurement items

We compared our patients with three measurement of dimen-

Table 1. Comparison of the three-dimensional (3D) digital photogrammetry and direct anthropometry with a paired test

Measurement items	3D photo	Manual A	Mean of difference	<i>p</i> -value
Heminasal width				
Right	14.30±2.23	16.33±3.99	-2.02	0.0112
Left	15.53±1.87	16.66±3.52	-1.13	0.1413
Labial height				
Right	9.60±3.71	9.28±1.65	0.32	0.8247 ^{a)}
Left	8.42±3.58	9.02±1.97	-0.60	0.4524
Transverse lip length				
Right	13.38±4.10	16.00±3.15	-2.62	0.0092 ^{a)}
Left	13.47±4.23	15.65±3.07	-2.18	0.0215

^{a)}Wilcoxon signed ranks test.

sion made on both sides: heminasal width (sn-ac), labial height (sbal-cph), transverse lip length (cph-ch). We used anthropometric points described by Farkas in Table 2 and anthropometric measurement items in Table 3.

Results

Preoperative anthropometric measurements were taken during 2010 to 2011 and measurements were performed on each our patient. As shown in Fig. 1, the anthropometric points were located with two methods, direct anthropometry and 3D photogrammetry.

The results of anthropometric measurements in unrepaired cleft lip patients are shown in Table 1. As shown in Table 1, the preoperative measurements were not significantly different in both side of labial height (sbal-cph) and trends of results showed average values were comparable in other variables.

Statistically significant differences were not observed across

Table 2. Definition of anthropometric points

Subalare (sbal)	The labial insertion of the alar base
Cheilon (ch)	The point located at each labial commissure
Crista philtri (cph)	The point on each elevated margin of the philtrum just above the vermilion line: the Peaks of Cupid's bow
Alar curvature (ac)	The facial insertion of the alar base
Subnasale (sn)	The midpoint of the angle at the columella base where the lower border of the nasal septum and the surface of the upper lip meet

Table 3. Anthropometric measurement items in unrepaired unilateral cleft lip patients

Subnasale-alar curvature	Heminasal width
Subalare-crista philtri	Labial height
Crista philtri-cheilon	Transverse lip length

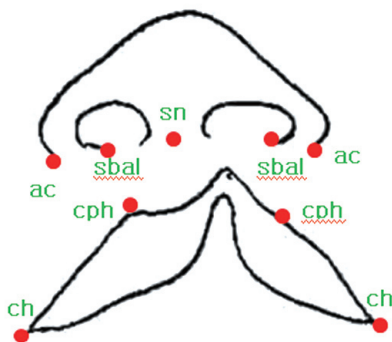


Fig. 1. Anthropometric points in unrepaired unilateral cleft lip patients. ac, alar curvature; ch, cheilon; cph, crista philtri; sbal, subalare; sn, subnasale.

measurement methods for measurement variables on left side of heminasal width (sn-ac). Statistically significant differences were found on both side of transverse lip length (cph-ch) and right side of heminasal width (sn-ac).

Discussion

The use and popularization of anthropometric measurements in clinical evaluation of cleft patients must be attributed to Farkas [2], whose primary studies have been carried out for almost 30 years. One of the first publication in his extensive scientific activities in this area concerns the use of anthropology in the observation of facial cleft. In this paper, for the first time, the authors suggested the use of direct anthropometry to evaluate anatomical changes of facial features in patients with cleft lip and palate, particularly as a primary means of assessing the initial cleft defect as compared to the final result of treatment. Suggestions presented in this paper became a milestone in developing clinical anthropometry for craniofacial deformities.

Anthropometry for facial evaluation can be divided into two methods, direct anthropometry and indirect anthropometry. For preoperative planning and postoperative evaluation in plastic surgery, the most ideal and accurate method is a direct anthropometry, but this requires special skills of examiners and could be time consuming in clinical setting, especially in congenital plastic surgery field. Especially, it is difficult to measure in the case of children because of poor cooperation, and it requires highly skilled specialty. If we want their cooperation, we should let them under sedation or anesthesia. And it also lacks re-productivity because direct anthropometry always need specialists [4].

Indirect anthropometry, currently used, includes two-dimensional (2D) photogrammetry, and laser and CT scanning. These methods have specific limitations, such as complexity, inaccuracy, long image capture time, and radiation exposition. Thus, each of these established techniques of data acquisition could be suboptimal. And there is increasing awareness that these techniques are incapable of fully capturing the 3D complexity of the human face [5,6].

Developments in computer technology have made possible the 3D evaluation of hard and soft tissues in diagnosis, treatment planning, and post-treatment results [3]. Assessment of facial deformity should ideally be quantitative, objective, and easily archived.

To assess cleft lip deformity properly, accurate and quantifiable 3D method is essential. It should be practical for use in the infant population and allow data to be archived and retrieved simply.

The 3D assessment is also possible using various methods including CT or laser scanning. CT scanning has the disadvantage of exposure to ionizing radiation. The use of laser scanning to capture facial morphology has certain disadvantages for use in infant or pediatric patients, as it needs a patient to cooperate with assessment for a prolonged period of time. The long scan time (up to 20 seconds) raises the need for sedation of the infants. Therefore they could not be used with uncooperative infants or children [7].

The 3D Photogrammetry Imaging System, 3D facial scanner (RS-400FL, MXR Ltd.) used in this study is powerful method in the 3D assessment of unrepaired cleft lip patients and statistically significant as shown in most of our results (Fig. 2). This system could also overcome the limitations of other 3D systems, such as CT and laser scanning, cited above. It is easier to measure and has less chance to make errors during measurement. Furthermore, it is possible to repeat measurements. Its quick captures result in permanent archival record of a subject's face. It is noninvasive to patients, It does not require any sedation.

However, according to our results, statistically significant differences were found on both side of transverse lip length and right side of heminasal width. This was unsatisfactory results against our expectations.

We thought these results related with several causes.

First, the proposed peak of Cupid's bow, has traditionally been less well defined. Noordhoff considers the proposed base of the philtral column an anatomically determined landmark that should be preserved irrespective of caliper measurements. "Noordhoff's point" is chosen on the vermilion-cutaneous junction where




Fig. 2. Three-dimensional (3D) images and automeasurement of 3D Photogrammetry Imaging System (RENAI system) from cleft lip patients.

the cutaneous roll and the vermilion-mucosal junction lines begin to converge medially. In our cases, we also defined the proposed peak of Cupid's bow according to Noordhoff but it was the anatomically defined point. We thought this ambiguous nature of definition of proposed peak of Cupid's bow was reflected in our measurement of transverse lip length.

Second, measurement of transverse lip length and heminasal width which have character of curvature, as compared with labial height and heminasal width, was shown to be error-prone, especially in 3D anthropometric condition.

To our knowledge, the present study is the first to simultaneously compare 3D Photogrammetry Imaging System with traditional direct anthropometry in Korea.

The causes of facial deformity following repair of cleft lip patient are not known. Like previous researchers, we also think it might develop following inaccurate reconstruction or as a result of impaired normal growth of the soft and hard tissues. This impairment of normal growth might occur secondarily to scarring or might represent an inherent growth deficiency. In these cleft lip patients undergoing changes in time, archival serial measurement should be needed, compounding the labor-intensive features of direct anthropometry. The necessity of a thorough preoperative analysis of facial deformities before reconstruction is unquestioned. Postoperative assessment, as well as preoperative assessment in this study is also essential. Serial and consecutive assessment of facial status in growth of patient is important. It might be the criteria of next operation and basis of the medical determination of the congenital plastic surgeon. Through the regular reassessment of the morphology, the changes resulting from growth and the timing of surgical intervention can be determined.

3D photogrammetry is known as a noninvasive, accurate and archival method of assessing facial form and surgical change in cleft lip patients. Facial deformities in cleft lip patients could be quantified and measured reliably with this tool. Through this study, we look forward to emphasize pre-operative anthropometric evaluation of cleft lip patient and wish convenient and simple 3D photogrammetry to be commonly used.

In cleft lip patients, the surgical plan is also based on the information gained from our preoperative anthropometric evaluation and is tailored to the patient's specific functional and aesthetic needs. By storing and then superimposing 3D data, the facial development of these children might be better understood.

When designing clinical studies which assess the aesthetic results of various treatment techniques in cleft lip patients, it is always

difficult to select the most appropriate evaluation method. We desire this study could contribute the methodological choice of the many researchers in cleft lip reconstruction field. Further work will be needed in validity and reliability of 3D photogrammetry and application of plastic reconstruction of other congenital deformity.

Conflict of Interest

No potential conflict of interest relevant to this article was reported.

References

1. Kim SW, Park JL, Kim JC, Baek SH, Son WG. Development of computerized anthropometric analysis model in cleft lip nasal deformity using 3D laser scanned facial cast model. *J Korean Soc Plast Reconstr Surg* 2008;35:303-8.
2. Farkas LG. *Anthropometry of the head and face*. New York: Raven Press; 1994.
3. Weinberg SM, Naidoo S, Govier DP, Martin RA, Kane AA, Marazita ML. Anthropometric precision and accuracy of digital three-dimensional photogrammetry: comparing the Genex and 3dMD imaging systems with one another and with direct anthropometry. *J Craniofac Surg* 2006;17:477-83.
4. Paik DH, Han KH, Won DC, Choi TH, Kim JH, Son DG. Accuracy of indirect anthropometry on cast model of the nose: comparison with direct anthropometry. *J Korean Soc Plast Reconstr Surg* 2008;35:47-54.
5. Krimmel M, Kluba S, Bacher M, Dietz K, Reinert S. Digital surface photogrammetry for anthropometric analysis of the cleft infant face. *Cleft Palate Craniofac J* 2006;43:350-5.
6. Devlin MF, Ray A, Raine P, Bowman A, Ayoub AF. Facial symmetry in unilateral cleft lip and palate following alar base augmentation with bone graft: a three-dimensional assessment. *Cleft Palate Craniofac J* 2007;44:391-5.
7. Wong JY, Oh AK, Ohta E, Hunt AT, Rogers GF, Mulliken JB, Deutsch CK. Validity and reliability of craniofacial anthropometric measurement of 3D digital photogrammetric images. *Cleft Palate Craniofac J* 2008;45:232-9.