

# Tinea Incognito Simulating Herpes Simplex Virus Infection

Young Woon Park<sup>1,2,3</sup>, Jae Woo Choi<sup>1</sup>, Seung Hwan Paik<sup>1</sup>, Dong Young Kim<sup>1,2,3</sup>,  
Seon-Pil Jin<sup>2,3</sup>, Hyun Sun Park<sup>1</sup>, Hyun-Sun Yoon<sup>1,2,3</sup>, Soyun Cho<sup>1,2,3</sup>

<sup>1</sup>Department of Dermatology, SMG-SNU Boramae Medical Center,

<sup>2</sup>Laboratory of Cutaneous Aging and Hair Research, Biomedical Research Institute, Seoul National University Hospital,

<sup>3</sup>Institute of Human-Environment Interface Biology, Medical Research Center, Seoul National University College of Medicine, Seoul, Korea

Dear Editor:

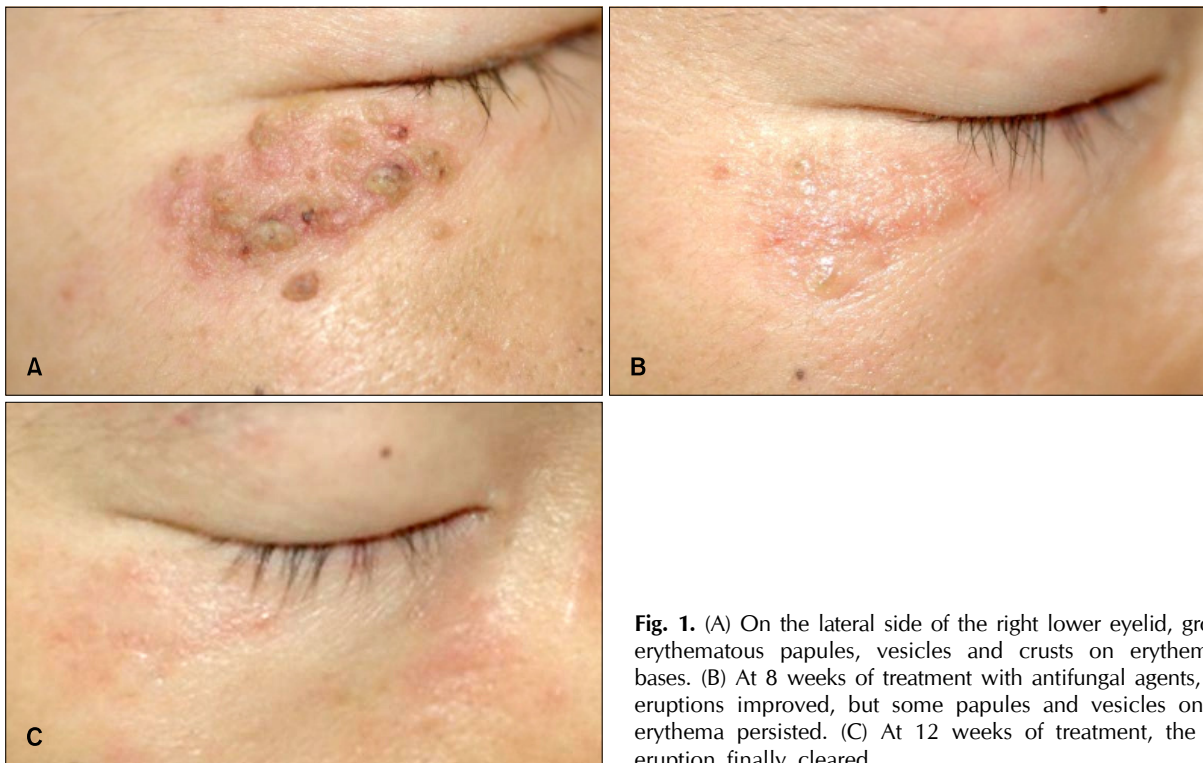A 30-year-old-man presented with a 2-month history of a facial lesion. He was examined by general practitioners, and the eruption was diagnosed as eczema. Topical corticosteroid was applied for 1 month, and the eruption initially seemed to improve with this treatment; but later on, it persisted, and gradually extended in size. Dermatological examination revealed the presence of grouped erythematous papules, vesicles and crusts on erythematous bases, on the right lower eyelid (Fig. 1A). He had no medical history, and no family member who had had similar skin eruptions or symptoms. The initial clinical differential diagnosis included herpes simplex, herpes zoster, and allergic contact dermatitis, caused by an antibiotic eye drop. We prescribed oral and topical acyclovir, and performed a skin biopsy, to reveal the exact diagnosis. Skin lesions did not respond to 5 days of acyclovir therapy, and histologic examination showed infiltration of various inflammatory cells from the upper to lower dermis, parakeratosis, irregular acanthosis, intraepidermal exocytosis of neutrophils, and extravasation of erythrocytes (Fig. 2A, B). Fungal hyphae and spores in the stratum corneum were identified on the periodic acid Schiff sta-

ined section (Fig. 2C). These findings led to the diagnosis of superficial fungal infection that had lost its typical clinical appearance, because of the use of steroids. The cause of infection might be dermatophytes, but non-dermatophytic fungi could be possible. Afterwards, the history that he had had contact with his cat was verified. He was administered oral terbinafine 250 mg daily, and topical terbinafine cream. After 8 weeks, the number of papules decreased, and the inflammatory reaction improved (Fig. 1B). Treatment was continued a month longer, and the facial eruption finally cleared (Fig. 1C). The clinical features of tinea faciei are characterized by various morphology, and because of that, the entity can mimic many other cutaneous disorders<sup>1</sup>. Moreover, because tinea faciei is relatively uncommon when compared with other forms of superficial fungal infection, it is often misdiagnosed; and treated with glucocorticosteroids, not antifungal agents<sup>1</sup>. Imprecise use of topical or oral corticosteroids in tinea faciei can modify their clinical features, and make the correct diagnosis more difficult<sup>2</sup>; therefore, tinea faciei is one of the considerable examples of tinea incognito<sup>1</sup>. One retrospective study showed 35.7% cases of tinea incognito among tinea faciei, because of improper diagnosis, and inappropriate therapy<sup>3</sup>. Other authors revealed that 50% to 70% of patients with tinea faciei are initially misdiagnosed as having other dermatoses<sup>2</sup>. The pathomechanism of tinea incognito is thought to be closely associated with a steroid-modified response of the host to cutaneous fungal infection<sup>4</sup>. Topical corticosteroids allow fungi to grow readily, and alter the clinical feature of the lesions, because they have immunosuppressive activity<sup>5</sup>. Regrettably, glucocorticosteroids are extensively used by patients and non-dermatologists, and lead to long-lasting fungal infections<sup>1</sup>, similar to that which

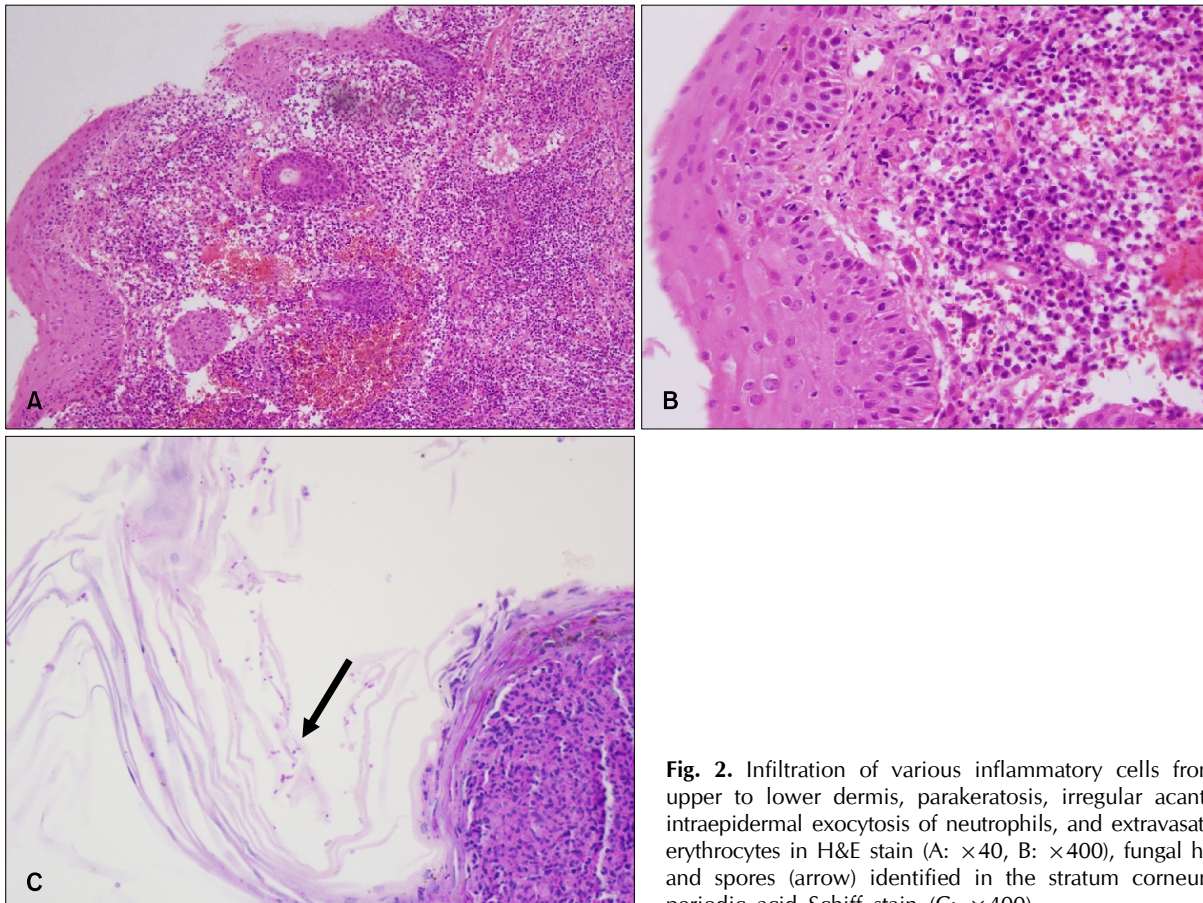
Received January 15, 2013, Revised April 24, 2013, Accepted for publication April 26, 2013

**Corresponding author:** Soyun Cho, Department of Dermatology, SMG-SNU Boramae Medical Center, 20 Boramae-ro 5-gil, Dongjak-gu, Seoul 156-849, Korea. Tel: 82-2-870-2381, Fax: 82-2-870-3866, E-mail: sycho@snu.ac.kr

This is an Open Access article distributed under the terms of the Creative Commons Attribution Non-Commercial License (<http://creativecommons.org/licenses/by-nc/3.0>) which permits unrestricted non-commercial use, distribution, and reproduction in any medium, provided the original work is properly cited.



**Fig. 1.** (A) On the lateral side of the right lower eyelid, grouped erythematous papules, vesicles and crusts on erythematous bases. (B) At 8 weeks of treatment with antifungal agents, facial eruptions improved, but some papules and vesicles on mild erythema persisted. (C) At 12 weeks of treatment, the facial eruption finally cleared.



**Fig. 2.** Infiltration of various inflammatory cells from the upper to lower dermis, parakeratosis, irregular acanthosis, intraepidermal exocytosis of neutrophils, and extravasation of erythrocytes in H&E stain (A:  $\times 40$ , B:  $\times 400$ ), fungal hyphae and spores (arrow) identified in the stratum corneum, by periodic acid Schiff stain (C:  $\times 400$ ).

occurred in our case.

Atypical presentations of tinea faciei can lead to misdiagnosis. The present case underlines that physicians should keep in mind that clinical features of superficial fungal infection can be substantially modified by incorrect treatment, to mimic even herpes simplex virus infection. Fungal infection should be on the list of differential diagnoses of facial eruptions, especially in cases not responding to preceding management.

## REFERENCES

1. Lange M, Jasiel-Walikowska E, Nowicki R, Bykowska B. Tinea incognito due to Trichophyton mentagrophytes. *Mycoses* 2010;53:455-457.
2. Lin RL, Szepletowski JC, Schwartz RA. Tinea faciei, an often deceptive facial eruption. *Int J Dermatol* 2004;43:437-440.
3. Romano C, Ghilardi A, Massai L. Eighty-four consecutive cases of tinea faciei in Siena, a retrospective study (1989-2003). *Mycoses* 2005;48:343-346.
4. Al Aboud K, Al Hawsawi K, Alfadley A. Tinea incognito on the hand causing a facial dermatophytid reaction. *Acta Derm Venereol* 2003;83:59.
5. Ohta Y, Saitoh N, Tanuma H, Fujimura T, Katsuoka K. Local cytokine expression in steroid-modified tinea faciei. *J Dermatol* 1998;25:362-366.

<http://dx.doi.org/10.5021/ad.2014.26.2.269>

# Allergic Contact Dermatitis Caused by Topical Eye Drops Containing Latanoprost

Ji Hye Lee, Tae Hyung Kim, Soo-Chan Kim

*Department of Dermatology, Gangnam Severance Hospital, Cutaneous Biology Research Institute, Yonsei University College of Medicine, Seoul, Korea*

Dear Editor:

Prostaglandin analogues are increasingly used as the first choice of drug for an open angle glaucoma<sup>1</sup>. They are known to be highly effective and have little systemic side effects. Latanoprost is an ester prodrug analog of prostaglandin F<sub>2</sub>α which reduces the intraocular pressure by increasing the uveoscleral outflow<sup>2</sup>. Latanoprost 0.005% has received the European and the US approval as the first-line drug reducing the intraocular pressure in patients with open angle glaucoma or ocular hypertension. Allergic contact dermatitis due to latanoprost is rare, although it has been commonly used worldwide on patients with

glaucoma. Only three cases of allergic contact dermatitis due to latanoprost have been reported in the English literature<sup>3-5</sup>. Herein we report a case of allergic contact dermatitis due to topical eye drops containing latanoprost. A 70-year-old man presented with an 1-year history of skin lesion on both eyelids to our department. He showed erythematous oozing patches on both eyelids, and suffered from severe pruritus and burning sensation (Fig. 1). He was diagnosed with open angle glaucoma 5 years ago, and he has been treated with latanoprost 0.005% (Xalatan<sup>®</sup>; Pfizer, New York, NY, USA) and dorzolamide/timolol (Cosopt<sup>®</sup>; Merck, Whitehouse Station, NJ, USA). The

Received August 29, 2012, Revised April 11, 2013, Accepted for publication May 8, 2013

**Corresponding author:** Soo-Chan Kim, Department of Dermatology, Gangnam Severance Hospital, 211 Eonjuro, Gangnam-gu, Seoul 135-720, Korea. Tel: 82-2-2019-3362, Fax: 82-2-3463-6136, E-mail: kimsc@yuhs.ac

This is an Open Access article distributed under the terms of the Creative Commons Attribution Non-Commercial License (<http://creativecommons.org/licenses/by-nc/3.0>) which permits unrestricted non-commercial use, distribution, and reproduction in any medium, provided the original work is properly cited.