

Clinical Study

Risk of vertebral artery injury: comparison between C1–C2 transarticular and C2 pedicle screws

Jin S. Yeom, MD^a, Jacob M. Buchowski, MD, MS^b, Ho-Joong Kim, MD^a,
Bong-Soon Chang, MD^c, Choon-Ki Lee, MD^{c,*}, K. Daniel Riew, MD^b

^aSpine Center and Department of Orthopaedic Surgery, Seoul National University College of Medicine and Seoul National University Bundang Hospital, 166 Gumiro, Bundang-ku, Sungnam 463-707, Republic of Korea

^bDepartment of Orthopaedic Surgery, Washington University in St Louis, 660 S. Euclid Ave., Campus Box 8233, St Louis, MO 63110, USA

^cDepartment of Orthopaedic Surgery, Seoul National University College of Medicine and Seoul National University Hospital, 101 Daehangno, Jongno-gu, Seoul 110-744, Republic of Korea

Received 5 March 2012; revised 10 February 2013; accepted 3 April 2013

Abstract

BACKGROUND CONTEXT: To our knowledge, no large series comparing the risk of vertebral artery injury by C1–C2 transarticular screw versus C2 pedicle screw have been published. In addition, no comparative studies have been performed on those with a high-riding vertebral artery and/or a narrow pedicle who are thought to be at higher risk than those with normal anatomy.

PURPOSE: To compare the risk of vertebral artery injury by C1–C2 transarticular screw versus C2 pedicle screw in an overall patient population and subsets of patients with a high-riding vertebral artery and a narrow pedicle using computed tomography (CT) scan images and three-dimensional (3D) screw trajectory software.

STUDY DESIGN: Radiographic analysis using CT scans.

PATIENT SAMPLE: Computed tomography scans of 269 consecutive patients, for a total of 538 potential screw insertion sites for each type of screw.

OUTCOME MEASURES: Cortical perforation into the vertebral artery groove of C2 by a screw.

METHODS: We simulated the placement of 4.0 mm transarticular and pedicle screws using 1-mm-sliced CT scans and 3D screw trajectory software. We then compared the frequency of C2 vertebral artery groove violation by the two different fixation methods. This was done in the overall patient population, in the subset of those with a high-riding vertebral artery (defined as an isthmus height ≤ 5 mm or internal height ≤ 2 mm on sagittal images) and with a narrow pedicle (defined as a pedicle width ≤ 4 mm on axial images).

FDA device/drug status: Not approved (C1–C2 transarticular and C2 pedicle screws).

Author disclosures: **JSY:** Grant: Research Grant of Seoul National University Bundang Hospital (04-2008-006) (B); Speaking/Teaching Arrangements: Medtronic (B), DePuy (B). **JMB:** Consulting: Stryker, Inc. (B), CoreLink, Inc. (B), Globus Medical, Inc. (C), Medtronic, Inc. (B); Speaking/Teaching Arrangements: Stryker, Inc. (C), Globus Medical, Inc. (B), K2M, Inc. (B), DePuy, Inc. (B); Trips/Travel: International Spine Study Group (ISSG) (B, Reimbursement for travel accommodations only); Complex Spine Study Group (B, Reimbursement for travel accommodations only); AO Spine (B, Reimbursement for travel accommodations and honoraria); Broadwater, Inc. (B, Honoraria). **H-JK:** Nothing to disclose. **B-SC:** Stock Ownership: Bio Alpha, Inc. (B). **C-KL:** Nothing to disclose. **KDR:** Royalties: Biomet (F); Medtronic (G), Osprey (D); Stock Ownership: Expanding Orthopedics (C); Private Investments: Amedica (C), Benvenue (C), Nexgen Spine (B), Osprey (C), Paradigm Spine (C), PSD (C), Spinal Kinetics (C), Spineology (C), Vertiflex (C); Trips/Travel: AOSpine (Honorarium B), New England Spine Society Group (Honorarium A), Dubai Spine Society (reimbursement only), SpineMasters (reimbursement only), Broadwater (reimbursement and ski lift tickets); Board of Directors: AOSpine (E);

Research Support (Investigator Salary): AOSpine (Lab & Materials, Paid directly to institution/employer), Cerapedics (Laboratory and Materials, Paid directly to institution/employer), Spinal Dynamics (Laboratory and Materials, Paid directly to institution/employer); Research Support (Staff/Materials): AOSpine (Lab & Materials, Paid directly to institution/employer), Cerapedics (Lab & Materials, Paid directly to institution/employer), Spinal Dynamics (Lab & Materials, Paid directly to institution/employer); Grants: Medtronic Sofamor Danek (for IDE participation, Paid directly to institution/employer); Fellowship Support: AOSpine (E, Paid directly to institution/employer), OREF (D, Paid directly to institution/employer).

The disclosure key can be found on the Table of Contents and at www.TheSpineJournalOnline.com.

Institutional review board status: This study received the approval of the institutional review board of Seoul National University Bundang Hospital.

* Corresponding author. Department of Orthopaedic Surgery, Seoul National University College of Medicine and Seoul National University Hospital, 101 Daehangno, Jongno-gu, Seoul 110-744, Republic of Korea. Tel.: (82) 2-2072-2336; fax: (82) 2-2072-2718.

E-mail address: choonki@snu.ac.kr (C.-K. Lee)

RESULTS: There were 78 high-riding vertebral arteries (14.5%) and 51 narrow pedicles (9.5%). Most (82%) of the narrow pedicles had a concurrent high-riding vertebral artery, whereas only 54% of the high-riding vertebral arteries had a concurrent narrow pedicle. Overall, 9.5% of transarticular and 8.0% of pedicle screws violated the C2 vertebral artery groove without a significant difference between the two types of screws ($p=.17$). Among those with a high-riding vertebral artery, vertebral artery groove violation was significantly lower ($p=.02$) with pedicle (49%) than with transarticular (63%) screws. Among those with a narrow pedicle, vertebral artery groove violation was high in both groups (71% with transarticular and 76% with pedicle screws) but without a significant difference between the two groups ($p=.55$).

CONCLUSIONS: Overall, neither technique has more inherent anatomic risk of vertebral artery injury. However, in the presence of a high-riding vertebral artery, placement of a pedicle screw is significantly safer than the placement of a transarticular screw. Narrow pedicles, which might be anticipated to lead to higher risk for a pedicle screw than a transarticular screw, did not result in a significant difference because most patients (82%) with narrow pedicles had a concurrent high-riding vertebral artery that also increased the risk with a transarticular screw. Except in case of a high-riding vertebral artery, our results suggest that the surgeon can opt for either technique and expect similar anatomic risks of vertebral artery injury. © 2013 Elsevier Inc. All rights reserved.

Keywords: C2 pedicle screw; C1–C2 transarticular screw; Vertebral artery injury; High-riding vertebral artery; Narrow C2 pedicle

Introduction

Posterior C1–C2 transarticular screw fixation can result in vertebral artery injury, with potentially catastrophic results such as vertebrobasilar insufficiency, brain stem and posterior fossa infarct, and even death [1–3]. The rate of vertebral artery injury has been reported to be as high as 8.2% [1–3]. Vertebral artery injuries commonly occur if a drill, tap, or screw perforates or occludes the vertebral artery in the vertebral artery groove of C2, which is located on the lower surface of C2 and lateral to the pedicle (Fig. 1) [1–8]. It has been suggested that C2 pedicle screw combined with C1 lateral mass screw placement is inherently safer than C1–C2 transarticular screw fixation in view of the risk of vertebral artery injury at C2, as the medially directed trajectory of the C2 pedicle screw carries the screw away from the vertebral artery, which normally is located lateral to the screw [9–11]. Although this is a commonly held belief, no large series have been performed to assess the validity of this assumption. Knowing whether the risk of vertebral artery injury is higher with C1–C2 transarticular screw fixation versus C2 pedicle screw placement is important, as the knowledge would provide surgeons with information on which to choose the appropriate fixation method, particularly in cases where the anatomy may be abnormal (eg, in the cases of a high-riding vertebral artery or narrow pedicle).

To date, two reports comparing the risk of vertebral artery injuries by transarticular screw versus pedicle screw have been published [12,13]. Both studies stated that the anatomic risk of vertebral artery injury is not significantly different between transarticular and pedicle screws, contrary to the previous suggestion favoring pedicle screw [9–11]. Although these studies carefully analyzed the risk of each fixation method, like all studies, they have

limitations. One study [13] used mainly 2D images with three-dimensional (3D) images used only in 10 patients. As stated by Miyata et al. [14], a 3D evaluation is essential for establishing the anatomic relationship between the course of the vertebral artery and the intended screw trajectory. Furthermore, both studies analyzed a small number of patients without a power analysis, raising the possibility that they were underpowered to detect a difference between the two fixation methods (beta error).

In addition to analyzing the safety of each technique in the general patient population, it may be even more important to evaluate the risk of vertebral artery injury in those with a relatively small space to accommodate these screws. These are the individuals in whom the risk of vertebral artery is increased, and the choice of appropriate screw fixation is even more important. Two anatomic variations have been suggested to be associated with vertebral artery injury. First, it is well known that the risk of vertebral artery injury during C1–C2 transarticular screw placement increases with a high-riding vertebral artery [2,5,6,15,16]. However, we are unaware of any reports comparing the risk of vertebral artery injury by C1–C2 transarticular screw versus C2 pedicle screw in those with a high-riding vertebral artery, and no references on the topic could be found in a computerized search using MEDLINE. Second, narrow pedicles of C2 theoretically can increase the risk of vertebral artery injury by C2 pedicle screw. Yoshida et al. [12] stated in their 3D simulation study that pedicle screw placement was limited by the width of the C2 pedicle. However, again, as far as we know, no studies have been performed comparing the risk of vertebral artery injury with transarticular screw versus pedicle screw in those with a narrow pedicle.

Given the limitations of the existing studies, the primary purpose of our study was to compare the anatomic risk of vertebral artery groove violation by transarticular screw versus pedicle screw using a large number of computed tomography (CT) scan images and 3D screw trajectory simulation software. The comparison was performed in three groups of patients: the overall patient population and two subsets, those with a high-riding vertebral artery and those with narrow pedicles. Of note, neither C1–C2 transarticular screws nor C2 pedicle screws are approved by the US Food and Drug Administration.

Materials and methods

Materials

This study was approved by our institutional review board. Computed tomography scans (Mx8000 IDT; Philips Medical Systems, Best, The Netherlands) of the cervical spine of consecutive patients taken at a single institution between March 2007 and June 2008 were initially included for the analyses. All the CT scans taken in 1.0-mm intervals were initially included regardless of the indications for the scan or the diagnosis. Exclusion criteria included CT scans of the patients under 20 years of age, postoperative CT scans, CT scans with unsatisfactory imaging of C1 and/or C2, CT scans with severe metal artifact from prior dental work causing noise in 3D reconstruction images, CT scans of patients with a congenital C2–C3 block vertebra, which obscured the landmarks for the entry point of transarticular

EVIDENCE & METHODS

Context

Whether transarticular or pedicle screws (at C1–C2) pose greater risk to the vertebral arteries is unclear.

Contribution

In this computer simulation using actual patient CT scans, the authors found no difference in risk between the two techniques unless a high-riding vertebral artery was noted, in which case pedicle screws appear safer.

Implication

The study provides valuable information that might help improve safety for patients.

—The Editors

screw, and CT scans of patients with infection, tumor, or trauma at C1 and/or C2.

Simulation

Digital files of 1.0-mm interval axial CT scan images were loaded onto a screw trajectory planning software (V-Works; Cybermed, Inc., Reston, VA, USA). From the axial images, sagittal and coronal images along with 3D images were reconstructed (Fig. 1). The simulation function of this software was similar to preoperative planning software used for

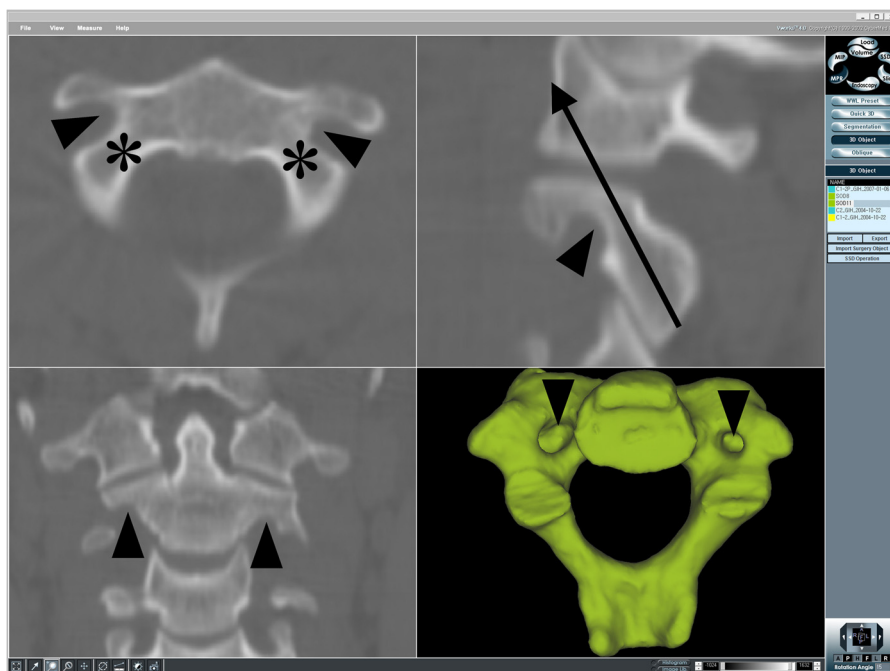


Fig. 1. Axial, sagittal, coronal, and three-dimensional inferior computed tomography scan images of C2 show vertebral artery groove of C2 (arrowheads). It is located anteroinferior to the transarticular screw trajectory (arrow) on a sagittal plane and lateral to the pedicle (asterisks) on an axial plane.

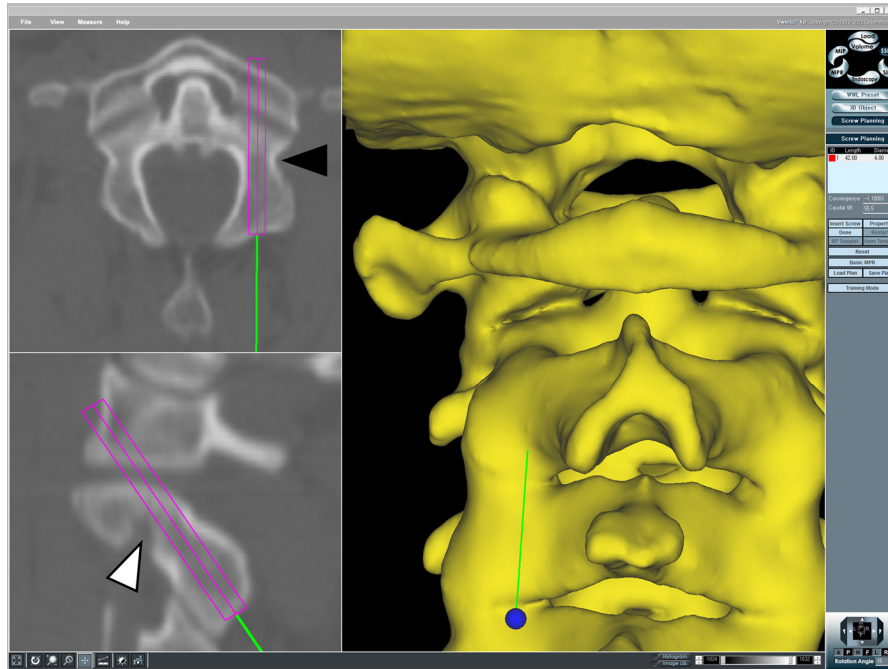


Fig. 2. The trajectory of the transarticular screw is shown. The entry point is set at 3 mm above the C2–C3 joint line and as medial as possible without penetrating the lateral wall of the spinal canal at C2. The screw is angulated as dorsally as possible without perforating the dorsal cortical surface of C2. The vertebral artery groove of C2 is located lateral (black arrowhead) and anteroinferior (white arrowhead) to the screw.

intraoperative navigation. Using this software, we simulated the insertion of 4.0 mm transarticular and pedicle screws by changing the entry point and insertion angle of each screw while manipulating 3D and multiplanar (axial, sagittal, and

coronal) images simultaneously (Figs. 2 and 3). During simulation, we examined whether violation of the C2 vertebral artery groove was unavoidable, while keeping the other cortices intact.

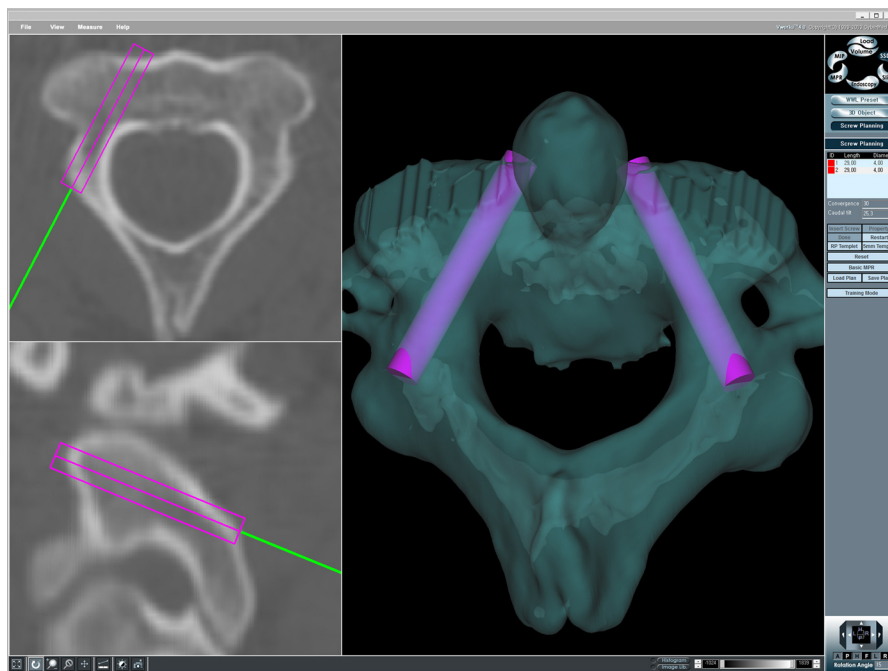


Fig. 3. The trajectory for the pedicle screw is shown. The entry point is set at the level of the upper end of the C2 lamina. Mediolaterally, it is located at a point that minimizes C2 vertebral artery groove violation, usually at the midportion of the pars interarticularis of C2. Medial and upward angulations are set at an angle that minimizes the groove violation.

Screw trajectories

The entry point of a transarticular screw was set at 3 mm above the C2–C3 joint line and at the most medial point that allowed for preservation of the cortical margin of the spinal canal wall at C2 while maintaining a proper sagittal screw trajectory (Fig. 2). The screw trajectory was directed as dorsally as possible (Fig. 2) to minimize the possibility of violating the anteriorly located C2 vertebral artery groove [15,17,18].

The entry point of the pedicle screw was set at the level of the upper end of the C2 lamina (Fig. 3) [19]. Mediolaterally, the entry point was located at a point that minimized C2 vertebral artery groove violation, usually at the midportion of the pars interarticularis of C2. Medial and upward angulations were set at an angle that minimized vertebral artery groove violation, taking into account individual anatomic variations [11,20].

High-riding vertebral artery and narrow pedicle of C2

In addition to the simulation of screw insertion, the presence or absence of a high-riding vertebral artery and/or narrow pedicle was determined for each side in all patients using the same software. A high-riding vertebral artery was defined as an isthmus height of 5 mm or less and/or internal height of 2 mm or less on a sagittal image that is at 3 mm lateral to the cortical margin of the spinal canal wall at C2 (Fig. 4, Left). This definition was adapted from previous descriptions by Bloch et al. [16] and Neo et al. [15]. A narrow pedicle was defined using the pedicle width, which was measured on axial CT scan images at the levels where the lateral cortical margin of the pedicle was clearly seen (Fig. 4, Right). A narrow pedicle was considered to be present when the largest pedicle width was 4 mm or less because the diameter of commonly used screws is 4.0 or 3.5 mm.

Analyses

We determined the prevalence of a high-riding vertebral artery and narrow pedicle. Next, for each screw including transarticular and pedicle screws, we evaluated the overall frequency of C2 vertebral artery groove violations and the relative risk of violation caused by high-riding vertebral arteries and narrow pedicles. Then we performed three comparative analyses. First, we compared the overall frequency of vertebral artery groove violations by transarticular screws versus pedicle screws in the entire patient population. Second, the same comparison was performed for the subset of patients with a high-riding vertebral artery and with a narrow pedicle.

Statistical analyses were carried out using GraphPad Prism version 5.00 for Windows (GraphPad Software, San Diego, CA, USA). The frequency of vertebral artery groove violation was compared using Fisher exact test (for independent proportions) or McNemar test (for paired proportions). The level of significance was set at $p < .05$ for all statistical analyses.

Sample size estimation

A prestudy sample size estimation was performed to determine the number of CT scans to be used. The primary determinant for sample size calculation was to allow meaningful comparison of the overall frequency of C2 vertebral artery groove violations by transarticular screws versus pedicle screws. Based on the report by Yoshida et al. [12], the vertebral artery groove violation rate for transarticular screws was set at 88.7%. We assumed that the minimal clinically important difference of vertebral artery groove violation rate was 5% and set the probability of a Type I error (the level of significance) at 5% ($\alpha = 0.05$) and Type II error at 20% ($\beta = 0.20$) with a statistical power of 80%. With these parameters, the minimum sample size needed for McNemar test was found to be 538 for each screw.

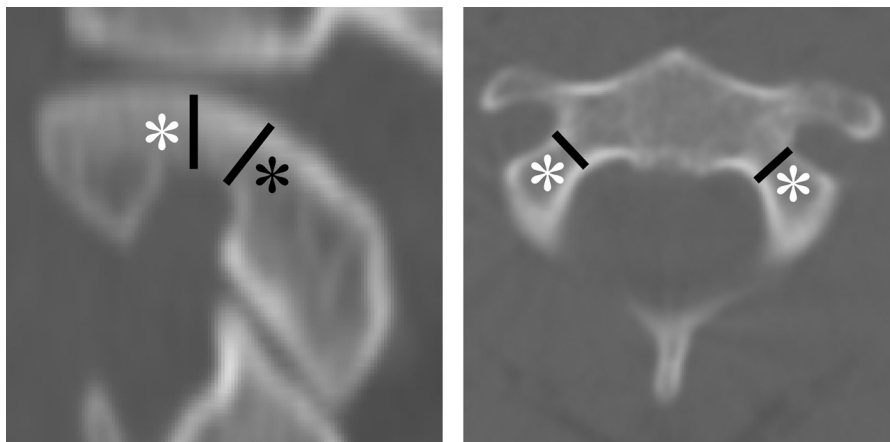


Fig. 4. (Left) High-riding vertebral artery is defined by an isthmus height (black asterisk) of 5 mm or less and/or internal height (white asterisk) of 2 mm or less on a sagittal image that is at 3 mm lateral to the cortical margin of the spinal canal wall at C2. (Right) Narrow pedicle is defined by a pedicle width (white asterisk) 4 mm or less, which is measured on axial computed tomography scan images at the levels where the lateral cortical margin of the pedicle was clearly seen.

Results

Demographic data

Computed tomography scans of 269 consecutive patients who fulfilled the selection criteria were used in the study, for a total of 538 possible screw insertion sites. There were 159 men and 110 women and the age averaged 49 years (range 20–84 years).

Frequency of high-riding vertebral artery and narrow pedicle

There were 78 high-riding vertebral arteries (14.5%) and 51 narrow pedicles (9.5%) among the 538 possible screw insertion sites. The vast majority of narrow pedicles (82%, 42/51) had a concurrent high-riding vertebral artery, whereas only 54% (42/78) of high-riding vertebral arteries had a concurrent narrow pedicle.

Frequency of C2 vertebral artery groove violations

Screw trajectories were evaluated bilaterally, for a total of 538 possible screw insertion sites for each type of screw. As a whole, transarticular screws violated the C2 vertebral artery groove in 9.5% (51/538; Table 1). Among the 78 possible screw insertion sites with high-riding vertebral artery, transarticular screws violated the vertebral artery groove in 49 (63%). Among the 460 possible screw insertion sites without a high-riding vertebral artery, the transarticular screw violated the vertebral artery groove in only 2 (<1%). Therefore, the frequency of vertebral artery groove violations by transarticular screws was significantly higher in those with a high-riding vertebral artery than in those without a high-riding vertebral artery ($p < .001$), with a relative risk of 144.5. Among the 51 possible screw insertion sites with narrow pedicles, the transarticular screw violated the vertebral artery groove in 36 (71%). Among the 487 possible screw insertion sites without a narrow pedicle, the transarticular screw violated the vertebral artery groove in 15 (3%). Therefore, the frequency of vertebral artery groove violation by the transarticular screw was significantly higher in those with narrow pedicles than in those without narrow pedicles ($p < .001$), with a relative risk of 22.9.

Table 1
C2 vertebral artery groove violations by C1–C2 transarticular screws

Variants	Violation (N=538)		p*	Relative risk (95% confidence interval)
	Present	Absent		
High-riding vertebral artery				
Present	49	29	<.0001	144.5 (35.9–582.3)
Absent	2	458		
Narrow pedicle				
Present	36	15	<.0001	22.9 (13.5–38.9)
Absent	15	472		

* Fisher exact test is used.

Table 2
C2 vertebral artery groove violations by C2 pedicle screws

Variants	Violation (N=538)		p*	Relative risk (95% confidence interval)
	Present	Absent		
High-riding vertebral artery				
Present	38	40	<.0001	44.8 (18.2–110.4)
Absent	5	455		
Narrow pedicle				
Present	39	12	<.0001	93.1 (34.7–250.1)
Absent	4	483		

* Fisher exact test is used.

C2 pedicle screws violated the C2 vertebral artery groove in 8.0% (43/538; Table 2). Among the 78 possible screw insertion sites with a high-riding vertebral artery, pedicle screws violated the vertebral artery groove in 38 (49%). Among the 460 possible screw insertion sites without a high-riding vertebral artery, the pedicle screw violated the vertebral artery groove in 5 (1%). Therefore, the frequency of vertebral artery groove violation by pedicle screws was significantly higher in those with high-riding vertebral artery than in those without high-riding vertebral artery ($p < .001$), with a relative risk of 44.8. Among the 51 possible screw insertion sites having narrow pedicles, the pedicle screw violated the vertebral artery groove in 39 (76%). Among the 487 possible screw insertion sites without a narrow pedicle, the pedicle screw violated the vertebral artery groove in 4 (1%). Therefore, the frequency of vertebral artery groove violation by the pedicle screw was significantly higher in those with a narrow pedicle than in those without a narrow pedicle ($p < .001$), with a relative risk of 93.1.

Comparison of frequency of C2 vertebral artery groove violations between the two types of screws

As described previously, overall, 9.5% (51/538) of transarticular screws violated the C2 vertebral artery groove compared with 8.0% (43/538) of pedicle screws (Table 3). However, the difference was not statistically significant ($p = .17$). Among the 78 possible screw insertion sites with high-riding vertebral arteries, vertebral artery groove violations were significantly lower ($p = .02$) with pedicle (38 violations, 49%) than with transarticular (49 violations, 63%)

Table 3
C2 vertebral artery groove violations by C1–C2 transarticular screws versus C2 pedicle screws

Variants	Violation by TAS (%)	Violation by PS (%)	p*
Overall (N=538)	51 (9.5)	43 (8.0)	.17
HRVA (N=78)	49 (63)	38 (49)	.02
NP (N=51)	36 (71)	39 (76)	.55

TAS, C1–C2 transarticular screw; PS, C2 pedicle screw; HRVA, high-riding vertebral artery; NP, narrow pedicle.

* McNemar test is used.

screws. Among the 51 possible screw insertion sites with narrow pedicles, transarticular screws violated the vertebral artery groove in 36 (71%) and pedicle screws violated the vertebral artery groove in 39 (76%), but this difference was not statistically significant ($p=.55$).

Discussion

Placement of either C1–C2 transarticular or C2 pedicle screws has a potential risk of vertebral artery injury [1–14,21]. The risk of vertebral artery injury by these two techniques needs to be carefully analyzed so as to allow the surgeon to choose the appropriate screw insertion method. Whereas some surgeons [9–11] have suggested that C2 pedicle screws have theoretical advantages over C1–C2 transarticular screws, as far as vertebral artery injury is concerned, the only two studies comparing the two fixation methods [12,13] have concluded that the risk is not significantly different. Resnick et al. [13] compared the risk with 4.0 mm transarticular screws versus pedicle screws using CT scans. In 50 patients, they analyzed 2D CT scans, and in 10 patients, they used 3D imaging and computer-aided navigation tools. In 2D CT scans, there was adequate room for transarticular screws in 94% and for pedicle screws in 91%. In 3D CT imaging, there was an adequate room for transarticular screws in 95% and for pedicle screws in 100%. Therefore, they stated that pedicle screw fixation is not any safer than transarticular screws from a strictly anatomic standpoint. More recently, Yoshida et al. [12] evaluated 62 patients using 3D images reconstructed by a computer-assisted navigation system. They found that there was no room for a 4-mm transarticular screw in 11.3% and for a 4-mm pedicle screw in 9.7%, with no statistically significant difference. Unfortunately, given the relatively small sample size and lack of power analysis in both studies, it is not clear whether these findings are valid. The authors of the 2 studies analyzed CT scans of 60 [13] and 62 [12] patients, respectively, whereas our sample size estimation showed that 269 patients were needed to provide adequate statistical power to enable a meaningful comparison.

Furthermore, to the best of our knowledge, no reports have been published to date comparing the risk of vertebral artery injury by the two types of screws in those with a limited space to accommodate these screws (such as those with a high-riding vertebral artery and/or narrow pedicle). Considering the morbidity and potential mortality of a vertebral artery injury and the increased risk of such injury in patients with a high-riding artery and/or narrow pedicle, the risk of vertebral artery injury needs to be specifically compared between the two screw types to provide helpful information to surgeons.

To address these issues, we undertook this study and compared the risk of vertebral artery injury with the two fixation methods using a large number of CT scan images and 3D surgical simulation software.

Key findings of the present study

In our study, the risk of vertebral artery groove violation by transarticular screws was significantly increased, not only by high-riding vertebral arteries ($p<.001$) but also by narrow pedicles ($p<.001$). Similarly, the risk of vertebral artery groove violation by pedicle screws was significantly increased by high-riding vertebral arteries ($p<.001$) and by narrow pedicles ($p<.001$). Interestingly, overall, the difference in the risk of vertebral artery groove violation between transarticular (9.5%) and pedicle (8.0%) screws was not statistically significant ($p=.17$). However, in the presence of a high-riding artery, the risk of a vertebral artery groove violation was significantly lower with pedicle than with transarticular screws ($p=.02$). On the other hand, narrow pedicles did not result in a significant difference in the risk between the screws ($p=.55$). This is counterintuitive in that small pedicles might be anticipated to lead to higher risk for pedicle screws (limited by pedicle width) [12] than transarticular screws. To reiterate, whereas the presence of a high-riding vertebral artery increased the risk of vertebral artery groove violation with transarticular screws to a significantly greater extent than with pedicle screws, the presence of narrow pedicles increased the risk of vertebral artery injury by the two types of screws to a similar degree.

Interpretation of study results

Our results of 3D surgical simulation using 538 possible screw insertion sites for each type of screw with 80% statistical power show that, overall, the risk of vertebral artery groove violation by the 2 screw types is not significantly different ($p=.17$). This is contrary to the previous suggestions [9–11] that pedicle screws are more likely to avoid injuring the vertebral artery because the artery is located lateral to the screw and the screw is placed medialward, as shown in Fig. 3. Whereas it is true that pedicle screws are directed more medially than transarticular screws (which is angled primarily in the sagittal plane), pedicle screws are also directed less cranially than transarticular screws (Figs. 2 and 3). Therefore, as shown in Fig. 5, the area of possible vertebral artery groove violation is moved not just medially but also inferiorly. As a result, pedicle screws typically tend to breach the inferomedial portion of the vertebral artery groove, that is, the lateral portion of the pedicle. In contrast, the area of typical vertebral artery groove violation by transarticular screws is at a more superoposterior portion of the vertebral artery groove (Fig. 5). Whereas medial angulation of pedicle screws decreases the risk of vertebral artery groove violation, less upward angulation of pedicle screws increases the risk because the vertebral artery groove is located in the caudal surface of C2 (Figs. 1 and 5). The effects of these two factors appear to counterbalance each other, resulting in no significant difference in the risk of vertebral artery groove violation with the two fixation methods.

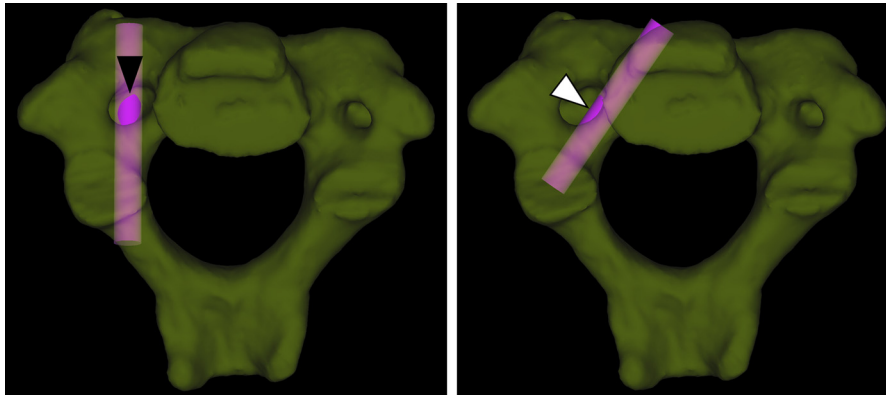


Fig. 5. Inferior views of C2 show the areas of vertebral artery groove violation by the two types of screws. (Left) The area of typical violation by transarticular screw (black arrowhead) is at the superoposterior portion of the groove. (Right) The area of typical violation by pedicle screw (white arrowhead) is the inferomedial portion of the groove.

Perhaps, even more important is the comparison of the risk between the two types of screws in those with a small space to accommodate the screws. We, therefore, analyzed the risk of vertebral artery groove violation in two subsets of patients: those with high-riding vertebral arteries and those with narrow pedicles. Transarticular screws place the artery at risk in cases with a high-riding vertebral artery, defined in the sagittal plane (Fig. 4, Left) [15,16]. On the other hand, narrow pedicles, defined in the axial plane (Fig. 4, Right), would be expected to increase the risk of vertebral artery injury by pedicle screws [12]. Considering that high-riding vertebral arteries and narrow pedicle are defined in two different planes (ie, sagittal vs. axial), one may anticipate that high-riding arteries may lead to a higher risk of arterial injury with transarticular than with pedicle screws and narrow pedicles may lead to a higher risk of arterial injury with pedicle than with transarticular screws. However, our study using 3D simulation showed different and unanticipated results. Whereas the risk in the presence of a high-riding vertebral artery was significantly higher with transarticular than pedicle screws ($p=.02$) as expected, narrow pedicles did not lead to a significant difference in the risk between the screws ($p=.55$). This could be explained by the fact that most patients with narrow pedicles (82%) had a concurrent high-riding vertebral artery that also increased the risk of vertebral artery injury with transarticular screws, whereas only 54% of patients with high-riding vertebral arteries had a concurrent narrow pedicle.

We defined a narrow pedicle as one where the largest pedicle width measured on axial CT scan images was 4 mm or less. We found that 24% of narrow pedicles could accommodate 4 mm pedicle screws. This may at first sound implausible. However, the C2 pedicle has a totally different morphology than other vertebrae. The shape of its coronal cut surface is not always ovoid as in other vertebrae and has wide individual variations, for example, the cranial part may be much wider than the caudal part. An extreme example is shown in Fig. 6. In such cases, the width of the

pedicle may appear narrow on axial images, whereas the cranial part of the pedicle, which may be much wider, may not be readily identifiable as a part of the pedicle on axial images (Fig. 6). These cases may be regarded as having a narrow pedicle by our definition, using axial images alone, while allowing pedicle screws to be placed in the cranial part of the pedicle without cortical breach. This demonstrates the limitation of predicting the feasibility of pedicle screw placement using axial images alone. On the 3D reconstructed images of these cases, the cranial part of the pedicle is wide enough to accommodate a screw, as seen in Fig. 6. Unfortunately, however, in most clinical settings, such a 3D image as seen in Fig. 6 may not be readily available and measurement of the pedicle width on 3D images may not be possible. Of note, C2 pedicle is the portion posterolateral to the vertebral body and medial to the transverse foramen (Fig. 7). It is different from the pars interarticularis or isthmus, which is the narrowest portion between the superior and inferior articular processes [22].

Because the 3D shape of the C2 vertebral artery groove and the internal anatomy of the bony space available for the screw placement are complex [14,21], it is very difficult to describe the C2 anatomy using only 2D methods, particularly in those with high-riding vertebral arteries and narrow pedicles. The more reliable method of evaluating the risk of vertebral artery groove violation is to use 3D screw trajectory analyses. Such methods have been used previously to study the cervical spine [12–14,21,23–26] and proved instrumental in the current study. Because this method is currently not readily available in most clinical settings, where only 2D images are usually accessible, the results of the current study may be used to guide the selection of the most appropriate fixation method by allowing assessment of the risk of arterial injury in a given patient using 2D parameters. This is especially the case for those with anatomic variations such as high-riding vertebral arteries and/or narrow pedicles.

Our results suggest that except in cases of a high-riding vertebral artery, the anatomic risk of the two types of

Fig. 6. An extreme example of discrepancy in the width of the cranial and caudal parts of the pedicle shows the limitation of evaluating the pedicle width using axial images alone. The width of the right pedicle looks small on an axial image and on a caudal three-dimensional (3D) view (white arrowheads). Using our definition, this case is classified as having a narrow pedicle. However, a pedicle screw (pink bar) may be placed without cortical breach in the cranial part of the pedicle, where its width is large enough, as seen on the cranial 3D view (black arrowhead). This part corresponds to an area on an axial image where the pedicle is not easily identifiable (black arrow).

screws to the vertebral artery is similar and surgeons may opt to use either technique. When making the decision as to which method is most appropriate, surgeons need to consider several individual patient factors, as follows. First,

some types of vertebral artery anomalies such as a persistent first intersegmental artery and fenestrated vertebral artery may preclude the use of C1 lateral mass screws [27], which is usually used in conjunction with C2 pedicle screws. In

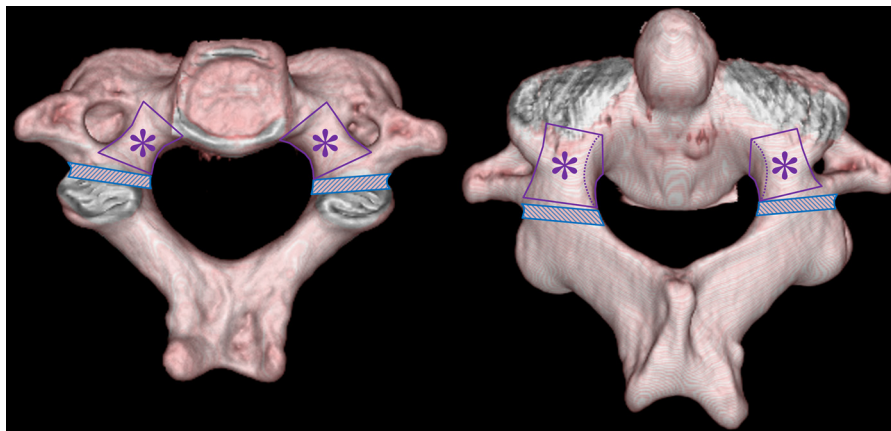


Fig. 7. Inferior and superoposterior views of C2 show the pedicle (asterisk) and the pars interarticularis (hatched areas). The pedicle is the portion posterolateral to the vertebral body and medial to the transverse foramen. The pars interarticularis is the narrowest portion between the superior and inferior articular processes.

those situations, transarticular screws may be advantageous, especially if the surgeon does not feel comfortable placing C1 lateral mass screws in a highly challenging situation. Second, technical difficulties in placing each screw should be taken into account in the selection. Whereas transarticular screws require prerotation of C1–C2 subluxation and should be placed maintaining the reduction, C2 pedicle screws do not require prerotation; so, surgeons can concentrate on screw placement without trying to maintain reduction. In this regard, placement of C2 pedicle screws may be safer. In addition, reduction can be easily achieved with pedicle screws because it is performed independently during rod assembly after screw placement. Furthermore, pedicle screws require less extensive skin incisions, are applicable to obese or kyphotic patients, and provide longer screw purchase [10,12,13]. Third, placement of C2 pedicle screws along with inferomedially angulated C1 lateral mass screws may be safer, as far as the risk of internal carotid artery injury is concerned, than placement of C1–C2 transarticular screws [23].

Limitations of the current study

As with any study, there are a number of limitations in ours. First of all, our study is based on simulation using CT scans rather than using real cadavers. Although we used fine-cut CT scans and 3D images, they are not as realistic as cadaveric specimens. However, it would be impractical to perform a cadaver study with as large a number of potential screw insertion sites as in the present study. In addition, cadaveric specimens have the possibility of overrepresentation of elderly patients, which may introduce age-related morphologic changes such as arthritis. Alternatively, using CT data provides a broader range of ages [28]. Furthermore, computer simulation has the advantage that it allows “placement” of both transarticular and pedicle screws on the same side of the same patient with an unlimited number of screw placement attempts.

A second limitation is that, in surgery, screws may not be inserted in an optimal trajectory, so that insertion of both C2 types of screws may not be as safe as illustrated in this study. On the other hand, not all vertebral artery groove violations result in a vertebral artery injury because the groove is not filled entirely by the vertebral artery [29]. Third, as described previously, this study focused on bony structures and lacks assessment of soft tissues such as congenital anomalies of the vertebral artery. Finally, race, age, gender, and original diagnosis among our subjects were not considered.

Despite these limitations, we believe that this study has unique strengths. We specifically compared the risk of vertebral artery injury by C1–C2 transarticular screws versus C2 pedicle screws using a sufficiently large number of cases, based on a power analysis for sample size estimation. Furthermore, we compared the risk of vertebral artery injury by both types of screws in those with high-riding

vertebral arteries and/or narrow pedicles, which is important, considering the increased risk of arterial injury in those conditions. Finally, as far as we know, no studies on this subject have been reported.

Conclusions

To our knowledge, this is the only study that specifically compares the risk of vertebral artery injury by C1–C2 transarticular screws versus C2 pedicle screws using a sufficiently large number of cases based on a power analysis for sample size estimation. In addition, we are also the first to evaluate the risk of vertebral artery injury by both types of screws in those with a high-riding vertebral artery and/or narrow pedicle. This study reveals that, overall, neither technique has an inherently higher anatomic risk of vertebral artery injury. However, in the presence of a high-riding vertebral artery, a pedicle screw is significantly safer than a transarticular screw, although the risk for both screws is significantly increased. A narrow pedicle also increases the risk for both screws significantly, but the risk is not significantly different between the two. Therefore, except in cases of a high-riding vertebral artery, our results suggest that surgeons can expect similar anatomical risks to the vertebral artery. They can opt for either technique, taking into account other already known factors such as congenital anomalies of the vertebral artery, technical difficulty in placement of each screw, and risk of internal carotid artery injury.

Acknowledgments

This study was supported by a Research Grant (04-2008-006) of Seoul National University Bundang Hospital of JSY (04-2008-006) with US \$9,000. This is a pure academic grant, and there are no topic-specific potential conflicts of interest with this study. KDR receives royalties for a posterior cervical fixation system, which can be used for C1–C2 transarticular or C2 pedicle screws; however, this system neither is mentioned in this article nor was used during the study. We thank and acknowledge Ms. Yoon Ju Kwon, Ms. Seung Min You, and Ms. Junga Park, the spine research coordinators at our institution, for their contributions to the project.

References

- [1] Farey ID, Nadkarni S, Smith N. Modified Gallie technique versus transarticular screw fixation in C1-C2 fusion. *Clin Orthop Relat Res* 1999;359:126–35.
- [2] Madawi AA, Casey AT, Solanki GA, et al. Radiological and anatomical evaluation of the atlantoaxial transarticular screw fixation technique. *J Neurosurg* 1997;86:961–8.
- [3] Wright NM, Laurysen C. Vertebral artery injury in C1-2 transarticular screw fixation: results of a survey of the AANS/CNS section on disorders of the spine and peripheral nerves. *American Association of*

- Neurological Surgeons/Congress of Neurological Surgeons. *J Neurosurg* 1998;88:634–40.
- [4] Igarashi T, Kikuchi S, Sato K, et al. Anatomic study of the axis for surgical planning of transarticular screw fixation. *Clin Orthop Relat Res* 2003;408:162–6.
- [5] Mandel IM, Kambach BJ, Petersilge CA, et al. Morphologic considerations of C2 isthmus dimensions for the placement of transarticular screws. *Spine* 2000;25:1542–7.
- [6] Paramore CG, Dickman CA, Sonntag VK. The anatomical suitability of the C1-2 complex for transarticular screw fixation. *J Neurosurg* 1996;85:221–4.
- [7] Prabhu VC, France JC, Voelker JL, Zoarski GH. Vertebral artery pseudoaneurysm complicating posterior C1-2 transarticular screw fixation. case report. *Surg Neurol* 2001;55:29–33; discussion 33–34.
- [8] Solanki GA, Crockard HA. Peroperative determination of safe superior transarticular screw trajectory through the lateral mass. *Spine* 1999;24:1477–82.
- [9] Shen FH, Samartzis D, Jenis LG, An HS. Rheumatoid arthritis: evaluation and surgical management of the cervical spine. *Spine J* 2004;4: 689–700.
- [10] Chen JF, Wu CT, Lee SC, Lee ST. Posterior atlantoaxial transpedicular screw and plate fixation. Technical note. *J Neurosurg Spine* 2005;2:386–92.
- [11] Harms J, Melcher RP. Posterior C1-C2 fusion with polyaxial screw and rod fixation. *Spine* 2001;26:2467–71.
- [12] Yoshida M, Neo M, Fujibayashi S, Nakamura T. Comparison of the anatomical risk for vertebral artery injury associated with the C2-pedicle screw and atlantoaxial transarticular screw. *Spine* 2006;31:E513–7.
- [13] Resnick DK, Lapsiwala S, Trost GR. Anatomic suitability of the C1-C2 complex for pedicle screw fixation. *Spine* 2002;27:1494–8.
- [14] Miyata M, Neo M, Ito H, et al. Is rheumatoid arthritis a risk factor for a high-riding vertebral artery? *Spine* 2008;33:2007–11.
- [15] Neo M, Matsushita M, Iwashita Y, et al. Atlantoaxial transarticular screw fixation for a high-riding vertebral artery. *Spine* 2003;28:666–70.
- [16] Bloch O, Holly LT, Park J, et al. Effect of frameless stereotaxy on the accuracy of C1-2 transarticular screw placement. *J Neurosurg* 2001; 95:74–9.
- [17] Neo M, Matsushita M, Yasuda T, et al. Use of an aiming device in posterior atlantoaxial transarticular screw fixation. Technical note. *J Neurosurg* 2002;97:123–7.
- [18] Neo M, Sakamoto T, Fujibayashi S, Nakamura T. A safe screw trajectory for atlantoaxial transarticular fixation achieved using an aiming device. *Spine* 2005;30:E236–42.
- [19] Abumi K, Kaneda K. Pedicle screw fixation for nontraumatic lesions of the cervical spine. *Spine* 1997;22:1853–63.
- [20] Goel A, Desai KI, Muzumdar DP. Atlantoaxial fixation using plate and screw method: a report of 160 treated patients. *Neurosurgery* 2002;51:1351–6.
- [21] Miyata M, Neo M, Ito H, et al. Rheumatoid arthritis as a risk factor for a narrow C-2 pedicle: 3D analysis of the C-2 pedicle screw trajectory. *J Neurosurg Spine* 2008;9:17–21.
- [22] Ebraheim NA, Fow J, Xu R, Yeasting RA. The location of the pedicle and pars interarticularis in the axis. *Spine* 2001;26:E34–7.
- [23] Estillore RP, Buchowski JM, Minh DV, et al. Risk of internal carotid artery injury during C1 screw placement: analysis of 160 computed tomography angiograms. *Spine J* 2011;11:316–23.
- [24] Lee JO, Buchowski JM, Lee KM, et al. Optimal trajectory for the occipital condylar screw. *Spine* 2011;37:385–92.
- [25] Lee KM, Yeom JS, Lee JO, et al. Optimal trajectory for the atlantooccipital transarticular screw. *Spine* 2010;35:1562–70.
- [26] Shin SI, Yeom JS, Kim H-J, et al. The feasibility of laminar screw placement in the subaxial spine: analysis using 215 three-dimensional computed tomography scans and simulation software. *Spine J* 2012;12: 577–84.
- [27] Hong JT, Lee SW, Son BC, et al. Analysis of anatomical variations of bone and vascular structures around the posterior atlantal arch using three-dimensional computed tomography angiography. *J Neurosurg Spine* 2008;8:230–6.
- [28] Hoh DJ, Liu CY, Wang MY. A radiographic computed tomography-based study to determine the ideal entry point, trajectory, and length for safe fixation using C-2 pars interarticularis screws. *J Neurosurg Spine* 2010;12:602–12.
- [29] Cacciola F, Phalke U, Goel A. Vertebral artery in relationship to C1-C2 vertebrae: an anatomical study. *Neurol India* 2004;52:178–84.